

2025 ESC Guidelines for the management of myocarditis and pericarditis

Developed by the task force for the management of myocarditis and pericarditis of the European Society of Cardiology (ESC)

Endorsed by the Association for European Paediatric and Congenital Cardiology (AEPCC) and the European Association for Cardio-Thoracic Surgery (EACTS)

Authors/Task Force Members: Jeanette Schulz-Menger ^{†,*}, (Chairperson) (Germany), Valentino Collini [‡], (Task Force Co-ordinator) (Italy), Jan Gröschel [‡], (Task Force Co-ordinator) (Germany), Yehuda Adler (Israel), Antonio Brucato  (Italy), Vanessa Christian (United Kingdom), Vanessa M. Ferreira  (United Kingdom), Estelle Gandjbakhch  (France), Bettina Heidecker  (Germany), Mathieu Kerneis  (France), Allan L. Klein  (United States of America), Karin Klingel  (Germany), George Lazaros  (Greece), Roberto Lorusso  (Netherlands), Elena G. Nesukay  (Ukraine), Kazem Rahimi  (United Kingdom), Arsen D. Ristić  (Serbia), Marcin Rucinski  (Poland), Leyla Elif Sade  (United States of America), Hannah Schaubroeck (Belgium), Anne Grete Semb  (Norway), Gianfranco Sinagra  (Italy), Jens Jakob Thune  (Denmark), Massimo Imazio ^{†,*}, (Chairperson) (Italy), and the ESC Scientific Document Group

* Corresponding authors: Jeanette Schulz-Menger, Charité—Universitätsmedizin Berlin, corporate member of Freie Universität Berlin and Humboldt-Universität zu Berlin, ECRC Experimental and Clinical Research Center, Berlin, Germany, and DZHK (German Centre for Cardiovascular Research), partner site Berlin, Berlin, Germany, and Deutsches Herzzentrum der Charité Berlin, Germany, and Cardiology and Nephrology, HELIOS Hospital Berlin-Buch, Berlin, Germany. Tel: +4930450540611, E-mail: jeanette.schulz-menger@charite.de

Massimo Imazio, Department of Medicine, University of Udine, and Cardiothoracic Department, University Hospital Santa Maria della Misericordia, ASUFC, Udine, Italy. Tel: +393296524271, E-mail: massimo.imazio@uniud.it

[†] The two Chairpersons contributed equally to the document and are joint corresponding authors.

[‡] The two Task Force Co-ordinators contributed equally to the document.

Author/Task Force Member affiliations are listed in author information.

ESC Clinical Practice Guidelines (CPG) Committee: listed in the Appendix.

ESC subspecialty communities having participated in the development of this document:

Associations: Association of Cardiovascular Nursing & Allied Professions (ACNAP), Association for Acute Cardiovascular Care (ACVCC), European Association of Cardiovascular Imaging (EACVI), European Association of Percutaneous Cardiovascular Interventions (EAPCI), European Heart Rhythm Association (EHRA), Heart Failure Association (HFA).

Councils: Council for Cardiology Practice, Council of Cardio-Oncology, Council on Basic Cardiovascular Science.

Working Groups: Cardiovascular Pharmacotherapy, Cardiovascular Surgery, Myocardial and Pericardial Diseases, Pulmonary Circulation and Right Ventricular Function.

Patient Forum

© The European Society of Cardiology 2025. All rights reserved.

Document Reviewers: Elena Arbelo, (CPG Review Co-ordinator) (Spain), Cristina Basso, (CPG Review Co-ordinator) (Italy), Marianna Adamo (Italy), Suleman Aktaa (United Kingdom), Enrico Ammirati (Italy), Lisa Anderson (United Kingdom), Eloisa Arbustini (Italy), Emanuele Bobbio (Sweden), Giuseppe Boriani (Italy), Margarita Brida (Croatia), Robert A. Byrne (Ireland), Alida L.P. Caforio (Italy), Gh.-Andrei Dan (Romania), Fernando Domínguez (Spain), Suzanne Fredericks (Canada), Geeta Gulati (Norway), Borja Ibanez (Spain), Stefan James (Sweden), Alexander Kharlamov (Netherlands), Sabine Klaassen (Germany), Jolanda Kluin (Netherlands), Konstantinos C. Koskinas (Switzerland), Petr Kuchynka (Czech Republic), Vijay Kunadian (United Kingdom), Ulf Landmesser (Germany), Gregory Y.H. Lip (United Kingdom), Bernhard Maisch (Germany), Federica Marelli-Berg (United Kingdom), Pilar Martin (Spain), John William McEvoy (Ireland), Borislava Mihaylova (United Kingdom), Richard Mindham (United Kingdom), Inge Moelgaard (Denmark), Saidi A. Mohiddin (United Kingdom), Jens Cosedis Nielsen (Denmark), Agnes A. Pasquet (Belgium), Giovanni Peretto (Italy), Kalliopi Pilichou (Italy), Nicolas Piriou (France), Eva Prescott (Denmark), Amina Rakisheva (Kazakhstan), Bianca Rocca (Italy), Xavier Rossello (Spain), Anna Sannino (Germany), Franziska Seidel¹ (Germany), Felix C. Tanner (Switzerland), Witold Zbyszek Tomkowski (Poland), Ilonca Vaartjes (Netherlands), Sophie Van Linthout (Germany), Christiaan Vrints (Belgium), Romuald Wojnicz (Poland), and Katja Zeppenfeld (Netherlands)

¹ Representing the Association for European Paediatric and Congenital Cardiology (AEPC).

SD All experts involved in the development of these guidelines have submitted declarations of interest, which are reported in a supplementary document to the guidelines. See the *European Heart Journal* online or <https://www.escardio.org/Guidelines> for supplementary documents as well as evidence tables.

Disclaimer: The European Society of Cardiology (ESC) Guidelines represent the views of the ESC and were produced after careful consideration of the scientific and medical knowledge and the evidence available at the time of their publication. The ESC is not responsible in the event of any contradiction, discrepancy and/or ambiguity between the ESC Guidelines and any other official recommendations or guidelines issued by the relevant public health authorities, in particular in relation to good use of healthcare or therapeutic strategies. Health professionals are encouraged to take the ESC Guidelines fully into account when exercising their clinical judgement, as well as in the determination and the implementation of preventive, diagnostic or therapeutic medical strategies; however, the ESC Guidelines do not override, in any way whatsoever, the individual responsibility of health professionals to make appropriate and accurate decisions in consideration of each patient's health condition and in consultation with that patient and, where appropriate and/or necessary, the patient's caregiver. Nor do the ESC Guidelines exempt health professionals from taking into full and careful consideration the relevant official updated recommendations or guidelines issued by the competent public health authorities, in order to manage each patient's case in light of the scientifically accepted data pursuant to their respective ethical and professional obligations. It is also the health professional's responsibility to verify the applicable rules and regulations relating to drugs and medical devices prior to making any clinical decision and to check whether a more recent version of this document exists. The ESC warns readers that the technical language may be misinterpreted and declines any responsibility in this respect.

Permissions: The content of these ESC Guidelines has been published for personal and educational use only. No commercial use is authorized. No part of the ESC Guidelines may be translated or reproduced in any form without written permission from the ESC. Permissions can be obtained upon submission of a written request to Oxford University Press, the publisher of the *European Heart Journal* and the party authorized to handle such permissions on behalf of the ESC (journals.permissions@oup.com).

Keywords

Guidelines • Myocarditis • Pericarditis • Myopericarditis • Perimyocarditis • Diagnosis • Therapy • Echocardiography • Cardiac magnetic resonance • Multimodality imaging • Endomyocardial biopsy

Table of contents

1. Preamble	3958	3.3.2. Diagnostic criteria for pericarditis	3966
2. Introduction	3959	3.4. Aetiology of myocarditis and pericarditis	3966
2.1. What is new	3959	3.4.1. Aetiology of myocarditis	3966
3. Epidemiology, classification, stages, diagnostic criteria and aetiology	3962	3.4.2. Aetiology of pericarditis	3966
3.1. Epidemiology	3962	4. Clinical presentation of inflammatory myopericardial syndrome	3966
3.2. Classification and stages	3962	4.1. General symptoms and signs	3970
3.3. Diagnostic criteria	3963	4.2. Clinical stages of myocarditis	3970
3.3.1. Diagnostic criteria for myocarditis	3963	4.2.1. Acute myocarditis	3970
		4.2.2. Fulminant myocarditis	3971
		4.2.3. Subacute myocarditis	3971
		4.2.4. Chronic myocarditis	3971

4.3. Clinical presentations of myocarditis	3971	6.3.1.2. Intra-aortic balloon pump	3993
4.3.1. Chest pain presentation	3971	6.3.2. Pericarditis	3993
4.3.2. Heart failure presentation	3973	6.3.2.1. Pericardiocentesis and pericardial drainage	3993
4.3.3. Presentation with arrhythmias	3973	6.3.2.2. Percutaneous balloon pericardiotomy	3994
4.3.4. Sudden cardiac death	3973	6.3.2.3. Intrapericardial drug administration	3994
4.3.5. Presentation of myocarditis with a potential genetic background	3973	6.3.2.4. Pericardioscopy	3994
4.4. Clinical stages of pericarditis	3973	6.3.2.5. Pericardial fluid analysis, pericardial and epicardial biopsy	3994
4.4.1. Acute pericarditis	3973	6.3.2.6. Circulatory support	3994
4.4.2. Subacute pericarditis	3976	6.4. Surgical therapy	3994
4.4.3. Chronic pericarditis	3976	6.4.1. Myocarditis	3994
4.5. Clinical presentations of pericarditis	3976	6.4.2. Pericarditis	3994
4.5.1. Dry pericarditis	3976	6.4.2.1. Surgical pericardiocentesis	3994
4.5.2. Effusive pericarditis	3976	6.4.2.2. Pericardiotomy/pericardial window	3994
4.5.3. Effusive–constrictive pericarditis	3976	6.4.2.3. Pericardiectomy	3995
4.5.4. Pericarditis with cardiac tamponade	3976	6.5. Management of arrhythmias and prevention of sudden cardiac death in myocarditis	3995
4.5.5. Constrictive pericarditis	3977	6.5.1. Role of active devices (wearable and implanted devices) in acute myocarditis	3996
4.5.6. Transient constrictive pericarditis	3978	7. Prognosis	3996
4.5.6.1. Constrictive pathophysiology	3978	7.1. Complications and outcomes for myocarditis	3996
4.5.7. Pericarditis with polyserositis	3979	7.1.1. Sequela and mortality in myocarditis	3997
4.5.8. Inflammatory vs non-inflammatory pericarditis	3979	7.1.2. Follow-up	3997
4.5.8.1. Inflammatory phenotype of pericarditis	3979	7.2. Complications and outcomes for pericarditis	3998
4.5.8.2. Non-inflammatory phenotype of pericarditis	3979	8. Inflammatory myopericardial syndrome overlapping types: myopericarditis and perimyocarditis	3999
5. Diagnosis and diagnostic work-up	3979	8.1. Inflammatory myopericardial syndrome in systemic disorders	4000
5.1. Electrocardiogram	3980	8.1.1. Rheumatoid arthritis	4000
5.2. Biomarkers	3980	8.1.2. Systemic lupus erythematosus	4000
5.2.1. Biomarkers in clinical routine	3980	8.1.3. Antiphospholipid syndrome	4000
5.2.2. Biomarkers beyond clinical routine	3980	8.1.4. Sjögren's syndrome	4000
5.3. Genetics	3981	8.1.5. Systemic sclerosis	4000
5.4. Multimodality imaging	3982	8.1.6. Polymyositis and dermatomyositis	4000
5.5. Echocardiography	3982	8.1.7. Vasculitis	4000
5.5.1. Echocardiography in myocarditis	3982	8.2. Inflammatory myopericardial syndrome in COVID-19 disease	4000
5.5.2. Echocardiography in pericarditis	3982	9. Specific types of myocarditis	4001
5.6. Cardiovascular magnetic resonance	3983	9.1. Lymphocytic myocarditis	4001
5.7. Computed tomography	3983	9.1.1. Presentation	4001
5.8. Nuclear medicine	3984	9.1.2. Diagnosis and therapy	4001
5.9. Endomyocardial and pericardial biopsy	3984	9.2. Eosinophilic myocarditis	4001
5.9.1. Endomyocardial biopsy	3984	9.2.1. Presentation	4001
5.9.2. Pericardial biopsy	3986	9.2.2. Diagnosis	4001
5.10. Role of autopsy	3986	9.2.3. Therapy	4001
5.11. Role of cardiac catheterization and coronary angiography	3986	9.3. Giant-cell myocarditis	4001
5.12. Electro-anatomical mapping	3987	9.3.1. Presentation	4002
6. Therapy	3987	9.3.2. Diagnosis	4002
6.1. Non-pharmacological therapy for inflammatory myopericardial syndrome	3987	9.3.3. Therapy	4002
6.2. Pharmacological therapy	3987	9.4. Myocarditis in sarcoidosis	4003
6.2.1. Pharmacological therapy for myocarditis	3987	9.4.1. Presentation	4003
6.2.1.1. General principles	3987	9.4.2. Diagnosis	4003
6.2.1.2. Fulminant myocarditis	3989	9.4.3. Therapy	4003
6.2.1.3. Acute myocarditis	3989	9.5. Specific infectious myocarditis (Viruses, Lyme, Chagas)	4004
6.2.1.4. Subacute and chronic myocarditis	3990	9.5.1. Viruses	4004
6.2.2. Pharmacological therapy for pericarditis	3990	9.5.1.1. Presentation	4004
6.2.2.1. General principles	3990	9.5.1.2. Diagnosis	4004
6.2.2.1.1. Acute pericarditis (first episode)	3990	9.5.1.3. Therapy	4004
6.2.2.2. Incessant and recurrent pericarditis	3990		
6.3. Interventional techniques including circulatory support	3993		
6.3.1. Myocarditis	3993		
6.3.1.1. Short-term mechanical circulatory support	3993		

9.5.1.3.1. Influenza virus	4004	11.9.1. Introduction	4014
9.5.1.3.2. Human immunodeficiency virus	4004	11.9.2. Presentation	4014
9.5.2. Lyme carditis	4004	11.9.3. Diagnosis	4014
9.5.2.1. Presentation	4004	11.9.4. Therapy	4015
9.5.2.2. Diagnosis	4004	11.10. Effusive–constrictive pericarditis	4015
9.5.2.3. Therapy	4004	11.10.1. Introduction	4015
9.5.3. Chagas disease	4005	11.10.2. Aetiology	4015
9.5.3.1. Presentation	4005	11.10.3. Presentation	4015
9.5.3.2. Diagnosis	4005	11.10.4. Diagnosis	4015
9.5.3.3. Therapy	4005	11.10.5. Treatment	4015
9.6. Drug- or vaccine-induced myocarditis	4005	12. Age- and sex-related aspects in inflammatory myopericardial syndrome	4015
9.6.1. Drug-induced myocarditis	4005	12.1. Sex distribution	4015
9.6.1.1. Immune checkpoint inhibitor-induced myocarditis ..	4005	12.2. Paediatric patients	4016
9.6.1.1.1. Presentation	4005	12.2.1. Myocarditis	4016
9.6.1.1.2. Diagnosis	4005	12.2.2. Pericarditis	4016
9.6.1.1.3. Therapy	4005	12.3. Pregnancy, lactation, and reproductive issues	4016
9.6.1.2. Other drugs associated with myocarditis	4006	12.4. The elderly	4017
9.6.2. Vaccine-induced myocarditis	4006	12.5. Physical activity in inflammatory myopericardial syndrome	4017
9.7. Pregnancy-associated myocarditis	4006	12.5.1. Mental health effect of restricting exercise	4017
9.7.1. Presentation	4006	12.6. Multidisciplinary teams for the management of inflammatory myopericardial syndrome	4017
9.7.2. Diagnosis	4006	13. Advice for patients	4018
9.7.3. Therapy	4006	14. Tertiary referral centres for inflammatory myopericardial syndrome: feature and volume of activity	4018
10. Inflammatory cardiomyopathy	4006	14.1. Tertiary care centres	4018
10.1. Presentation	4007	14.2. Inflammatory myopericardial syndrome in regional centres	4018
10.2. Diagnosis	4007	14.3. Hub-and-spoke model	4018
10.3. Therapy	4007	14.4. Teamwork, competencies, and advances in imaging techniques	4019
11. Specific types of pericarditis	4007	15. Key messages	4019
11.1. Tuberculous pericarditis	4007	15.1. Aetiology	4019
11.1.1. Presentation	4007	15.2. Clinical presentation and diagnosis	4019
11.1.2. Diagnosis	4007	15.3. Therapy	4019
11.1.3. Therapy	4008	15.4. Prognosis and outcomes	4019
11.2. Pericardial involvement in neoplastic disease	4009	15.5. Multidisciplinary team	4019
11.2.1. Presentation	4009	16. Gaps in evidence	4019
11.2.2. Diagnosis	4009	16.1. Myocarditis	4019
11.2.3. Therapy	4009	16.2. Pericarditis	4020
11.3. Post-cardiac injury syndrome	4009	17. Sex differences	4020
11.3.1. Diagnosis	4010	18. 'What to do' and 'What not to do' messages from the Guidelines	4020
11.3.2. Therapy	4010	19. Evidence tables	4023
11.4. Pericarditis and autoinflammatory diseases	4010	20. Data availability statement	4023
11.5. Purulent pericarditis	4010	21. Author information	4023
11.5.1. Presentation	4011	22. Appendix	4024
11.5.2. Diagnosis	4011	ESC Scientific Document Group	4024
11.5.3. Therapy	4011	23. References	4025
11.6. Incessant and recurrent pericarditis	4011		
11.7. Inflammatory and non-inflammatory pericardial effusion ..	4011		
11.7.1. Classification and aetiology	4011		
11.7.2. Presentation	4011		
11.7.3. Diagnosis	4012		
11.7.4. Therapy	4013		
11.7.5. Prognosis and follow-up	4013		
11.8. Cardiac tamponade	4013		
11.8.1. Presentation	4013		
11.8.2. Aetiology and diagnosis	4013		
11.8.3. Therapy	4014		
11.8.4. Outcomes and prognosis	4014		
11.9. Pericardial constriction and constrictive pericarditis (calcified and non-calcified)	4014		
		Tables of Recommendations	
		Recommendation Table 1 — Recommendations for clinical evaluation of myocarditis and pericarditis (see Evidence Table 1) .	3979
		Recommendation Table 2 — Recommendations for genetic testing (see Evidence Table 2)	3981
		Recommendation Table 3 — Recommendations for the use of cardiovascular magnetic resonance imaging (see Evidence Table 3)	3983

Recommendation Table 4 — Recommendations for computed tomography (see Evidence Table 4)	3983
Recommendation Table 5 — Recommendations for nuclear medicine (see Evidence Table 5)	3984
Recommendation Table 6 — Recommendations for endomyocardial biopsy (see Evidence Table 6)	3985
Recommendation Table 7 — Recommendations for autopsy (see Evidence Table 7)	3986
Recommendation Table 8 — Recommendations for electro-anatomical mapping (see Evidence Table 8)	3987
Recommendation Table 9 — Recommendations for medical therapy in myocarditis (see Evidence Table 9)	3990
Recommendation Table 10 — Recommendations for medical therapy in pericarditis (see Evidence Table 10)	3993
Recommendation Table 11 — Recommendations for interventional techniques including circulatory support in myocarditis (see Evidence Table 11)	3993
Recommendation Table 12 — Recommendations for interventional techniques in pericarditis (see Evidence Table 12)	3994
Recommendation Table 13 — Recommendations for surgical therapy (see Evidence Table 13)	3995
Recommendation Table 14 — Recommendations for management of arrhythmias and prevention of sudden cardiac death in myocarditis (see Evidence Table 14)	3996
Recommendation Table 15 — Recommendations for risk stratification, complications, and outcomes of inflammatory myopericardial syndrome (see Evidence Table 15)	3998
Recommendation Table 16 — Recommendations for giant-cell myocarditis (see Evidence Table 16)	4002
Recommendation Table 17 — Recommendations for myocarditis in sarcoidosis (see Evidence Table 17)	4003
Recommendation Table 18 — Recommendations for immune checkpoint inhibitor-associated myocarditis (see Evidence Table 18)	4006
Recommendation Table 19 — Recommendations for inflammatory cardiomyopathy (see Evidence Table 19)	4007
Recommendation Table 20 — Recommendations for tuberculous pericarditis (see Evidence Table 20)	4008
Recommendation Table 21 — Recommendations for neoplastic pericardial involvement (see Evidence Table 21)	4009
Recommendation Table 22 — Recommendations for post-cardiac injury syndrome (see Evidence Table 22)	4010
Recommendation Table 23 — Recommendations for purulent pericarditis (see Evidence Table 23)	4011
Recommendation Table 24 — Recommendations for constrictive pericarditis (see Evidence Table 24)	4015
Recommendation Table 25 — Recommendations for pregnancy, lactation, and reproductive issues (see Evidence Table 25)	4016
Recommendation Table 26 — Recommendations for physical activity and myocarditis/pericarditis (see Evidence Table 26)	4017
Recommendation Table 27 — Recommendations for multidisciplinary teams in myopericardial syndromes (see Evidence Table 27)	4017

List of tables

Table 1 Classes of recommendations	3958
Table 2 Levels of evidence	3959
Table 3 Terminology and stages	3962

Table 4 Diagnostic criteria and classification for inflammatory myopericardial syndrome	3964
Table 5 Histopathological criteria for myocarditis	3964
Table 6 Red flags for the clinical diagnosis of myocarditis and pericarditis	3967
Table 7 Clinical risk stratification to guide work-up in inflammatory myopericardial syndrome	3967
Table 8 Causes of cardiac tamponade	3976
Table 9 Basic and advanced level assessment	3980
Table 10 Classification of pericardial effusion	3982
Table 11 Parameters for reporting by endomyocardial biopsy	3986
Table 12 Therapy for specific forms of myocarditis	3988
Table 13 Specific initial dosing and duration of therapy for acute and recurrent pericarditis	3991
Table 14 Tapering of corticosteroids	3991
Table 15 Follow-up in inflammatory myopericardial syndrome after discharge	3998
Table 16 Indicators of non-viral aetiologies and complications (high-risk features or red flags in acute pericarditis)	3999
Table 17 Echocardiographic signs of cardiac tamponade	4013
Table 18 Definitions and therapy of main constrictive pericardial syndromes	4014
Table 19 'What to do' and 'What not to do'	4020

List of figures

Figure 1 Central illustration of the ESC guidelines on myocarditis and pericarditis	3960
Figure 2 Paradigm change in the clinical diagnosis of myocarditis ...	3961
Figure 3 Stages of inflammatory myopericardial syndrome	3963
Figure 4 Diagnostic criteria by cardiovascular magnetic resonance based on the updated Lake Louise criteria	3965
Figure 5 Diagnostic algorithm and triage for inpatient myocarditis	3968
Figure 6 Diagnostic algorithm and triage for outpatient myocarditis	3969
Figure 7 Diagnostic algorithm and triage for pericarditis	3970
Figure 8 Spectrum of myocarditis presentations and outcomes	3971
Figure 9 Diagnostic algorithm for acute chest pain presentation ...	3972
Figure 10 Diagnostic algorithm for acute heart failure presentation	3974
Figure 11 Diagnostic algorithm for arrhythmia presentation	3975
Figure 12 Management of cardiac tamponade	3977
Figure 13 Management of constriction	3978
Figure 14 The different courses of inflammatory myopericardial syndrome and the interplay between genetic background inflammation and autoimmunity beyond the initial infectious trigger	3982
Figure 15 Histopathological findings in myocarditis	3985
Figure 16 Proposed algorithm of medical therapy for pericarditis in adults (not including interventional therapies and pericardiectomy)	3992
Figure 17 Follow-up and risk stratification after acute myocarditis with arrhythmic presentation	3999
Figure 18 Stages of tuberculous pericarditis	4008
Figure 19 Triage and management of pericardial effusion	4012
Figure 20 Multidisciplinary teams for inflammatory myopericardial syndrome	4018

Abbreviations and acronyms

ACC	American College of Cardiology
ACS	Acute coronary syndrome
ADA	Adenosine deaminase

AF	Atrial fibrillation	ICU	Intensive care unit
AM	Acute myocarditis	IFN	Interferon
AMI	Acute myocardial infarction	IL	Interleukin
AP	Acute pericarditis	IL-1RA	Interleukin-1 receptor antagonist
ARVC	Arrhythmogenic right ventricular cardiomyopathy	IL-1RL1	IL-1 receptor-like 1
ATG	Anti-thymocyte globulin	IMPS	Inflammatory myopericardial syndrome
AVB	Atrioventricular block	i.v.	Intravenous
B19V	Parvovirus B19	IVIG	Intravenous immunoglobulins
CAD	Coronary artery disease	JVP	Jugular venous pressure
CD	Chagas disease	LA	Left atrial
CI	Confidence interval	LAG-3	Lymphocyte activation gene 3
CK	Creatinine kinase	LC	Lyme carditis
CK-MB	Creatinine kinase muscle-brain type	LGE	Late gadolinium enhancement
CMP	Cardiomyopathy	LLC	Lake Louise criteria
CMR	Cardiovascular magnetic resonance	LM	Lymphocytic myocarditis
CMV	Cytomegalovirus	LV	Left ventricle
COVID-19	Coronavirus disease 2019	LVAD	Left ventricular assist device
CP	Constrictive pericarditis	LVEF	Left ventricular ejection fraction
CPB	Cardiopulmonary bypass	MACE	Major adverse cardiac events
CRT	Cardiac resynchronization therapy	MCS	Mechanical circulatory support
CS	Cardiac sarcoidosis	miRNAs	MicroRNAs
CT	Computed tomography	NDLVC	Non-dilated left ventricular cardiomyopathy
CTLA-4	Cytotoxic T-lymphocyte antigen 4	NLRP3	NLR family pyrin domain containing 3
CTP	Cardiac tamponade	NSAID	Non-steroidal anti-inflammatory drug
DCM	Dilated cardiomyopathy	NSVT	Non-sustained ventricular tachycardia
DNA	Deoxyribonucleic acid	NT-proBNP	N-terminal prohormone of brain natriuretic peptide
DSP	Desmoplakin	OR	Odds ratio
EAM	Electro-anatomical mapping	P/LP	Pathogenic/likely pathogenic
EBV	Epstein–Barr virus	PaM	Pregnancy-associated myocarditis
ECG	Electrocardiogram	PCIS	Post-cardiac injury syndrome
ECP	Effusive–constrictive pericarditis	PCR	Polymerase chain reaction
ECV	Extracellular volume	PD-1	Programmed cell death protein 1
EF	Ejection fraction	PD-L1	Programmed death ligand 1
EGPA	Eosinophilic granulomatosis with polyangiitis	PEff	Pericardial effusion
EM	Eosinophilic myocarditis	PPCM	Peripartum cardiomyopathy
EMB	Endomyocardial biopsy	PPS	Post-pericardiotomy syndrome
ESC	European Society of Cardiology	PVS	Programmed ventricular stimulation
ESR	Erythrocyte sedimentation rate	RA	Rheumatoid arthritis
FDG-PET	Fluorodeoxyglucose positron emission tomography	RAP	Right atrial pressure
FM	Fulminant myocarditis	RCM	Restrictive cardiomyopathy
FMF	Familial Mediterranean fever	RCT	Randomized controlled trial
GCM	Giant-cell myocarditis	RNA	Ribonucleic acid
GDMT	Guideline-directed medical therapy	RP	Recurrent pericarditis
GLS	Global longitudinal strain	RV	Right ventricle
HAART	Highly active antiretroviral therapy	SARS-CoV-2	Severe acute respiratory syndrome coronavirus 2
HCM	Hypertrophic cardiomyopathy	SCD	Sudden cardiac death
HCV	Hepatitis C virus	SLE	Systemic lupus erythematosus
HES	Hypereosinophilic syndrome	SSc	Systemic sclerosis
HF	Heart failure	TB	Tuberculosis
HHV-6	Human herpesvirus 6	TDI	Tissue Doppler imaging
HIV	Human immunodeficiency virus	TF	Task Force
HR	Hazard ratio	TNF- α	Tumour necrosis factor alpha
hs-TnI	High-sensitivity troponin I	TRAPS	Tumour necrosis factor receptor-associated periodic syndrome
hs-TnT	High-sensitivity troponin T	TTE	Transthoracic echocardiography
HT	Heart transplantation	uIFN- γ	Unstimulated interferon gamma
IABP	Intra-aortic balloon pump	VA	Ventricular arrhythmias
ICD	Implantable cardioverter-defibrillator		
ICI	Immune checkpoint inhibitor		

VA-ECMO	Veno-arterial extracorporeal membrane oxygenation
VAD	Ventricular assist device
VF	Ventricular fibrillation
VT	Ventricular tachycardia
WCD	Wearable cardioverter-defibrillator
WMA	Wall motion abnormalities

1. Preamble

Guidelines evaluate and summarize available evidence with the aim of assisting health professionals in proposing the best diagnostic or therapeutic approach for an individual patient with a given condition. ESC Guidelines are intended for use by health professionals but do not override their individual responsibility to make appropriate and accurate decisions in consideration of each patient's health condition and in consultation with the patient or the patient's caregiver where appropriate and/or necessary. It is also the health professional's responsibility to verify the rules and regulations applicable in each country to drugs and devices at the time of prescription and to respect the ethical rules of their profession.

ESC Guidelines represent the official position of the ESC on a given topic. Guideline topics are selected for updating after annual expert review of new evidence conducted by the ESC Clinical Practice Guidelines (CPG) Committee. ESC Policies and Procedures for formulating and issuing ESC Guidelines can be found on the ESC website (<https://www.escardio.org/Guidelines/Clinical-Practice-Guidelines/Guidelines-development/Writing-ESC-Guidelines>).

This guideline updates and replaces the previous version of the ESC Guidelines on pericarditis from 2015. For the first time it also covers myocarditis. This Task Force was selected by the ESC to include professionals involved with the medical care of patients with this pathology and to include patient representatives and methodologists. The selection procedure included an open call for authors and aimed to include

members from across the whole of the ESC region and from relevant ESC Subspecialty Communities. Consideration was given to diversity and inclusion.

Guidelines Task Forces perform a critical review and evaluation of the published literature on diagnostic and therapeutic approaches including assessment of the risk–benefit ratio. Recommendations are based on major randomized trials and relevant systematic reviews and meta-analyses, when available. Systematic literature searches are conducted in cases of controversy or uncertainty to ensure that all key studies were considered. For recommendations related to diagnosis and prognosis, additional types of evidence are included, such as diagnostic accuracy studies and studies focused on the development and validation of prognostic models. The strength of each recommendation and the level of evidence supporting it are weighed and scored according to predefined criteria as outlined in [Tables 1](#) and [2](#). Patient-reported outcome measures (PROMs) and patient-reported experience measures (PREMs) are also evaluated when available as the basis for recommendations and/or discussion in these guidelines.

Evidence tables summarizing key information from relevant studies are generated to facilitate the formulation of recommendations, to enhance comprehension of recommendations after publication, and to reinforce transparency in the guidelines development process. The tables are published in their own section of ESC Guidelines and reference specific recommendation tables.

After an iterative process of deliberations, a first Task Force vote on all recommendations is conducted prior to the initiation of rounds of review. A second Task Force vote on all recommendations is conducted after the final round of review and revision. For each vote, the Task Force follows ESC voting procedures and all recommendations require at least 75% agreement among voting members to be approved. Voting restrictions may be applied based on declarations of interests.

Table 1 Classes of recommendations

	Definition	Wording to use	
Classes of recommendations	Class I	Evidence and/or general agreement that a given treatment or procedure is beneficial, useful, effective.	Is recommended or is indicated
	Class II	Conflicting evidence and/or a divergence of opinion about the usefulness/efficacy of the given treatment or procedure.	
	Class IIa	Weight of evidence/opinion is in favour of usefulness/efficacy.	Should be considered
	Class IIb	Usefulness/efficacy is less well established by evidence/opinion.	May be considered
	Class III	Evidence or general agreement that the given treatment or procedure is not useful/effective, and in some cases may be harmful.	Is not recommended

Table 2 Levels of evidence

Level of evidence A	Data derived from multiple randomized clinical trials or meta-analyses.
Level of evidence B	Data derived from a single randomized clinical trial or large non-randomized studies.
Level of evidence C	Consensus of opinion of the experts and/or small studies, retrospective studies, registries.

©ESC 2025

The writing and reviewing panels provide declaration of interest forms for all relationships that might be perceived as real or potential sources of conflicts of interest. Their declarations of interest are reviewed according to the ESC declaration of interest rules, which can be found on the ESC website (<http://www.escardio.org/doi>) and are compiled in a report published in a supplementary document with the guidelines. Funding for the development of ESC Guidelines is derived entirely from the ESC with no involvement of the healthcare industry.

The CPG Committee supervises and co-ordinates the preparation of new guidelines and approves their publication. In addition to review by the CPG Committee, ESC Guidelines undergo multiple rounds of double-blind peer review on a dedicated online review platform. The review is conducted by topic experts, including members from ESC National Cardiac Societies and from relevant ESC Subspecialty Communities. Guideline Task Forces consider all review comments and are required to respond to all those classified as major. After appropriate revisions, the Task Force and the CPG Committee members approve the final document for publication in the *European Heart Journal*.

Unless otherwise stated, ESC Guidelines content refers to sex, understood as the biological condition of being male or female, defined by genes, hormones and sexual organs. Off-label use of medication may be presented in this guideline if a sufficient level of evidence shows that it can be considered medically appropriate for a given condition. However, decisions on off-label use must be made by the responsible health professional giving special consideration to ethical rules concerning healthcare, the specific situation of the patient, patient consent, and country-specific health regulations.

2. Introduction

Myocarditis and pericarditis are inflammatory diseases of the myocardium and pericardium, respectively, with potential overlap. These are the first ESC clinical practice guidelines covering the whole spectrum of these diseases.

Herein, the Task Force (TF) introduces the term 'inflammatory myopericardial syndrome' (IMPS). IMPS is an umbrella term during the initial

diagnostic process until a final diagnosis is made (Figure 1). It reflects the possible myocarditis–pericarditis overlap, aiming to increase the awareness of the spectrum of disease, and to allow timely diagnosis and better management. IMPS ranges from isolated myocarditis to isolated pericarditis through mixed forms with possible reciprocal involvement, such as myopericarditis and perimyocarditis. Both terms are commonly used in the medical literature, and defined in the 2015 ESC Guidelines for the diagnosis and management of pericardial diseases (see Section 8).¹

The rationale for the introduction of IMPS is that myocarditis and pericarditis have similar aetiologies and are anatomical contiguous structures with possible secondary involvement.^{2–5}

The field has experienced rapid growth, with position statements proposed by different cardiac societies.^{6–10} In the past, several consensus statements were provided, usually defining a proven myocarditis based on endomyocardial biopsy (EMB). Endomyocardial biopsy is able to detect the histological type, can identify some specific aetiologies, and can help to differentiate from non-inflammatory cardiomyopathies (CMPs).¹⁰ But nowadays multimodality imaging has become a cornerstone for the diagnosis of myocardial and pericardial inflammation and cardiovascular magnetic resonance (CMR) plays a crucial role, as reported in other ESC guidelines^{11–13} (Figure 2).

The aim of these guidelines is to provide evidence-based guidance for clinical management of IMPS, to guide clinicians of all subspecialties from a clinical point of view, and to ensure qualified shared decision-making with patients (see Section 13 and Supplementary data online, Section 8).

2.1. What is new

Guidelines on pericarditis have been published twice before,^{1,15} while myocarditis will be covered for the first time in a guideline. The TF believes that combined guidelines with the recognition of the spectrum of disease are a step in a new direction, enabling a paradigm shift towards therapy based on the combined input from experts in inflammatory diseases of the myocardium and pericardium, with the support of a multidisciplinary team. In order to improve the awareness of the spectrum of disease, a new category, 'inflammatory myopericardial syndrome (IMPS)', will be introduced as an umbrella term to increase the understanding of the potential myocarditis–pericarditis overlap.

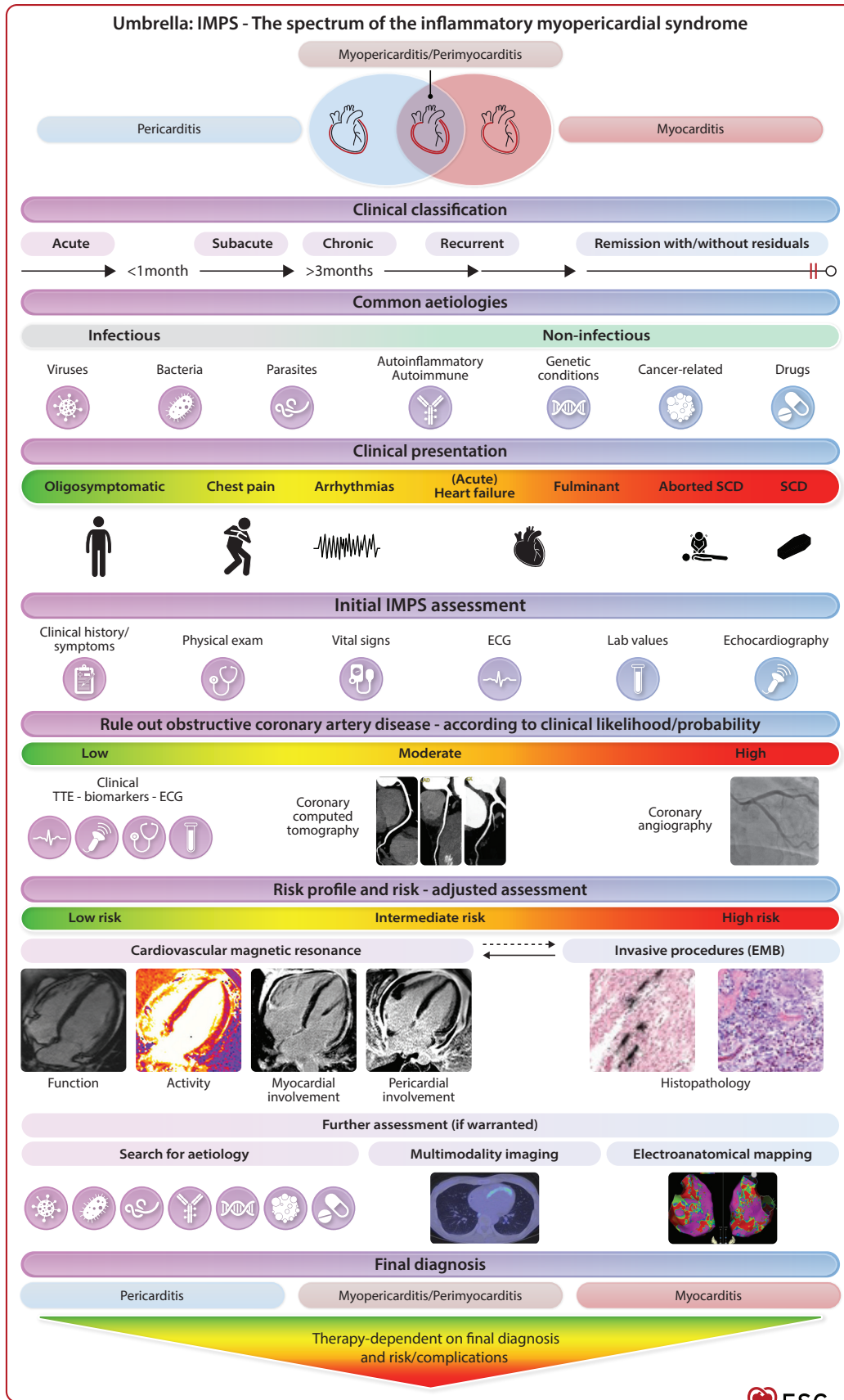


Figure 1 Central illustration of the ESC guidelines on myocarditis and pericarditis. ECG, electrocardiogram; EMB, endomyocardial biopsy; IMPS, inflammatory myopericardial syndrome; SCD, sudden cardiac death; TTE, transthoracic echocardiography.

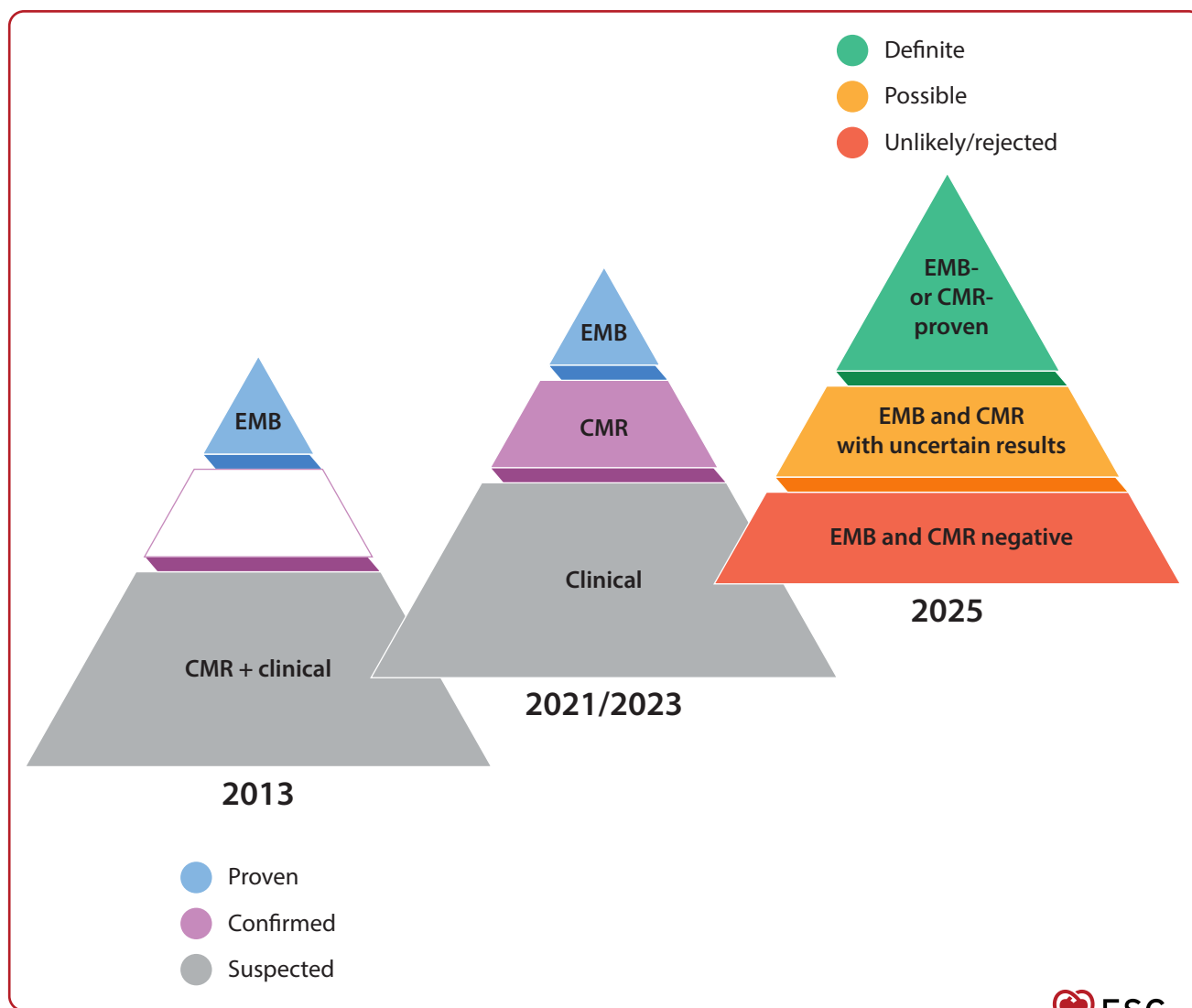


Figure 2 Paradigm change in the clinical diagnosis of myocarditis. CMR, cardiovascular magnetic resonance; EMB, endomyocardial biopsy. Both EMB and CMR can provide a definitive clinical diagnosis but with different indications. Details are given in Section 5. 2013 Reference: Caforio *et al.*¹⁰ 2021 and 2023 References: Keren *et al.*, Law *et al.*^{6,14}

It is introduced as an entering diagnostic term to lead to a tailored work-up and individualized therapy. Patient-oriented case management is proposed in different settings such as diagnosis and therapy, as well as return to work and play avoiding strict time definitions, since the remission pathway differs from patient to patient. In addition, a novelty in the field of IMPS is the improved knowledge on its possible genetic background and its link to specific inherited CMPs. Furthermore, a paradigm shift will be introduced in its diagnostic management. This is reflecting the new capabilities of multimodality imaging, especially CMR, as it has changed clinical workflow during recent years. A similar change was introduced in the American College of Cardiology (ACC) consensus statement in 2024.⁹ Endomyocardial biopsy has its place and is needed if specific decisions are warranted.

In comparison with the last ESC Guidelines for the diagnosis and management of pericardial diseases,¹ the current understanding

of the pathogenesis of pericarditis has greatly improved with new evidence on the importance of the interplay between inflammation and autoinflammatory mechanisms, the role of genetic background, and immune responses in patients with multiple recurrences. The identification of a positive family history, a poor response to colchicine, and a clinical presentation with an inflammatory or non-inflammatory phenotype are useful tools to guide the selection of patients for genetic testing and specific pharmacological options. A new class of drugs targeting interleukin-1 (IL-1), the so-called anti-IL-1 agents, has become available and is used in recurrent cases with a poor response to other conventional therapies. Nevertheless, we need to further improve our understanding of the pathogenesis of non-inflammatory disease forms.

Moreover, diagnostic capabilities have increased, thanks to the role of multimodality imaging, allowing improved diagnostic accuracy and

individualized duration of therapies according to clinical and imaging findings.

The TF recommends establishing a multidisciplinary IMPS team to ensure optimal patient care in complicated cases.

We firmly believe that recognizing IMPS will enhance the understanding of these inflammatory conditions and hope it will inspire further research to advance personalized diagnostic and therapeutic approaches.

3. Epidemiology, classification, stages, diagnostic criteria and aetiology

3.1. Epidemiology

Population-based studies of the incidence or prevalence of IMPS are limited, and most epidemiological studies assess disease burden and sequelae in selected patient groups, such as those admitted to hospital. However, such studies might underestimate the true disease burden. For example, the rate of patients diagnosed with acute myocarditis (AM) increases from 5% to 13% with the use of CMR among patients with angina-like symptoms and increased high-sensitivity troponin T (hs-TnT).¹⁶ A different registry reported an incidence of 6.3–8.6 per 100 000 inhabitants, mostly in young men.¹⁷ The current global burden of cardiovascular disease data reports a prevalence of 4.2–8.7 per 100 000 in the age range between 35 and 39 years.¹⁸ Men and younger patients are more likely to be diagnosed, although this could reflect the diagnostic bias towards these patient groups.¹⁹

In children <2 years of age, the sex distribution is balanced; in adolescents there is a male prevalence (about two-thirds of cases),^{20,21} which is also maintained in adult patients, suggesting the importance of hormonal factors.

The incidence of acute pericarditis (AP) is estimated to be about 3–32 cases per 100 000 person-years.^{22,23} Similar to myocarditis, men and younger individuals are more likely to be diagnosed. Recurrence occurs in about 20%–30% of patients within 18 months after a first episode of AP.²⁴ The recurrence rate increases up to 50% after the first recurrence.²⁵ Pericarditis is diagnosed in 0.2% of all cardiovascular in-hospital admissions and is responsible for 5% of emergency room admissions for chest pain.²³ In the observational Epidémiologie de la Douleur Thoracique (EPIDOULTHO) study, 3% of patients received a final diagnosis of IMPS.²⁶

3.2. Classification and stages

The field of IMPS gained increasing awareness and interest during the coronavirus disease 2019 (COVID-19) pandemic.²⁷ Research in the field of all forms of IMPS has a long history, and several terminologies exist. This is also reflected in the definition of stages. We are proposing a terminology from a clinical point of view with the intention of guiding the appropriate management of patients (Table 3). In addition, time frames for the stages (acute, subacute, and chronic) are suggested to be used for myocarditis and pericarditis. However, it is not always possible from a clinical point of view to identify the disease onset, for instance in subacute cases.¹

IMPS is characterized by different stages (see Figure 3). The course of the disease differs among patients. A patient may recover completely without any residuals, but others may develop complications, in some

Table 3 Terminology and stages

Terminology	Definition
IMPS	Umbrella term for inflammatory myocardial and pericardial syndromes
Myopericarditis	Predominant pericarditis ^a
Perimyocarditis	Predominant myocarditis ^b
Acute myocarditis	Duration of symptoms ≤4 weeks Fulminant if: <ul style="list-style-type: none"> • Acute onset²⁸ and haemodynamically unstable patients requiring inotropes or mechanical circulatory support
Complicated myocarditis	AM and ≥1 of the following: ²⁸ <ul style="list-style-type: none"> • LVEF <50% on echocardiogram • Sustained ventricular arrhythmias • Advanced heart block • Heart failure • Cardiogenic shock
Acute pericarditis	Duration of symptoms ≤4 weeks
Subacute/ongoing myocarditis	Duration of symptoms >4 weeks to ≤3 months
Subacute/incessant pericarditis ^c	Duration of symptoms >4 weeks to ≤3 months
Chronic myocarditis/pericarditis	Duration of symptoms >3 months
Inflammatory cardiomyopathy	Chronic myocarditis in association with cardiac dysfunction and ventricular remodelling with clinical phenotype of hypokinetic, either dilated or non-dilated cardiomyopathy with/without arrhythmogenic substrate
Recurrent myocarditis/pericarditis	New symptoms or disease activity after clinical remission
Remission without residuals	Regression/absence of symptoms, normalization of ECG, biomarkers, imaging abnormalities (echocardiography and CMR)
Remission with residuals	Regression/absence of symptoms, persistence of abnormalities on ECG, biomarkers and/or imaging (functional and/or structural abnormalities in echocardiography or CMR)

AM, acute myocarditis; CK-MB, creatine kinase muscle-brain type; CMR, cardiovascular magnetic resonance; ECG, electrocardiogram; IMPS, inflammatory myopericardial syndrome; LVEF, left ventricular ejection fraction.

^aPatients with definite criteria for pericarditis and elevated biomarkers of myocardial injury (high-sensitivity troponin I or T, CK-MB fraction) without newly developed regional or global impairment of left ventricular function in echocardiography or CMR.

^bPatients with definite criteria for pericarditis and elevated biomarkers of myocardial injury (high-sensitivity troponin I or T, CK-MB fraction) with newly developed regional or global impairment of left ventricular function in echocardiography or CMR.

^cIncessant/ongoing pericarditis: the term incessant pericarditis describes patients with persistent symptoms without a symptom-free interval of >4 weeks despite full-dose guideline-directed medical therapy (including corticosteroids), or those relapsing early during the tapering.

cases leading to death. Patients may not experience every stage. Complete remission can occur at every timepoint. However, a deep understanding of the respective stages is essential for appropriate therapeutic guidance.

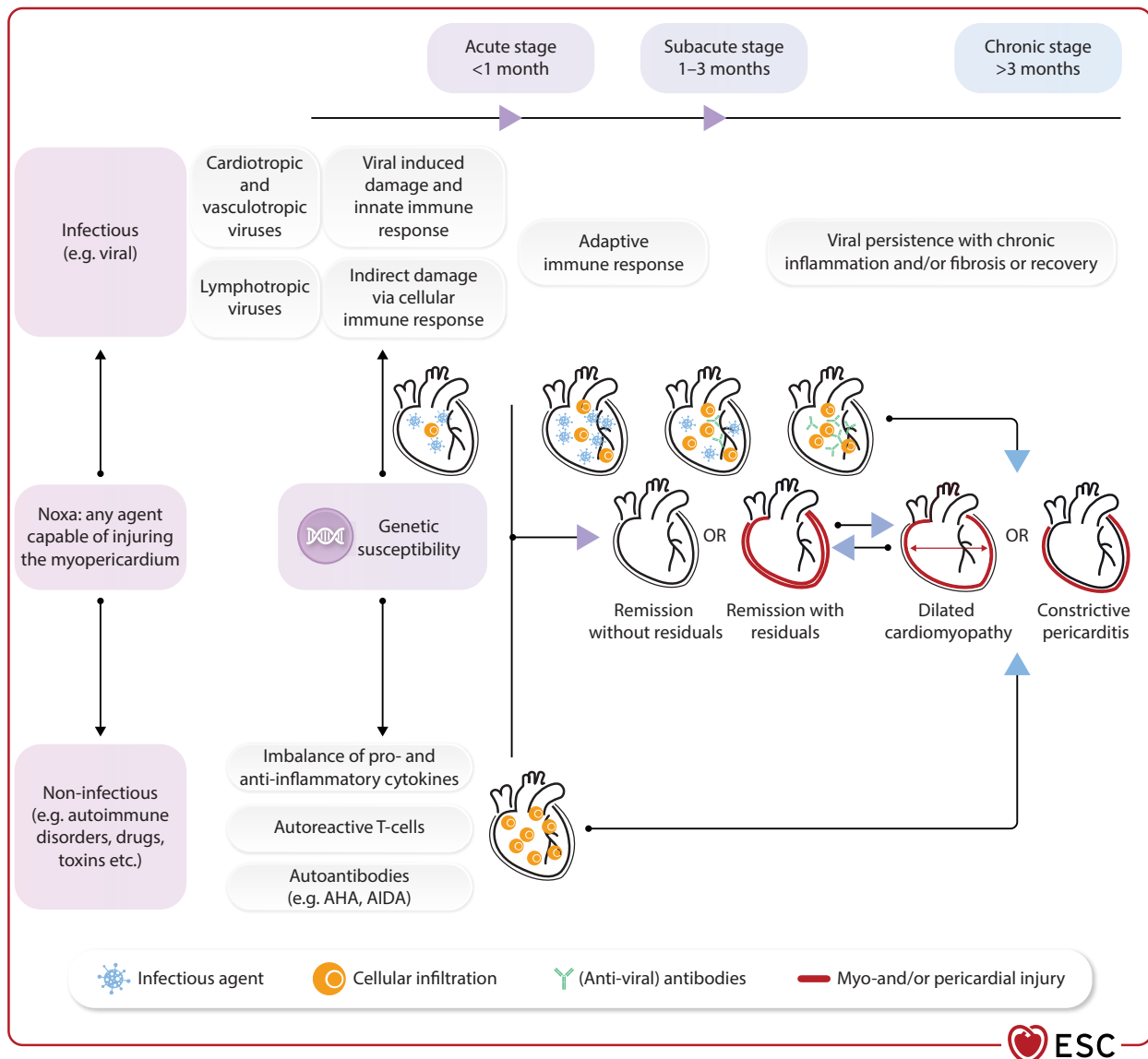


Figure 3 Stages of inflammatory myopericardial syndrome. AHA, anti-heart antibodies; AIDA, anti-intercalated disc antibodies.

3.3. Diagnostic criteria

After the original proposed diagnostic criteria from the consensus paper in 2013,¹⁰ multimodality imaging, in particular CMR, has made a clinical, non-invasive diagnosis of myocarditis feasible. In accordance with the paradigm change (Figure 2), the TF proposes new diagnostic criteria and a new classification, following the system introduced in the 2023 ESC Guidelines for the management of endocarditis (Table 4).²⁹ This clinically driven approach is based on a clinical presentation, with additional supportive findings, and positive CMR or EMB for myocarditis. Histopathological criteria and updated CMR Lake Louise criteria (LLC)³⁰ are given in Table 5 and Figure 4, respectively. Similarly, diagnosis of pericarditis can be made with a clinical presentation, and more than one additional criterion. Cardiovascular magnetic resonance can also provide the non-invasive confirmation of the presence of pericarditis beyond clinical criteria.

3.3.1. Diagnostic criteria for myocarditis

Myocarditis can be clinically diagnosed as definite/possible with an appropriate clinical presentation and additional criterion, including

CMR-proven or EMB-proven result (see details in Table 4). The additional criteria include common parameters in basic work-up, such as an electrocardiogram (ECG), which may show unspecific changes, including the whole spectrum of presentations from mimicking a myocardial infarction with ST elevation in non-coronary distribution, as well as rhythm abnormalities, or findings in echocardiography (see Section 5.5). Laboratory analysis of serum biomarkers usually shows elevation of markers of myocardial lesion, such as hs-TnT or high-sensitivity troponin I (hs-TnI). Biomarkers of heart failure (HF) (such as N-terminal pro-hormone of brain natriuretic peptide, NT-proBNP) are also needed to identify the severity of the disease, and suggest myocardial involvement. Depending on the individual case and risk (see Section 4), definitive diagnosis of myocarditis can be based on CMR (Figure 4) or EMB (Table 5). For EMB analysis quantitative immunohistochemistry criteria for inflammatory cells in lymphocytic myocarditis (LM) are under development. Asymptomatic cases may exist, e.g. vaccine- or drug-related cases, such as immune checkpoint inhibitor (ICI)-induced myocarditis, and are often underdiagnosed.

Table 4 Diagnostic criteria and classification for inflammatory myopericardial syndrome

IMPS		
If diagnostic criteria for myocarditis and/or pericarditis are fulfilled ^a		
	Myocarditis	Pericarditis
Definite	Clinical presentation ^b and CMR- or EMB-proven	Clinical presentation ^b with >1 additional criterion
Possible	Clinical presentation ^b with at least 1 additional criterion CMR- or EMB-uncertain or not available	Clinical presentation ^b with 1 additional criterion
Unlikely/rejected	Only clinical presentation ^b without additional criteria	Only clinical presentation ^b without additional criteria
Additional criteria beyond clinical presentations ^b		
	Myocarditis	Pericarditis
Clinical ^b	Non-specific findings	Pericardial rubs
ECG ^c	ST-T changes	PR depression, widespread ST-segment elevation
Biomarkers	Troponin elevation	C-reactive protein elevation
Imaging ^d	Abnormal strain, wall motion, reduced EF Myocardial oedema and/or LGE (CMR findings)	New or worsening pericardial effusion Pericardial oedema and/or LGE (CMR findings)

CMR, cardiovascular magnetic resonance; ECG, electrocardiogram; EF, ejection fraction; EMB, endomyocardial biopsy; IMPS, inflammatory myopericardial syndrome; LGE, late gadolinium enhancement; LLC, Lake Louise criteria.

Clinical presentations include chest pain or infarct-like symptoms, arrhythmias, heart failure, aborted sudden cardiac death.

Cardiovascular magnetic resonance categories: proven = 2 out of 2 updated LLC fulfilled (Figure 4); uncertain = only 1 out of 2 updated LLC fulfilled; rejected = negative CMR.

EMB categories: proven, uncertain, rejected (according to pathologist consensus).

^aOne condition may be leading (see Section 8).

^bSee detailed description of clinical presentation in Section 4; rarely asymptomatic cases may be detected (e.g. drug-related with a distinct history, such as immune checkpoint inhibitors).

^cIf ECG changes always consider/exclude myocarditis.

^dSee additional Sections 5.4–5.7 for detailed description of imaging findings.

Table 5 Histopathological criteria for myocarditis

Term	Predominant inflammatory cells	Myocyte necrosis	Infections PCR positive (viruses, etc.)
Active lymphocytic myocarditis	CD3 ⁺ T lymphocytes >7/mm ² , CD68 ⁺ macrophages	yes	yes/no
Persistent lymphocytic myocarditis	CD3 ⁺ T lymphocytes >7/mm ² , CD68 ⁺ macrophages	yes	yes/no
Resolved lymphocytic myocarditis	–	no	yes/no
Eosinophilic myocarditis (acute stage)	Eosinophils, CD3 ⁺ T lymphocytes, CD68 ⁺ macrophages	yes	yes/no
Giant-cell myocarditis (acute stage)	Eosinophils, CD68 ⁺ giant cells, CD3 ⁺ T lymphocytes, CD68 ⁺ macrophages	yes	no
Sarcoidosis	CD68 ⁺ giant cells, granuloma, CD3 ⁺ T lymphocytes, CD68 ⁺ macrophages	yes/no	no

PCR, polymerase chain reaction.

Non-ischæmic myocardial inflammation can be diagnosed by CMR according to the updated LLC³⁰ (see Figure 4). This is based on at least one T2-based criterion plus ideally one T1-based criterion. Having both a positive T2-based criterion and a T1-based criterion will increase specificity for diagnosing AM, but a diagnosis of possible myocarditis can

still be made by having only one (i.e. T2-based or T1-based) criterion in an appropriate clinical scenario, although with less specificity. Supportive criteria include pericardial abnormalities (which, however, suggest concomitant pericarditis), and global or regional left ventricular (LV) systolic dysfunction on cine imaging.

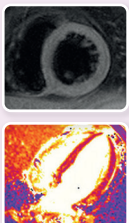
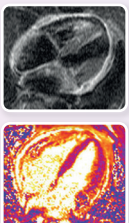
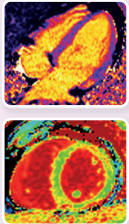
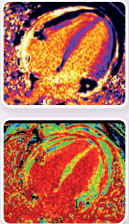
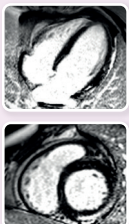
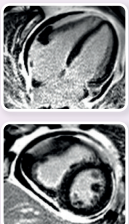
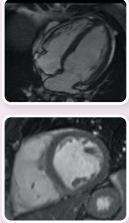
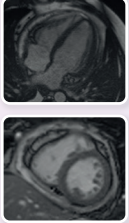
Criterion	Methods	Example images and pathology		Parameters for reporting	
				For myocarditis	For pericardial involvement
T2-based criterion	T2-weighted imaging or T2 mapping	Myocardial oedema 	Pericardial oedema 	<ul style="list-style-type: none"> • Presence, extent, and location of oedema (T2 weighted) • Regional high T2 SI or global high T2 SI (T2-weighted) • Regional or global increase of myocardial T2 times 	<ul style="list-style-type: none"> • High signal intensity of the pericardium in T2-mapping or T2-weighted imaging
T1-based criterion	Native T1 mapping/ post-contrast T1 mapping (ECV)/ T1-weighted imaging	Myocardial oedema/ diffuse fibrosis 	Pericardial oedema/ diffuse fibrosis 	<ul style="list-style-type: none"> • Description of focal increases • Regional or global increase of native myocardial T1 times • Regional or global increase ECV values 	<ul style="list-style-type: none"> • High signal intensity of the pericardium in T1-mapping
	Late gadolinium enhancement	Focal myocardial fibrosis/scar 	Pericardial inflammation/scar 	<ul style="list-style-type: none"> • Presence, pattern, extent, and location of LGE (positive if areas with high SI in a nonischaemic distribution pattern) • Thrombi (if present) • Total LGE/LV mass (%) (no routine) 	<ul style="list-style-type: none"> • High signal intensity of the pericardium in LGE images
Supportive criterion	Cine imaging	Functional and wall motion abnormalities 	Haemodynamic compromise 	<ul style="list-style-type: none"> • Regional wall-motion abnormalities • Cardiac function (e.g. LVEF, RVEF) and volume parameters 	<ul style="list-style-type: none"> • Presence, composition, and extent of pericardial effusion • Haemodynamic relevance of pericardial effusion • Diameter of pericardial effusion
Updated Lake Louise Criteria (LLC) for myocarditis					
CMR-proven myocarditis = 2 out of 2 updated LLC main criteria fulfilled	T2-based criterion Myocardial oedema	Abnormal T2-mapping or T2-weighted imaging	Supportive criteria Pericardial abnormalities Systolic LV-dysfunction		
CMR-uncertain myocarditis = only 1 out of 2 updated LLC main criteria fulfilled	T1-based criterion Non-ischaemic myocardial injury	Abnormal T1-mapping, ECV or LGE			



Figure 4 Diagnostic criteria by cardiovascular magnetic resonance based on the updated Lake Louise criteria. CMR, cardiovascular magnetic resonance; ECV, extracellular volume; LGE, late gadolinium enhancement; LLC, Lake Louise criteria; LV, left ventricle; LVEF, left ventricular ejection fraction; RVEF, right ventricular ejection fraction; SI, signal intensity ratio.³⁰ Presence of pericardial effusion suggests concomitant pericarditis.

Histopathological Dallas criteria,³¹ in addition to immunohistological staining to detect CD3⁺ T cells and CD68⁺ macrophages, are required to identify specific histological subtypes of myocarditis and to differentiate from phenocopies [e.g. arrhythmogenic right ventricular cardiomyopathy (ARVC)].^{32,33} New quantitative criteria are presently required, since the ESC criteria of ≥ 14 leucocytes/mm² including ≥ 7 CD3⁺ T cells/mm² have been questioned by cardiopathologists.¹⁰ In addition, molecular analysis of EMB and blood [including assessment of viral deoxyribonucleic acid (DNA) or ribonucleic acid (RNA) in peripheral leucocytes and in plasma] using quantitative polymerase chain reaction (PCR) is necessary to identify the aetiopathogenesis of myocarditis and allow targeted therapies (antiviral or immunosuppressive/immunomodulatory), if clinically useful.^{10,32,34} Examples are given in Section 5.9.1.

3.3.2. Diagnostic criteria for pericarditis

Pericarditis is an inflammatory pericardial syndrome with or without pericardial effusion (PEff). The definite clinical diagnosis can be made with a clinical presentation and more than one additional criterion (Table 4). The main presenting symptom is usually chest pain (85%–90% of cases), which is typically sharp and pleuritic, improves by sitting up and leaning forward, and is exacerbated by inspiration, lying down, and deglutition, due to increased attrition between inflamed pericardial layers. Dyspnoea can be reported by the elderly, or right HF signs and symptoms in the case of pericarditis with constriction. Arrhythmic presentations are rare and are usually associated with atrial fibrillation (AF). Additional criteria include a pericardial friction rub ($\leq 33\%$ of cases), which is a superficial scratchy or squeaking sound, caused by friction between the two inflamed pericardial layers. Electrocardiogram changes have been historically reported as a typical hallmark of AP; however, the pericardium is electrically silent, so ECG changes imply concomitant inflammation of the myocardium, warranting investigation for concurrent myocarditis.³⁵ On imaging, new or worsening PEff (up to 60% of cases), which is generally mild, might be detected. As pericarditis classically manifests with an inflammatory syndrome, elevated laboratory markers of inflammation, such as C-reactive protein (79%–90%),³⁶ erythrocyte sedimentation rate (ESR), and neutrophilic leucocytosis,^{37,38} can provide additional supportive criteria. The inflamed pericardium is neovascularized and contrast-enhanced on computed tomography (CT) and CMR. Cardiovascular magnetic resonance is superior for tissue characterization and can reveal pericardial oedema and/or pericardial late gadolinium enhancement (LGE), providing additional imaging criteria for the diagnosis.

3.4. Aetiology of myocarditis and pericarditis

Myocardial and pericardial diseases share mostly similar aetiologies (see Supplementary data online, Table S1). The aetiology of IMPS can be either infectious or non-infectious. These can trigger IMPS in a genetically predisposed individual by inflammatory/autoimmune mechanisms. However, the prevalence of each aetiology and the impact of the causative agent on the clinical course, prognosis, and therapeutic approach may differ between the two entities.^{1,10}

3.4.1. Aetiology of myocarditis

The most common infectious aetiology is presumed to be viral.^{10,39,40} Enteroviruses, adenoviruses, parvovirus B19 (B19V) and some

herpesviruses [Epstein–Barr virus (EBV), human herpesvirus 6 (HHV-6)], as well as influenza and coronaviruses, are the most common viruses associated with myocarditis (Supplementary data online, Table S1). Non-cytotoxic viruses trigger myocarditis indirectly by activating the immune system.^{41,42} Bacterial infection with *Borrelia* species [Lyme carditis (LC)] and parasitic infections, such as *Trypanosoma cruzi* [Chagas disease (CD)], are additional important aetiologies in specific regions of the globe.

However, several non-infectious aetiologies should be recognized, including systemic diseases, autoimmune (or likely autoimmune) disorders [systemic lupus erythematosus (SLE), systemic sclerosis (SSc), rheumatoid arthritis (RA), eosinophilic granulomatosis with polyangiitis (EGPA), hypereosinophilic syndrome (HES)], immune-mediated forms [such as LM, giant-cell myocarditis (GCM), eosinophilic myocarditis (EM), and cardiac sarcoidosis (CS)], inflammatory bowel disorders, drugs and toxic reactions (including ICI-associated myocarditis, see Section 9.6.1.1) and chest radiation, as well as genetic conditions such as inherited CMP (see Section 5.3);^{10,39} see Supplementary data online, Table S1.¹⁰

3.4.2. Aetiology of pericarditis

The aetiology largely depends on the epidemiological background, patient population, and clinical setting.^{1,10} Idiopathic or viral pericarditis is the most frequent aetiology in developed countries, ranging from 50% in inpatient settings to >80% in outpatient settings.^{43–48} Tuberculosis (TB) is responsible for about 70% of all cases, especially in human immunodeficiency (HIV)-infected patients, in regions where the disease is endemic. An increasing number of cases are related to interventional procedures and surgery [post-cardiac injury syndrome (PCIS)] due to the increased number of procedures performed and the ageing population.⁴⁹ Other common causes include systemic inflammatory/autoimmune diseases and cancer (especially lung and breast cancer or lymphomas and leukaemia) (see Supplementary data online, Table S1).¹

About 5%–15% of patients with recurrence have genetic mutations, sometimes related to a monogenic autoinflammatory disease, mainly familial Mediterranean fever (FMF) and tumour necrosis factor receptor-associated periodic syndrome (TRAPS).^{50,51} A genetic predisposition and an autoinflammatory/immune-mediated pathogenesis are also suspected in patients with multiple recurrences. For additional information see Supplementary data online, Tables S2 and S3.^{50–52}

4. Clinical presentation of inflammatory myopericardial syndrome

The term IMPS includes a spectrum of inflammatory diseases from isolated myocarditis to isolated pericarditis through a combination of both. IMPS should be used as an umbrella term during the initial diagnostic work-up until the final diagnosis is made. One of the major challenges for the diagnosis of IMPS is recognition itself, therefore the TF highlighted red flags (Table 6). These symptoms and signs should suggest IMPS. The red flags for IMPS are mainly clinical signs, accompanied by serological and/or imaging biomarkers, and are not equivalent to the risk. Red flags for IMPS are warning signs, aiming to raise the awareness of the disease. If there is a suspicion of IMPS, staging based on the risk assessment should be performed (Table 7).

Table 6 Red flags for the clinical diagnosis of myocarditis and pericarditis

Myocarditis	Pericarditis
Recent or concomitant flu-like syndrome or gastroenteritis	Recent or concomitant flu-like syndrome or gastroenteritis
Infarct-like chest pain	Pleuritic/infarct-like chest pain
Palpitations	Right HF symptoms and signs of constriction
HF symptoms	Fever
ECG changes ^a	Pericardial rubs
Ventricular arrhythmias (isolated, complex)	C-reactive protein elevation
Syncope	Pericardial effusion
Haemodynamic instability	Pleural effusion
Elevated markers of myocardial lesion (hs-Tn, CK-MB elevation)	Polyserositis
Elevated markers of HF (NT-proBNP)	CMR imaging with pericardial oedema and/or LGE
Abnormal wall motion, increased wall thickness and/or impaired systolic function on imaging	
CMR imaging with myocardial oedema and/or LGE	

CK-MB, creatinine kinase muscle-brain type; CMR, cardiovascular magnetic resonance; ECG, electrocardiogram; HF, heart failure; hs-Tn; high-sensitivity troponin; LGE, late gadolinium enhancement; NT-proBNP, N-terminal prohormone of brain natriuretic peptide.

^aSee Section 5.1.

Table 7 Clinical risk stratification to guide work-up in inflammatory myopericardial syndrome

Risk	High risk	Intermediate risk	Low risk
Myocarditis	<ul style="list-style-type: none"> Acute HF/cardiogenic shock Dyspnoea NYHA III–IV refractory to medical therapy Cardiac arrest/syncope^a Ventricular fibrillation/sustained ventricular tachycardia^a High-level AV block^a 	<ul style="list-style-type: none"> New/progressive dyspnoea Non-sustained ventricular arrhythmias Persistent release or relapsing troponin 	Stable symptoms or oligosymptomatic
	Imaging criteria:	Imaging criteria:	Imaging criteria:
	<ul style="list-style-type: none"> Newly reduced LVEF (<40%)^a Extensive LGE on CMR^a 	<ul style="list-style-type: none"> Newly mildly reduced LVEF (41%–49%) and/or WMA Preserved LVEF (≥50%) and LGE ≥2 segments on CMR 	<ul style="list-style-type: none"> Preserved LVEF (≥50%) without LGE or limited LGE (<2 segments) on CMR
Pericarditis	<ul style="list-style-type: none"> Signs and symptoms of cardiac tamponade Fever (temperature >38°C) Effusive–constrictive pericarditis Failure of NSAID therapy Incessant pericarditis 	<ul style="list-style-type: none"> Signs and symptoms of right HF 	<ul style="list-style-type: none"> Response to adequate therapy within 1–2 weeks
	Imaging criteria:	Imaging criteria:	Imaging criteria:
	<ul style="list-style-type: none"> Large PEff (>20 mm end-diastole) Cardiac tamponade Extensive pericardial LGE on CMR 	<ul style="list-style-type: none"> Moderate–large PEff (10–20 mm end-diastole) Constrictive physiology regardless of the size of the effusion 	<ul style="list-style-type: none"> Absence or mild PEff Absence of pericardial LGE on CMR

AV, atrioventricular; CMR, cardiovascular magnetic resonance; HF, heart failure; LGE, late gadolinium enhancement; LVEF, left ventricular ejection fraction; NSAID, non-steroidal anti-inflammatory drug; NYHA, New York Heart Association classification; PEff, pericardial effusion; WMA, wall motion abnormalities.

^aThese criteria do not lead directly towards endomyocardial biopsy; in these scenarios it is a case-by-case decision depending on the suspected underlying cause.

A fast and reliable diagnosis is crucial for proper management. The initial step involves triaging patients by assessing their risk factors and ruling out acute coronary syndrome (ACS), whenever indicated by the patient's characteristics and clinical presentation. In addition, myocarditis

warrants consideration whether the first contact was inpatient or outpatient.^{53,54} This approach is based on the different national healthcare systems, given that a patient may be first seen in an outpatient or inpatient setting (Figures 5–7).

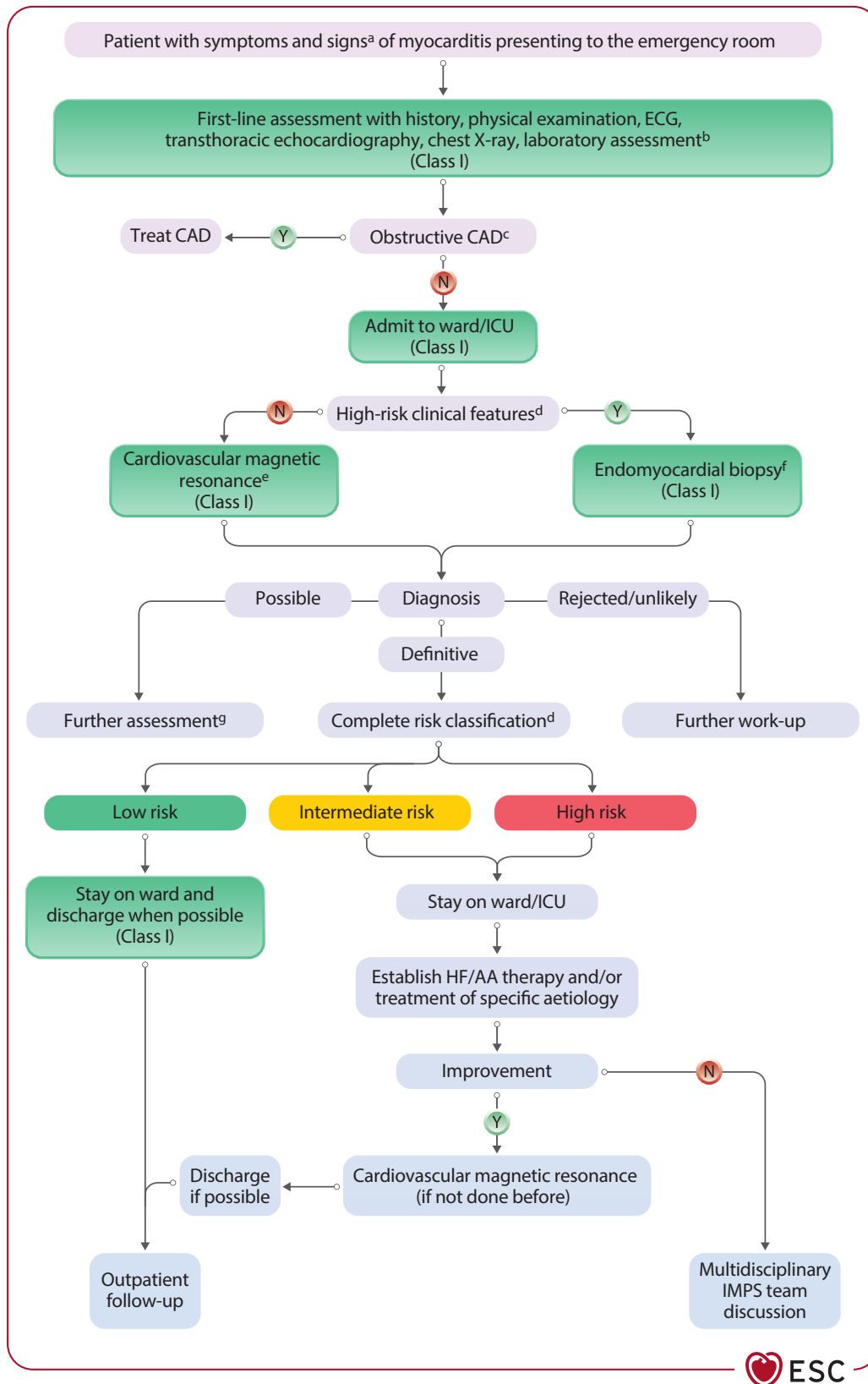
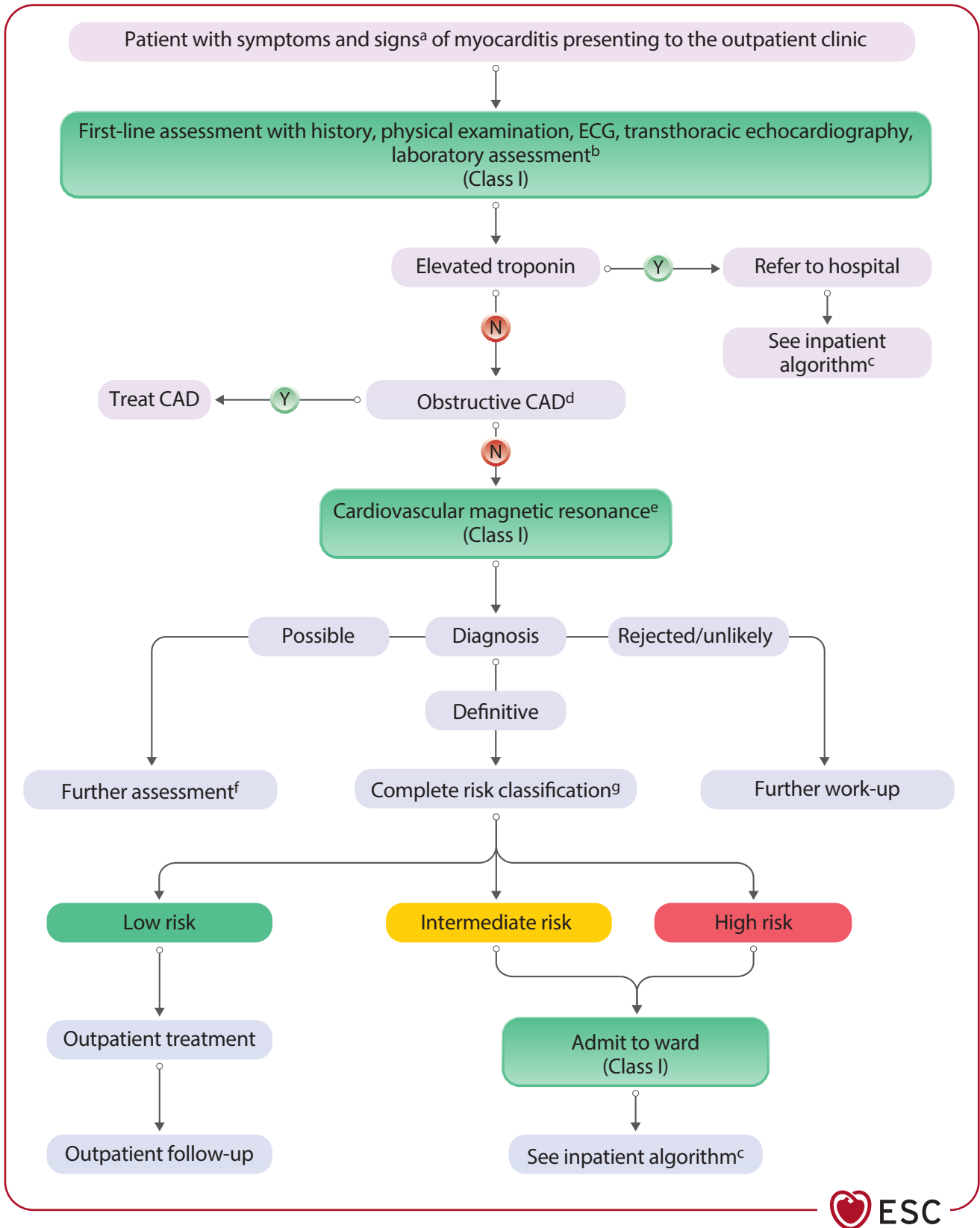


Figure 5 Diagnostic algorithm and triage for inpatient myocarditis. AA, anti-arrhythmic therapy; CAD, coronary artery disease; CRP, C-reactive protein; ECG, electrocardiogram; HF, heart failure; ICU, intensive care unit; IMPS, inflammatory myopericardial syndrome; N, no; NT-proBNP, N-terminal pro-hormone of brain natriuretic peptide; Y, yes. ^aSee Table 6. ^bLaboratory testing including troponin, NT-proBNP, C-reactive protein, differential blood count. ^cInvasive coronary angiography or computed tomography angiography depending on clinical likelihood/probability. ^dSee Table 7. ^eConsider endomyocardial biopsy. ^fConsider cardiovascular magnetic resonance. ^gSee Table 9.



Downloaded from https://academic.oup.com/eurheartj/article/46/40/3952/8234483 by guest on 13 April 2026



Figure 6 Diagnostic algorithm and triage for outpatient myocarditis. CAD, coronary artery disease; CRP, C-reactive protein; ECG, electrocardiogram; N, no; NT-proBNP, N-terminal prohormone of brain natriuretic peptide; Y, yes. ^aSee Table 6. ^bLaboratory testing including troponin, NT-proBNP, C-reactive protein, differential blood count. ^cSee Figure 5. ^dInvasive coronary angiography or computed tomography angiography depending on clinical likelihood/probability. ^eDepending on clinical situation (heart failure, arrhythmias) admit to ward. ^fSee Table 9. ^gSee Table 7.

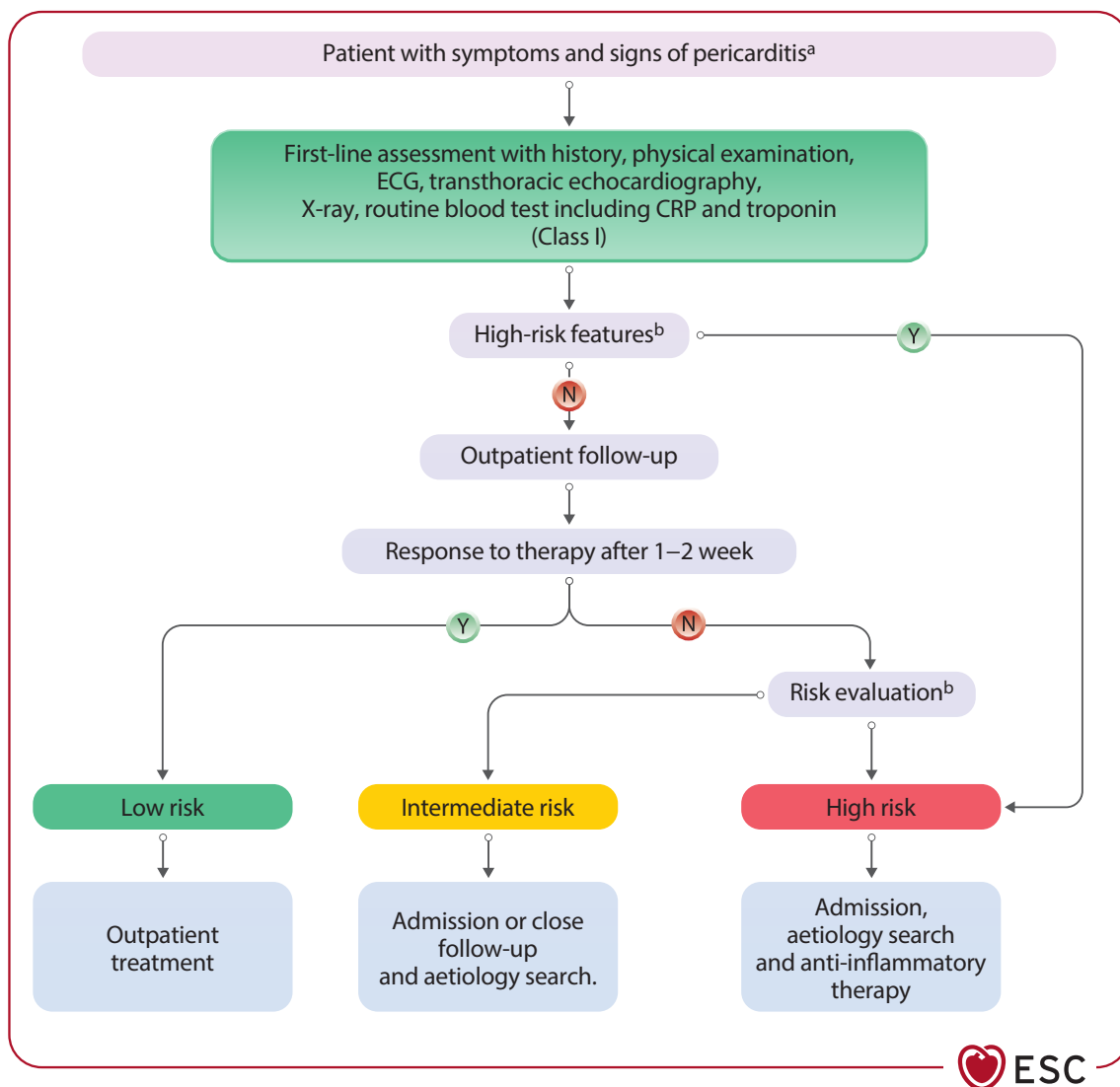


Figure 7 Diagnostic algorithm and triage for pericarditis. CRP, C-reactive protein; ECG, electrocardiogram; N, no; Y, yes. ^asee Table 6. ^bIf a patient has one or more prognostic predictors, as reported in Table 7, a high-risk patient must be admitted to hospital, and an aetiology search should be performed. Patients without high-risk features can be managed as outpatients without an aetiology search and admission if there is a good response to empirical anti-inflammatory therapy.

4.1. General symptoms and signs

The most common symptom of myocarditis and pericarditis is chest pain (sometimes with infarct-like features, especially for myocarditis, or pleuritic with respiratory changes, especially for pericarditis). Other common presentations include dyspnoea (myocarditis with HF presentation, but it is also the most common symptom in the elderly with pericarditis) and/or arrhythmias of different degrees (mainly ventricular for myocarditis and supraventricular and AF for pericarditis) and, less frequently, syncope. Flow charts are provided for each type to guide the diagnostic pathway (see Section 4.3).

Some patients may present with persistent symptoms without remission and are labelled as patients with incessant/ongoing IMPS.

4.2. Clinical stages of myocarditis

4.2.1. Acute myocarditis

Acute onset is defined as symptoms and signs lasting ≤ 4 weeks.²⁸ In myocarditis, this entails AM and the subtype fulminant myocarditis (FM).

The presentation of AM can vary from very mild symptoms to a life-threatening condition.¹⁰ The typical symptoms and signs at presentation include chest pain in $>80\%$ of cases, and dyspnoea in 20%–50%, while fatigue, palpitations, and syncope are less common and are reported in about 5%.^{28,32,55} In the majority of cases (80%), symptoms are preceded by prodromes, such as fever (60%), gastrointestinal complaints (30%), or respiratory symptoms (25%).^{28,55,56} Other extracardiac symptoms, depending on the underlying disease, can be present. Electrocardiogram is normal in a minority of patients (about 15%); most frequently, ST-segment elevation is present (57.5%), but other ST/T-segment changes can be found (23.5%), as well as conduction blocks (10%).^{28,55}

In most patients with acute presentation, cardiac enzymes [troponin T/I and creatinine kinase muscle-brain type (CK-MB)] are elevated.^{28,55} Echocardiography is important for clinical evaluation as it might reveal signs of myocarditis, including increased wall thickness and echogenicity due to myocardial oedema. PEff is seen in up to 25% of patients, reflecting concomitant pericarditis or related to haemodynamic factors.^{28,55}

4.2.2. Fulminant myocarditis

Fulminant myocarditis (occurring in 3%–9%) is characterized by cardiogenic shock at presentation for which haemodynamic support is needed.²⁸ Isolated right ventricle (RV) dysfunction is uncommon; however, biventricular failure occurs frequently in FM. Sustained ventricular arrhythmias (VA) may also occur in these patients (46.9%) and some present with sudden cardiac death (SCD) (25.8%).^{28,56,57}

In the majority of children with FM (usually <2 years of age), LV dysfunction with dilatation is present at initial presentation,⁴⁰ while there is usually no LV dilatation in the early phase for adults. Concurrent viral infections can be common in these children.

4.2.3. Subacute myocarditis

The subacute stage refers to cases with symptoms lasting >1 month but ≤3 months. The symptoms are unspecific, and patients might either have a remission without residuals or might progress to chronic myocarditis or inflammatory CMP (see Section 10).

4.2.4. Chronic myocarditis

Chronic myocarditis is myocarditis persisting beyond 3 months.³⁹ Chronic myocarditis might reflect an intermediate stage possibly leading to inflammatory CMP, characterized by cardiac remodelling and some degree of ventricular dysfunction.^{10,39}

Milder forms may appear as hypokinetic non-dilated forms of CMP.³⁹ Moreover, an arrhythmogenic substrate, due to fibrosis, should be considered for the management of these patients.^{39,58}

Symptoms may be unremarkable in chronic myocarditis.^{10,39} Dyspnoea and palpitations might be the leading symptoms.^{10,39} Biomarkers of myocardial injury are usually within normal limits.⁵⁹ Notably, elevated C-reactive protein, hs-TnT, and impaired global longitudinal strain (GLS) have been associated with EMB-proven

myocardial inflammation in patients with non-ischaemic HF.⁶⁰ New quantitative CMR techniques have improved the diagnostic yield in patients with chronic myocarditis.⁶¹

4.3. Clinical presentations of myocarditis

Myocarditis is characterized by the heterogeneity of clinical manifestations (Figure 8); therefore, the diagnosis requires a high level of suspicion. The main patterns of clinical presentation are infarct-like chest pain (most frequent symptom), arrhythmias, and HF. Severity may range from asymptomatic/oligosymptomatic to severe life-threatening scenarios, such as severe HF or VA (potentially leading to SCD). A clinical classification based on presentation as high-risk or non-high-risk myocarditis (see Table 7) has been shown to meaningfully predict outcomes in large cohorts.^{28,62,63} Moreover, myocarditis, especially when recurrent, may represent the 'hot phase' of some CMPs [e.g. desmoplakin (DSP)-related ARVC].⁶⁴ Details are given in Section 4.3.5.

4.3.1. Chest pain presentation

Chest pain is the most common form of clinical presentation (about 75% of unselected cases) in adolescents and adults.²⁸ It is commonly associated with an increase in necrosis biomarkers, such as troponin, often with ECG alterations (especially ST-segment elevation), which may mimic ACS, despite the absence of significant obstructive coronary artery disease (CAD). These cases are often labelled as infarct-like.⁶⁵ Patients with this presentation usually report a recent or concomitant viral infection, such as a respiratory tract infection or gastroenteritis, which often precedes myocarditis by several days to weeks (2–4 weeks). Usually, the presence of troponin release in the context of IMPS is not a negative prognostic marker, when associated with preserved biventricular function.^{4,66} Patients presenting with chest pain and normal left ventricular ejection fraction (LVEF) without wall motion abnormalities (WMA), no VA, and complete resolution of ECG abnormalities in the short term can

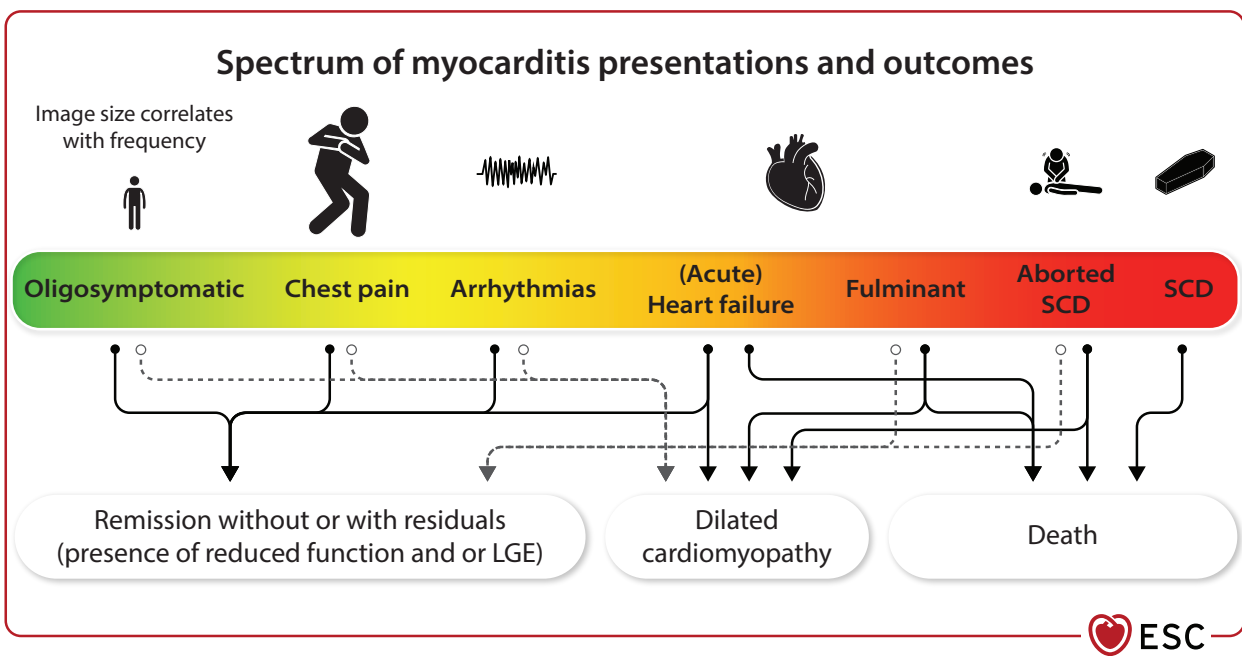


Figure 8 Spectrum of myocarditis presentations and outcomes. LGE, late gadolinium enhancement; SCD, sudden cardiac death. Image size correlates with presentation frequency (e.g. chest pain being the most common). Uncomplicated cases of myocarditis (about 75% of unselected cases) usually have spontaneous remission.²⁸ In acute myocarditis diagnosed by endomyocardial biopsy, up to 50% of patients have spontaneous recovery, but up to 25% may have a persistent stable cardiac dysfunction, while 10%–25% have a progressive ventricular dysfunction, which could lead to end-stage dilated cardiomyopathy, heart transplantation, or death.⁹

be considered as having a low-risk presentation with an excellent long-term prognosis.^{4,28,62,66,67} There are possible exceptions to this general rule in a few cases with EM and GCM. Myocardial scarring as detected by CMR can be present in cases with preserved LVEF.^{3,68–70} Focal scarring

of any cause was shown to be relevant for outcome, and small scars (e.g. <2 segments) after >6 months seemed to be more benign.⁷¹ Nevertheless, long-term outcome data are missing. For a proposed workflow see [Figure 9](#).

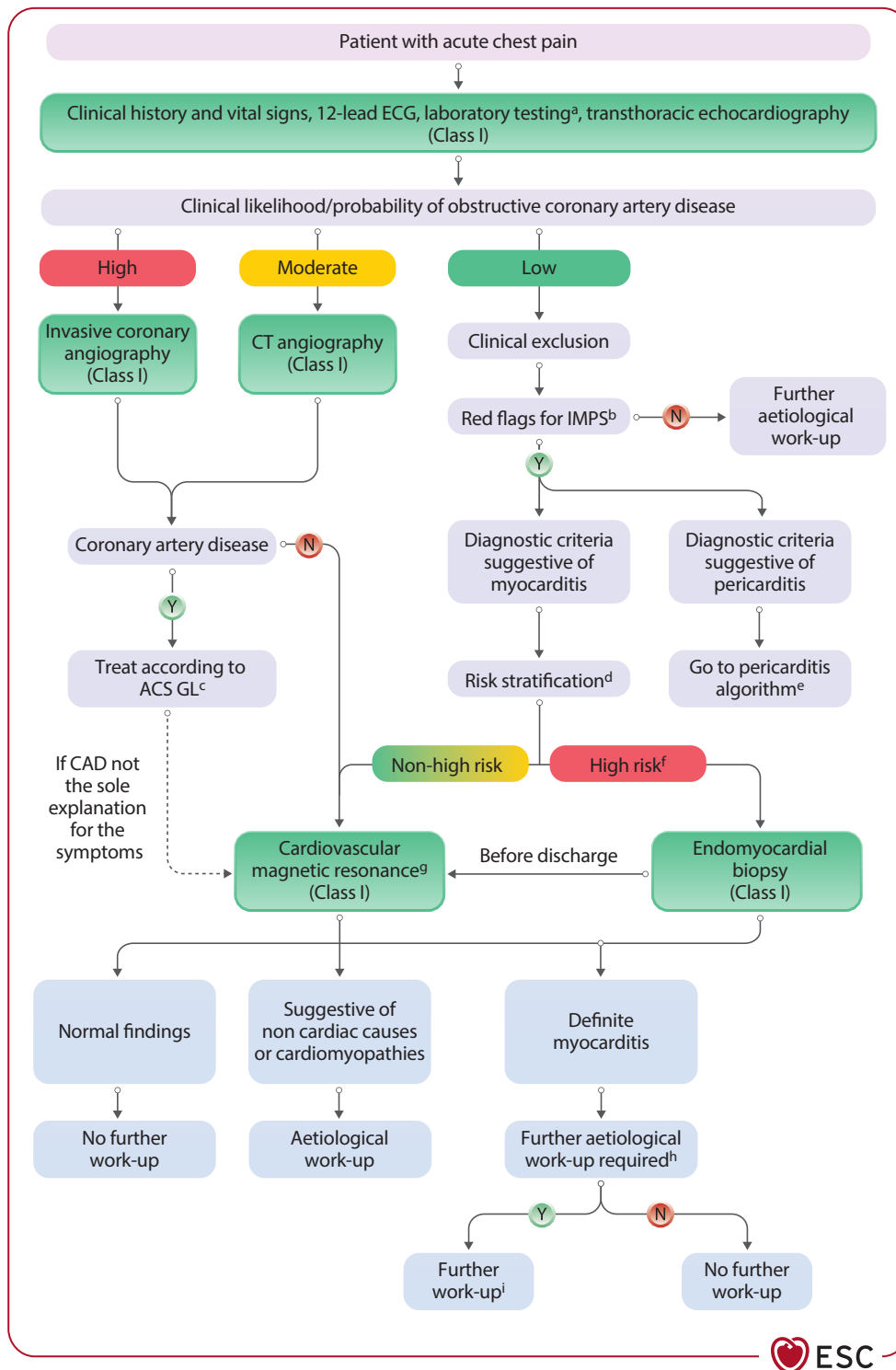


Figure 9 Diagnostic algorithm for acute chest pain presentation. ACS, acute coronary syndrome; CAD, coronary artery disease; CRP, C-reactive protein; CT, computed tomography; ECG, electrocardiogram; GL, guideline; IMPS, inflammatory myopericardial syndrome; N, no; NT-proBNP, N-terminal pro-hormone of brain natriuretic peptide; Y, yes. ^aLaboratory testing including troponin, NT-proBNP, C-reactive protein, differential blood count. ^bSee [Table 6](#). ^cReference: Byrne *et al.*⁷² ^dSee [Table 7](#). ^eSee [Figure 7](#). ^fConsider cardiovascular magnetic resonance. ^gConsider endomyocardial biopsy on a case-by-case basis. ^hDepending on the underlying cause and clinical need. ⁱSee [Sections 5, 8, 9, 10](#).

4.3.2. Heart failure presentation

Patients with myocarditis presenting with acute HF, in particular when associated with left ventricular dysfunction (LVEF \leq 40%), should be considered as a high-risk group, and their prognosis largely depends on the short-term response to therapy.^{28,62} Clinical presentation may range from unexplained impaired ventricular function (with or without dilated LV), new onset or worsening HF (usually over 2 weeks to 3 months), to rapidly progressive refractory HF and cardiogenic shock. Fulminant myocarditis presenting with HF has a higher rate of cardiac death and heart transplantation (HT) both in the short and long term, compared with patients with LV dysfunction without FM (see Section 4.2.2).^{56,73,74} In these scenarios, GCM and EM are independently associated with increased mortality.^{56,75} An algorithm for the proposed workflow is shown in Figure 10. As a central scheme, the workflow follows the CHAMPIT approach, provided in the 2021 ESC Guidelines for the diagnosis and treatment of acute and chronic heart failure.¹² One should be aware that arrhythmias can be a presentation of myocarditis, as well as an 'alternative cause' of HF outside the suspicion of myocarditis.

4.3.3. Presentation with arrhythmias

Patients with AM with new, recurrent, or unexplained arrhythmias may have a wide spectrum of symptoms, ranging from palpitations to syncope or life-threatening arrhythmias causing aborted SCD.^{10,76} Supraventricular arrhythmias, especially AF,^{63,77} are more common in the presence of concomitant pericarditis and PEff, while atrioventricular blocks (AVBs) or sustained VA are generally, but not exclusively, associated with LV dysfunction and HF. Patients with advanced AVB or sustained VA should be considered as high risk, even in the absence of LV dysfunction. Ventricular fibrillation (VF)/cardiac arrest occurs in about 2.5% of myocarditis-related hospitalizations.⁷⁸ Patients with sustained VA during AM have a high risk of recurrence.⁷⁹

Patients with GCM (see Section 9.3) or CS (see Section 9.4) are at a high risk of VA, with a prevalence of $>25\%$.^{80–82}

Scar-related VA can occur at any time during follow-up, even after inflammation resolution. However, polymorphic and irregular VA are more common during the active inflammatory phase, whereas monomorphic and regular VA are associated with healed myocarditis with residuals.⁸³ Consistently, catheter ablation of ventricular tachycardia (VT) is more effective when performed in the post-inflammatory stage of the disease rather than during AM.⁸⁴

AVB is a common feature of myocarditis related to non-viral infections (i.e. CD, LC, diphtheria),⁸⁵ and can also be an initial presentation of CS. In patients with arrhythmic presentation, genetic testing for CMP [ARVC/dilated CMP (DCM)/non-dilated left ventricular CMP (NDLVC)] should be considered (see Section 5.3).

An algorithm for the proposed workflow is shown in Figure 11.

4.3.4. Sudden cardiac death

One of the causes of SCD in young adults is myocardial inflammation associated with fatal arrhythmias. Sudden cardiac death attributed to myocarditis among autopsied patients ranged from 1.1% to 12%,^{87,88} and males show higher incidence rates of SCD than females, with an incidence rate ratio of 2.2.⁸⁸ Most individuals are asymptomatic before SCD; however, between 18% and 48% of

patients present with symptoms, including viral illness/malaise, syncope, nausea/abdominal pain, chest pain, and palpitations.^{87,88} Only 5% show cardiac symptoms in conjunction with an infective process.⁸⁷ These data highlight the need to suspect a diagnosis of myocarditis early enough. Late gadolinium enhancement in the mid-wall layer of the anteroseptal myocardial segments has been associated with higher rates of mortality and major VA, including SCD,^{3,89,90} even in the presence of preserved LVEF. Septal involvement in myocarditis can be associated with a worse prognosis in the presence of a specific genetic background, such as pathogenic desmosomal gene variants (see Section 5.3).^{91,92} Further studies are necessary to confirm these data.

4.3.5. Presentation of myocarditis with a potential genetic background

A complex interaction between genetic background and inflammation might be responsible for the heterogeneity of the clinical presentation of myocarditis. An inflammatory stimulus of the heart might unveil an increased genetic susceptibility to develop overt LV dysfunction or arrhythmogenic phenotypes. In this setting it is important to consider additional features, such as a family history of myocarditis/pericarditis, CMP, or SCD. Autosomal dominant gene defects may be associated with myocarditis.^{93–95} Certain autosomal recessive defects in genes encoding various components of the cardiac structure can predispose young individuals to myocarditis.^{95,96}

Different studies reported that patients with myocarditis and evidence of pathogenic/likely pathogenic (P/LP) desmosomal gene variants (mostly with DSP variants) have a higher incidence of adverse cardiovascular events, especially myocarditis recurrence and VA, than patients without.^{91,94} Episodes of acute chest pain with troponin elevation and normal coronary arteries may occur in about 15% of patients with DSP mutations and are associated with LV LGE in about 90% of cases.⁹⁷ Specific genetic P/LP variants may increase the susceptibility to superimposed myocarditis in ARVC, which may be the first clinical presentation in the natural history of the disease.^{64,98} The presence of so-called 'hot phases' (chest pain episodes accompanied by ECG changes and troponin release) represents a possible clinical presentation of ARVC, which often occurs in paediatric and young patients, as well as carriers of DSP genetic variants.^{99–101} Currently, the role of 'hot phases' in disease progression, as well as in arrhythmic risk stratification, remains to be clarified. For more details see Section 5.3.

4.4. Clinical stages of pericarditis

4.4.1. Acute pericarditis

Acute pericarditis is an inflammatory pericardial syndrome with or without PEff with an onset of ≤ 4 weeks. The clinical diagnosis is usually characterized by pleuritic and/or positional chest pain ($>80\%$ of cases). Dyspnoea is more common in the elderly.^{45,102} Physical examination may be characterized by pericardial friction rubs in up to one-third of cases, which could disappear with the presence of PEff. Pericardial effusion has been reported in up to 60% of cases, and it is usually mild. ECG changes, especially PR depression as an early sign and widespread ST-segment elevations, have been reported in up to 60% of cases, especially in young patients. This is suggestive of concomitant myocardial involvement, at least of mild degree.

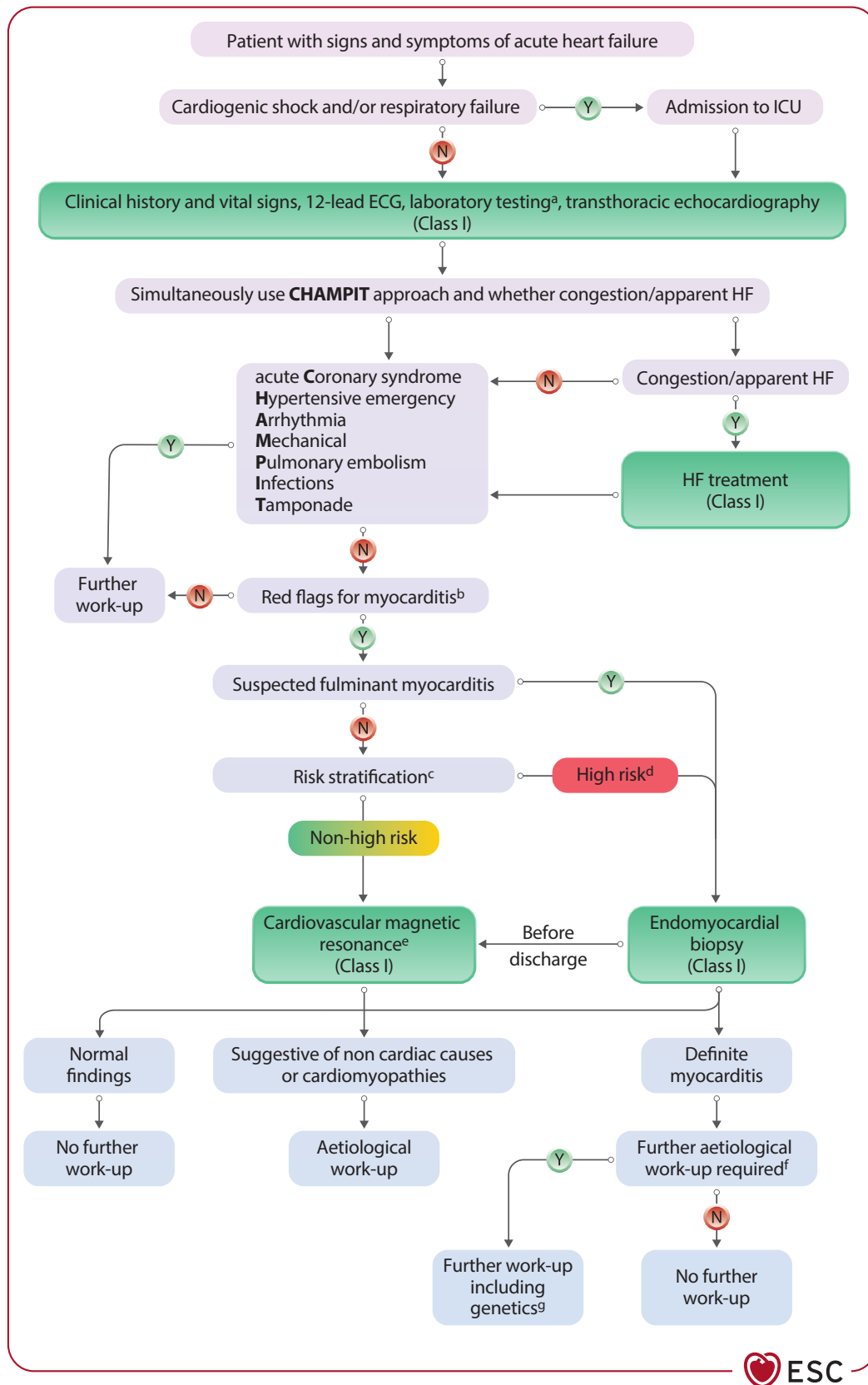


Figure 10 Diagnostic algorithm for acute heart failure presentation. CRP, C-reactive protein; ECG, electrocardiogram; HF, heart failure; ICU, intensive care unit; N, no; NT-proBNP, N-terminal prohormone of brain natriuretic peptide; Y, yes. ^aLaboratory testing including troponin, NT-proBNP, C-reactive protein, differential blood count. ^bSee [Table 6](#). ^cSee [Table 7](#). ^dConsider cardiovascular magnetic resonance. ^eIn stabilized heart failure patients, endomyocardial biopsy may be performed on a case-by-case basis. ^fDepending on the underlying cause and clinical need. ^gSee [Sections 5, 8, 9, 10](#).

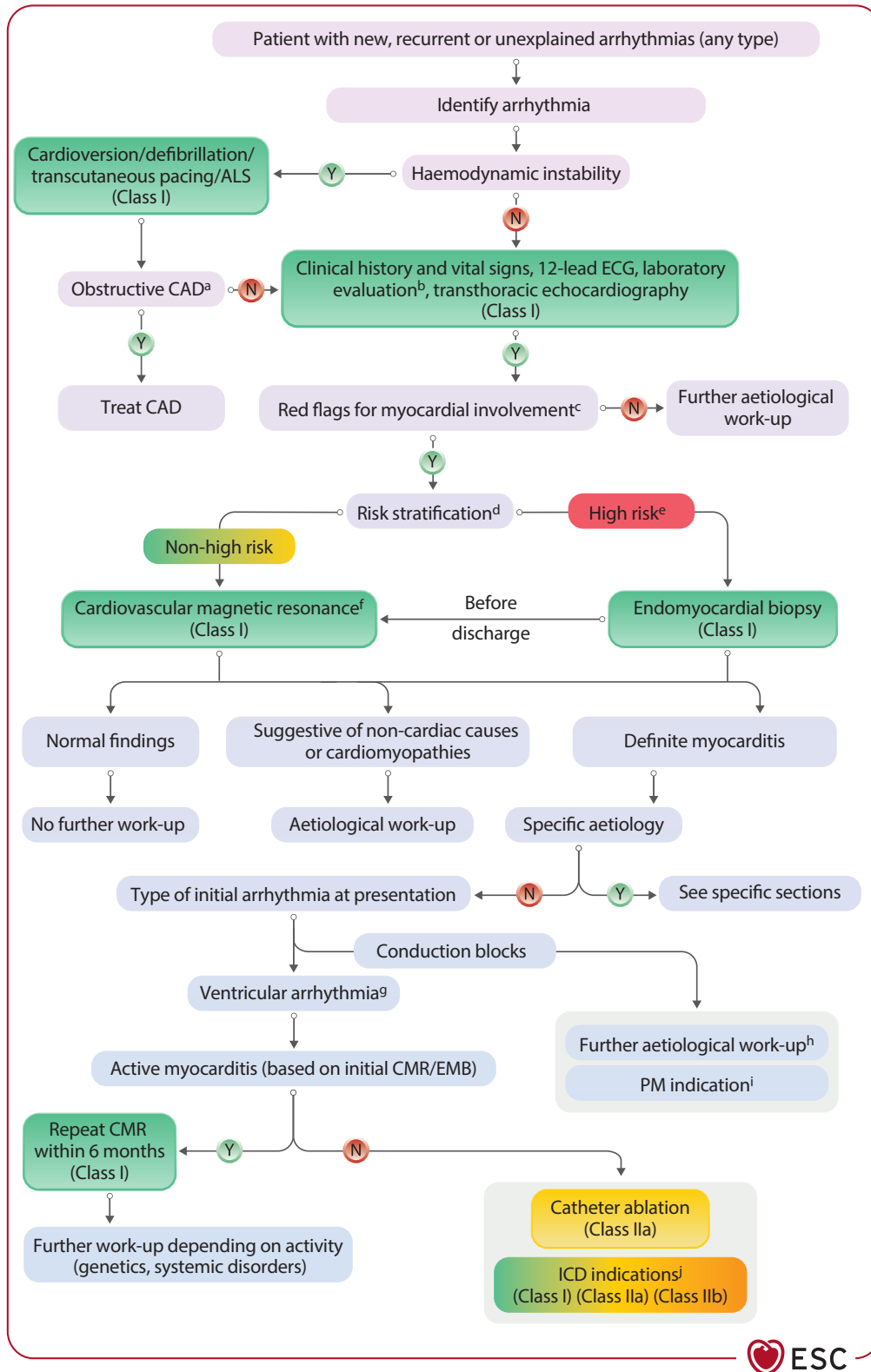


Figure 11 Diagnostic algorithm for arrhythmia presentation. ALS, advanced life support; CAD, coronary artery disease; CMR, cardiovascular magnetic resonance; CRP, C-reactive protein; ECG, electrocardiogram; EMB, endomyocardial biopsy; ICD, implantable cardioverter-defibrillator; N, no; NT-proBNP, N-terminal prohormone of brain natriuretic peptide; PM, pacemaker; Y, yes. ^aInvasive coronary angiography or computed tomography angiography depending on clinical likelihood/probability. ^bLaboratory testing including troponin, NT-proBNP, C-reactive protein, differential blood count. ^cSee Table 6. ^dSee Table 7. ^eConsider cardiovascular magnetic resonance. ^fConsider endomyocardial biopsy on a case-by-case basis. ^gSee Section 6.5 for wearable cardioverter-defibrillator. ^hSee Sections 5, 8, 9, 10. ⁱSee Section 6.5 and Reference Glikson et al.⁸⁶ ^jSee Section 6.5, Recommendation Table 14 and Reference Zeppenfeld et al.⁵⁸

An inflammatory syndrome is usually present with fever of $>38^{\circ}\text{C}$ (70%),³⁷ elevated markers of inflammation (C-reactive protein) (80%–90%),^{36,37} ESR, neutrophil leucocytosis,^{37,38} and pericardial and/or pleural effusion (approximately 50%), often with lung atelectasis, leading to a possible diagnosis of pleuro-pneumonia,^{37,103} and less commonly, peritoneal involvement (13%).³⁸ This presentation is labelled 'inflammatory phenotype' of AP.

Cardiac enzymes are usually normal, but troponin may be elevated in 20%–30% of cases, due to concomitant myocarditis (myopericarditis).⁴

4.4.2. Subacute pericarditis

Subacute pericarditis refers to cases with persistent symptoms lasting >1 month and <3 months. This condition may directly progress to constrictive pericarditis (CP) within a few months and requires timely optimal medical therapy and close follow-up to prevent chronic evolution.¹⁰⁴

4.4.3. Chronic pericarditis

Chronic pericarditis refers to cases lasting >3 months. In pericarditis, management of the patient during the acute phase is of paramount importance, not only for symptom relief but, most importantly, for prognostic purposes. Hospitalization of patients with AP and high-risk features allows the prompt identification and treatment of potentially life-threatening complications, such as cardiac tamponade (CTP).¹⁰⁵ Moreover, appropriate screening for specific aetiologies is the basis for tailored therapy. Progression of AP to subacute or chronic disease is sometimes unpredictable. Omission of colchicine administration and the use of high doses of corticosteroids with fast tapering are risk factors for recurrences or a chronic course of the disease.^{24,106–109} Recently, scores that predict the individual risk of complicated pericarditis and chronicity have been proposed for the identification of subjects who require intensive therapy in terms of medication dose and length, as well as close follow-up.^{43,44,110} They require further validation in prospective, multicentre studies.

In chronic forms, symptoms are similar to previous attack(s), but often milder.¹ In unclear cases or in difficult-to-treat patients, CMR may be performed to assess the degree of inflammation and individualize medical therapy, especially before drug tapering or discontinuation.^{111,112}

Paradoxically, although chronic pericarditis significantly impairs quality of life, the rate of progression to CP is negligible ($<1\%$) and is lower than the risk imposed by a single episode of AP, unless a specific aetiology is identified.^{105,113,114}

4.5. Clinical presentations of pericarditis

Pericarditis is characterized by a wide spectrum of clinical presentations. The main presenting symptom of pericarditis is positional chest pain, which is reported in most affected individuals. Typical pericardial pain is sharp and is worse when coughing and taking a deep breath (pleuritic). Left trapezius ridge pain is a classic symptom of pericardial irritation and is transmitted through the phrenic nerve. Other less common symptoms include shortness of breath, fever, fatigue, and arrhythmia (e.g. AF). Pericardial effusion often accompanies pericarditis ($>50\%$ of cases). Other presentations include right HF-like symptoms [elevated jugular venous pressure (JVP), peripheral oedema, ascites] when constriction is present. Hypotension is a sign of CTP (which presents with Beck's triad: hypotension, jugular venous distension, and muffled heart sounds). It is crucial to differentiate pericarditis from other diseases, such as ACS,

congestive HF, pneumonia with pleuritis, pulmonary embolism, chronic obstructive pulmonary disease, and vasculitis.

4.5.1. Dry pericarditis

Dry pericarditis (40%–50% of cases), also referred to as 'pericarditis sicca', is a form of pericarditis that is characterized by inflammation of the pericardium without the presence of PEff. It can begin insidiously or abruptly. It is usually not associated with a specific cause or a worse prognosis.

4.5.2. Effusive pericarditis

Effusive pericarditis (50%–60% of cases) is characterized by the concurrent presence of effusion.¹¹⁵ A moderate to large PEff is more commonly associated with a non-idiopathic aetiology.

4.5.3. Effusive–constrictive pericarditis

Effusive–constrictive pericarditis (ECP) is characterized by the concurrent presence of PEff, along with thickening and constriction of the pericardium that restricts the normal filling of the heart.¹¹⁶ Effusive–constrictive pericarditis occurs when constrictive physiology is uncovered following the drainage of a PEff with tamponade. The exact haemodynamic definition involves the right atrial pressure (RAP) failing to fall by $\geq 50\%$ or to a level of <10 mmHg despite intrapericardial pressure being lowered to near 0 mmHg with removal of pericardial fluid via pericardiocentesis.^{110,116,117} Current multimodality imaging allows a clinical diagnosis of ECP without cardiac catheterization.

4.5.4. Pericarditis with cardiac tamponade

The two most serious complications of pericarditis are CTP and CP. Pericarditis with CTP is a life-threatening condition where inflammation of the pericardium leads to the accumulation of compressive pericardial fluid (Table 8).^{110,115} Symptoms may include chest discomfort, fatigue, and dyspnoea. Clinical signs include hypotension, tachycardia, raised JVP, pulsus paradoxus, muffled heart sounds, electrical alternans with decreased ECG voltage, and an enlarged cardiac silhouette on chest X-ray. The magnitude of clinical and haemodynamic abnormalities depends on the amount of pericardial fluid and rate of accumulation, the distensibility of the pericardium, and the compliance and filling pressures of the cardiac chambers¹¹⁸ (Figure 12).

Table 8 Causes of cardiac tamponade

Common causes (in order of relative frequency):

- (1) Neoplasm/malignancy
- (2) Iatrogenic/trauma
- (3) Pericarditis
- (4) Tuberculosis (most common in developing countries)

Less common causes (in order of relative frequency):

- (1) Collagen vascular diseases (systemic lupus erythematosus, rheumatoid arthritis, scleroderma)
- (2) Pericardial injury syndrome
- (3) Acute myocardial infarction
- (4) Aortic dissection
- (5) Uraemia
- (6) Bacterial infection
- (7) Pneumopericardium

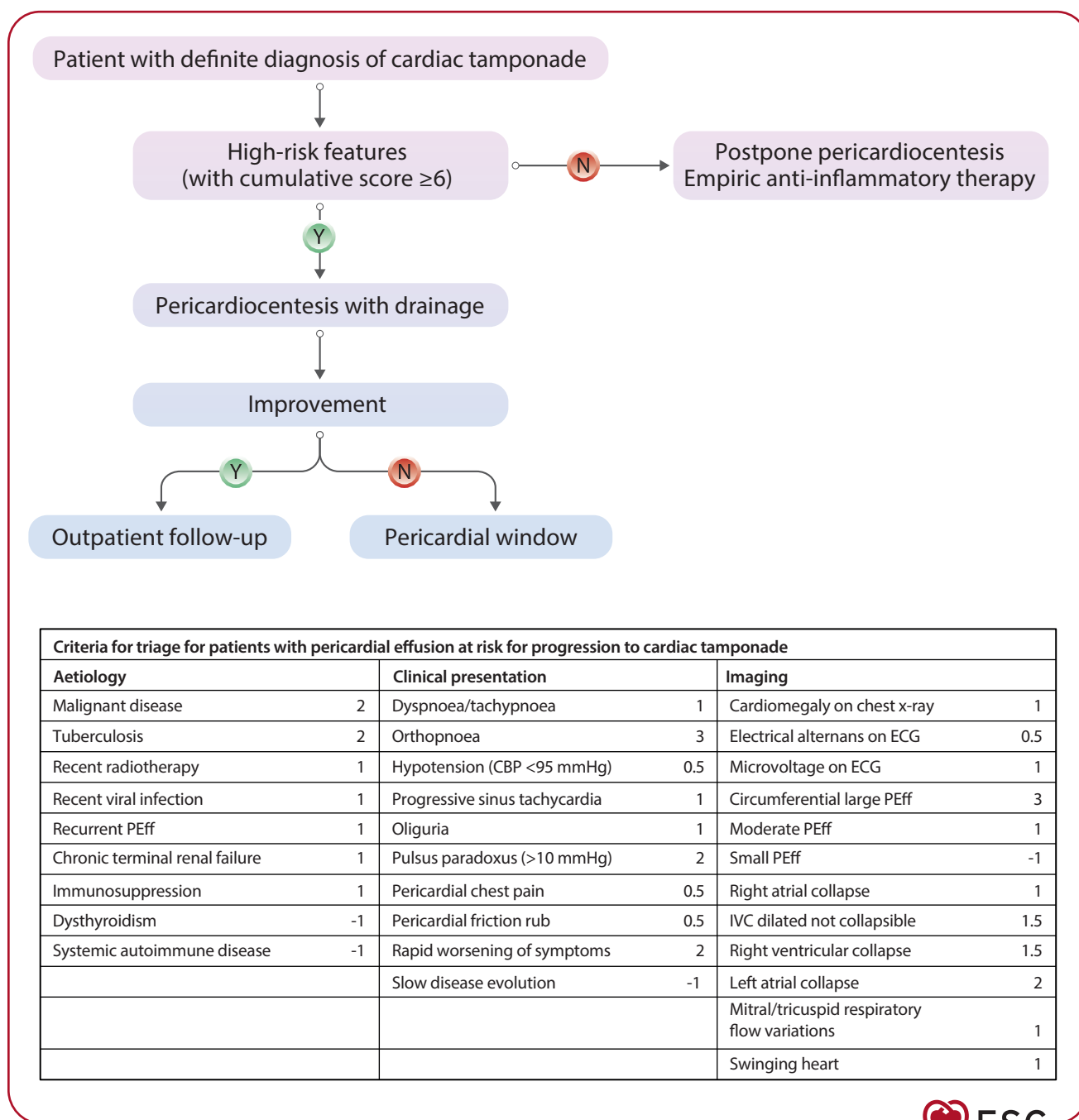


Figure 12 Management of cardiac tamponade. CBP, central blood pressure; ECG, electrocardiogram; IVC, inferior vena cava; N, no; PEff, pericardial effusion; Y, yes. Criteria are listed for the evaluation of patients by immediate or delayed pericardiocentesis based on expert consensus. Immediate pericardiocentesis should be considered if there are >6 points from at least two categories.

4.5.5. Constrictive pericarditis

Pericardial constriction is a chronic condition characterized by a thickened, fibrotic, and often calcified pericardium that leads to impaired diastolic filling of the heart. It should be named CP when associated with pericarditis. Constrictive pericarditis is a consequence of chronic pericardial inflammation and is characterized by scarring, fibrosis, and loss of elasticity of the pericardium. The main symptoms are dyspnoea,

oedema, orthopnoea, and fatigue. The classic clinical picture is usually characterized by isolated right HF with normal or nearly normal natriuretic peptide levels. Venous congestion, hepatomegaly, pleural effusions, and ascites may occur.^{110,115,119} Constrictive pericarditis should be treated empirically with anti-inflammatory therapy. Cases after failure of medical therapy and pericardial constriction without pericarditis should be referred for pericardiectomy without delay (Figure 13).

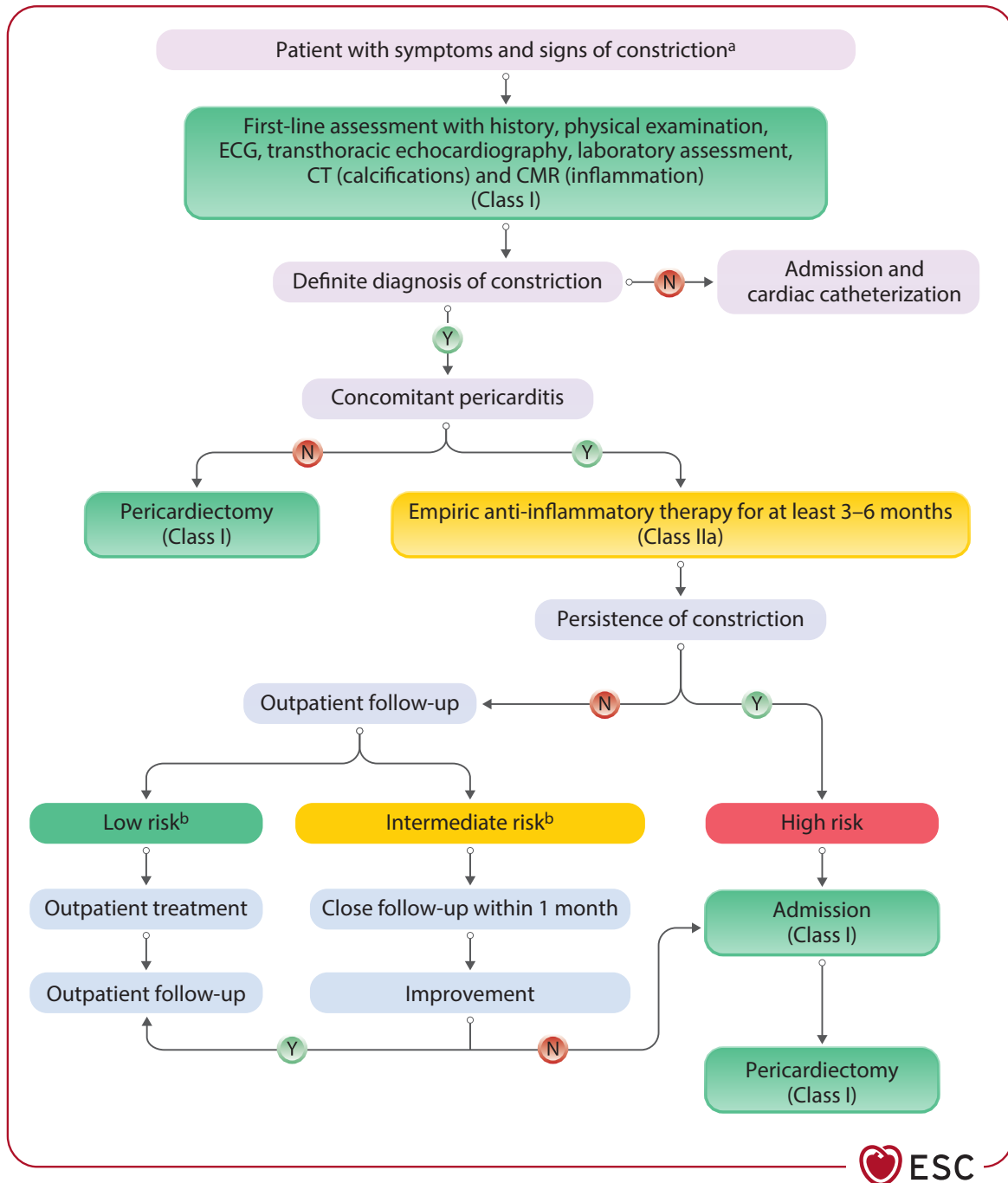


Figure 13 Management of constriction. CMR, cardiovascular magnetic resonance; CT, computed tomography; ECG, electrocardiogram; N, no; Y, yes. Empirical anti-inflammatory therapy is warranted only for those with evidence of pericarditis (by clinical criteria, biomarkers, and/or imaging). Low risk: clinical remission after therapy/normalization of imaging findings. Intermediate risk: improved symptoms without complete remission/partial regression. High risk: persistent symptoms/persistent imaging signs of constriction. ^aSee Table 6. ^bSee Table 7.

4.5.6. Transient constrictive pericarditis

Transient constriction is CP with ongoing inflammation that can be reversed following anti-inflammatory treatment or that heals spontaneously.

It develops with pericarditis with or without PEff (about 10% of cases) and resolves with anti-inflammatory therapy in >50% of cases.^{120,121} A trial of 3–6 months of anti-inflammatory therapy is recommended in patients with newly diagnosed CP before referral for

pericardiectomy.^{122,123} Biomarkers (e.g. elevated C-reactive protein) and multimodality imaging, including CMR, are mandatory to detect pericardial inflammation.

4.5.6.1. Constrictive pathophysiology

It is important to distinguish constrictive pathophysiology from actual HF symptoms.^{115,120,121,124} There may be features of septal bounce,

respiratory phase-dependent shift of the ventricular septum, and Doppler features of constriction without HF symptoms (see [Supplementary data online, Section 2.4](#) and [Figure S1](#)).

4.5.7. Pericarditis with polyserositis

Pericarditis with polyserositis is characterized by inflammation of the pericardium and concurrent inflammation of other serous membranes lining major body cavities, such as the pleura and peritoneum.^{37,103,125,126}

4.5.8. Inflammatory vs non-inflammatory pericarditis

In the context of pericarditis, the terms ‘inflammatory’ and ‘non-inflammatory’ phenotype refer to two distinct clinical presentations based on the underlying pathophysiological mechanisms.

4.5.8.1. Inflammatory phenotype of pericarditis

The inflammatory phenotype is characterized by inflammation of the pericardium with evidence of systemic inflammation. This phenotype is often associated with fever, and/or elevated systemic inflammatory markers (e.g. C-reactive protein), PEff, and/or pleural effusion. These forms typically respond well to targeted anti-inflammatory therapies, including colchicine and anti-IL-1 agents.^{37,127}

4.5.8.2. Non-inflammatory phenotype of pericarditis

The non-inflammatory phenotype refers to the manifestation of pericarditis without C-reactive protein elevation or low elevation of markers of systemic inflammation (e.g. high-sensitivity C-reactive protein).¹²⁷ This occurs in 10%–20% of patients with pericarditis.³⁶ The pathogenesis of pericarditis with normal C-reactive protein is unknown and these cases are often difficult to treat. C-reactive protein is a sensitive albeit unspecific biomarker of inflammation mainly driven by IL-6. Moreover, in autoimmune diseases characterized by the type I interferon (IFN) gene signature, C-reactive protein appears to be an unreliable marker of inflammation.⁵²

5. Diagnosis and diagnostic work-up

The diagnostic work-up in patients with suspected IMPS should be tailored based on the severity of clinical presentation, response to medical therapy, and individual risk ([Table 7](#)). It includes medical history, clinical/physical exam, biomarkers (myocardial injury, systemic inflammation, and HF), ECG, and multimodality imaging. Endomyocardial biopsy has its place in dedicated clinical scenarios. For IMPS, routine viral serology is not recommended,¹ except for HIV and hepatitis C virus (HCV), as well as for suspected bacterial infections (such as *Borrelia* spp., rickettsial, and *T. cruzi* infections). Echocardiography is the basic imaging method, followed by other techniques. Cardiovascular magnetic resonance is an advanced imaging test of increasing importance for detection of myocardial as well as pericardial injury.^{115,128} Most important is a patient-tailored approach, usually driven by the dominant symptoms. Flow charts ([Figures 5–7](#) and [9–13](#)) illustrate the proposed workflow in different clinical scenarios. If a patient presents with clinical symptoms suggestive of IMPS ([Table 6](#)), basic and advanced diagnostic assessments are recommended (see [Table 9](#)).

Recommendation Table 1 — Recommendations for clinical evaluation of myocarditis and pericarditis (see [Evidence Table 1](#))

Recommendations	Class ^a	Level ^b
Complete clinical evaluation, including history, physical examination, chest X-ray, biomarkers ^c , ECG, and echocardiography is recommended in all patients with a suspicion of myocarditis and/or pericarditis for the initial diagnostic assessment.	I	C
CMR is recommended in patients with the clinical suspicion of myocarditis (using updated LL criteria) ³⁰ and/or pericarditis for the non-invasive diagnosis of inflammatory reaction. ^{110,115,129}	I	B
Hospital admission is recommended for patients with high-risk pericarditis ^d for monitoring and treatment. ^{105,130}	I	B
Hospital admission is recommended for patients with moderate- to high-risk myocarditis ^d for monitoring and treatment.	I	C
EMB ^e is recommended in patients with high-risk myocarditis ^d and/or haemodynamic instability, and/or in patients with intermediate-risk myocarditis not responding to conventional therapy in order to detect a specific histologic subtype and to assess the presence of viral genome for treatment. ^{34,63,73,131}	I	C
Invasive coronary angiography or coronary CT, depending on clinical likelihood, is recommended in patients with IMPS if an acute coronary syndrome is suspected to rule out obstructive coronary artery disease.	I	C
Hospital admission should be considered for patients with low-risk myocarditis ^d for monitoring and treatment.	IIa	C
Pericardial or epicardial biopsy may be considered in relapsing pericardial effusion as part of the diagnostic work-up when the diagnosis cannot be reached with multimodality imaging and laboratory examinations.	IIb	C
Routine serology is not recommended in patients with myocarditis and/or pericarditis for the evaluation of viral aetiology except for hepatitis C, HIV, and Lyme disease.	III	C

CMR, cardiovascular magnetic resonance; CT, computed tomography; ECG, electrocardiogram; EMB, endomyocardial biopsy; HIV, human immunodeficiency virus; hs-TnI, high-sensitivity troponin I; hs-TnT, high-sensitivity troponin T; IMPS, inflammatory myopericardial syndrome; LL, Lake Louise; NT-proBNP, N-terminal prohormone of brain natriuretic peptide.

^aClass of recommendation.

^bLevel of evidence.

^cIncluding hs-TnT or hs-TnI, C-reactive protein, NT-proBNP.

^dSee [Table 7](#).

^eContemporary evaluation of EMB should be based on histology, immunohistology, and molecular pathology for detection of viral infections in myocardial and blood samples (see also [Table 11](#)).

Table 9 Basic and advanced level assessment

Basic assessment:
History: potential causes and triggers (viral infection of upper respiratory or gastrointestinal tract, toxins, drug use, medications), recurrent symptoms, family history of IMPS/cardiomyopathy/SCD, and systemic inflammatory/autoimmune diseases
Physical examination: assess clinical stability, symptoms (chest pain, HF symptoms, palpitations, syncope), malaise, general weakness and fatigue, pericardial friction rub, clinical symptoms/signs of CTP
ECG: PR-segment depression, ST/T-wave changes, AVB, and ventricular arrhythmias
Chest X-ray
Basic laboratory data:
Markers of myocardial lesion (e.g. hs-TnT/TnI)
Markers of systemic inflammation (e.g. C-reactive protein, ESR, WBC count)
Markers of heart failure (e.g. NT-proBNP)
Complete blood count (including eosinophilic count)
Renal function and electrolytes (e.g. sodium, potassium, creatinine)
Thyroid function (e.g. TSH)
Hepatic function and additional testing (e.g. lactate dehydrogenase, aspartate aminotransferase, alanine aminotransferase)
Echocardiography including strain imaging
Advanced assessment usually after admission:
Coronary anatomy evaluation (if needed for differential diagnosis by invasive coronary angiography or coronary CT depending on the clinical likelihood of ACS)
CMR to assess signs of myocardial and pericardial inflammation and/or fibrosis
Arrhythmia screening depending on risk stratification (e.g. Holter-ECG)
Additional laboratory parameters guided by clinical suspicion (e.g. if therapeutic consequences are expected)
Dedicated genetic testing if indicated
CT to assess concomitant pleuropulmonary diseases
Specific myocarditis: EMB in high-risk cases and in intermediate-risk cases on a case-by-case decision to detect specific histology and some aetiologies if needed
Specific pericarditis: diagnostic pericardiocentesis when indicated ^a

© ESC 2025

ACS, acute coronary syndrome; AVB, atrioventricular block; CMR, cardiovascular magnetic resonance; CT, computed tomography; CTP, cardiac tamponade; ECG, electrocardiogram; EMB, endomyocardial biopsy; ESR, erythrocyte sedimentation rate; HF, heart failure; hs-TnT/TnI, high-sensitivity troponin T/I; IMPS, inflammatory myopericardial syndrome; NT-proBNP, N-terminal prohormone of brain natriuretic peptide; SCD, sudden cardiac death; TSH, thyroid-stimulating hormone; WBC, white blood cell.

^aSee Recommendation Table 12

5.1. Electrocardiogram

Dynamic changes in the ST segment are classic hallmarks of pericarditis and myocarditis. The most typical pattern includes widespread ST-segment elevation, reported in 20%–60% of cases (see [Supplementary data online, Table S4](#)). In pericarditis, ECG changes suggest concomitant myocardial involvement, and are indicative of

inflammation of the subepicardium.³⁵ These changes are more common in the initial phase and may be more frequent in younger patients. ST-segment depression and T-wave inversion may also be present, albeit less frequently than in patients with acute myocardial ischaemia,¹³² and may be related to the extent of myocardial damage.^{133,134} Diffuse depression of the PR segment is a classic early finding in AP.

A decrease in the amplitude of QRS complexes on ECG can be observed in cases of AP and/or AM, especially with large effusions or extensive myocardial injury. Electrical alternans of the QRS complexes has been reported, attributed to fluctuation of the heart within a large effusion (swinging heart). Lengthening of the QT interval might occur in AM.

Atrial fibrillation can occur in AP, especially in predisposed patients, in whom pericardial inflammation may be a trigger for supraventricular arrhythmias.⁷⁷ In contrast, VA are more common in myocarditis.

AVBs and intraventricular conduction defects, particularly right bundle branch blocks, are not uncommon (see [Section 4.3.3](#), and [Supplementary data online, Table S4](#)) and may be associated with more severe presentations.^{135–137}

Electrocardiogram changes are highly dynamic and may evolve over a span of hours or days, with temporal progression varying significantly among patients. Typically, ST changes resolve; however, it is important to note that a normal ECG at presentation does not exclude the possibility of IMPS.

5.2. Biomarkers

5.2.1. Biomarkers in clinical routine

Recommended biomarkers in IMPS include:

- **Markers of inflammation** (e.g. C-reactive protein): C-reactive protein is often increased in patients with pericarditis (up to 80%) and AM (up to 80%), and contributes to the diagnosis.^{28,36,138} Negative results, however, do not exclude the diagnosis. In pericarditis, C-reactive protein is a marker of disease activity that could be used to guide the duration of anti-inflammatory therapy.³⁶ D-dimers are currently being investigated for their diagnostic and prognostic relevance.^{36,139,140}
- **Markers of myocardial lesions** (e.g. troponin): Troponin is elevated in myocardial involvement, usually indicating cardiomyocyte necrosis. Assessment of baseline troponin is crucial to diagnose the severity of myocarditis. It is typically increased in infarct-like myocarditis.
- **Markers of HF** (BNP or NT-proBNP): Assessment of baseline level is recommended among patients with suspected myocarditis. This measurement can be repeated at discharge and during follow-up in an outpatient setting to assess the risk of clinical events. NT-proBNP can be used in patients with myocarditis as a predictive marker of HF among patients with normal or impaired LVEF.¹²

5.2.2. Biomarkers beyond clinical routine

Different biomarkers may help to identify a specific aetiology and to guide risk stratification. Most of them are not part of clinical routine,

but could help based on a strong clinical suspicion,⁷³ e.g. miR721 was shown to have a discriminatory capacity.¹⁴¹

In specific circumstances, tumour necrosis factor alpha (TNF- α), IL-1 β , IL-6, and IL-17A may be of value. Similarly, in some cases, evaluation of cardio-specific antibodies may be helpful, according to the local laboratory availability. These include organ-specific anti-heart autoantibodies and anti-intercalated disc autoantibodies, as well as non-organ-specific serum autoantibodies.¹⁰ These autoantibodies, especially if found at high titres, may have a negative prognostic value.^{73,142}

Furthermore, a specific serum biomarker, i.e. the soluble form of the IL-1 receptor-like 1 (IL-1RL1), also known as ST2, was associated with a higher risk of severe HF among male myocarditis patients.¹⁴³ Other biomarkers have been studied in myocarditis, including procollagen type III, gelsolin, soluble VCAM-1, galectin-3, serum alarmin S100A8/S100A9, immunoglobulin free light chain, and heparin-binding protein, for both diagnostic and prognostic purposes. However, these biomarkers were evaluated among limited small cohorts and are clinically not routinely used.^{144,145}

5.3. Genetics

Genetic testing is relatively new in the field of IMPS. There is a potential overlap with CMPs. Myocarditis and pericarditis will be discussed separately.

There has been increasing evidence that gene variants coding for structural proteins, particularly desmosomal and sarcomeric proteins, may overlap with acute and recurrent myocarditis and affect disease severity.^{94,95} Furthermore, it has been shown that there is an overlap of gene variants predisposing to myocardial inflammation and inherited CMP (ARVC and NDLVC).¹³ In particular, myocardial inflammation may be detected in patients with inherited CMP using serum and imaging biomarkers.¹³ There is evidence that these patients are at higher risk for complicated myocarditis (Section 4.3.5).^{13,91,93,94} In a meta-analysis, the pooled prevalence of P/LP variants was 4.2% for uncomplicated myocarditis, whereas for complicated myocarditis the pooled prevalence was 22% and 45% in adults and children, respectively.⁹⁵ Pathogenic/likely pathogenic variants in desmosomal genes were more common in uncomplicated myocarditis (64%), while variants in sarcomeric genes were more prevalent in complicated myocarditis (58% in adults and 71% in children).⁹⁵

A case series demonstrated a high proportion of definite or probable pathogenic variants in patients with myocarditis with RV involvement or sustained VA.¹⁴⁶ Furthermore, DSP variants have been reported in familial recurrent myocarditis.¹⁴⁷ Another study demonstrated overlap of gene variants in myocarditis and inherited CMP.⁹⁶

Identifying such gene variants has several clinical implications:

- (1) While in myocarditis there is a recommendation to defer on implantable cardioverter-defibrillator (ICD) placement during the acute phase of the disease, the threshold for ICD placement is lower in ARVC in cases of primary prevention.⁵⁸
- (2) Gene variants predisposing to myocarditis have relevant implications for patients.^{147,148} Details are given in the 2023 ESC Guidelines for the management of cardiomyopathies.¹³
- (3) Cascade clinical and genetic screening for relatives and familial genetic counselling should be offered.^{93,149}

As scientific knowledge about gene variants and their potential pathophysiological role has been continuously increasing over recent years, comprehensive screening includes desmosomal and sarcomeric genes and some DCM-associated genes.^{64,91,96,146,150} For details, see 2023 ESC Guidelines for the management of cardiomyopathies.¹³ Nevertheless, it is not clear whether the inflammatory process acts as a trigger or is fully part of the pathophysiological process in inherited CMP.¹⁵¹

Pathogenic/likely pathogenic variants have been identified in patients with recurrent pericarditis (RP), especially young patients, with a family history, multiple recurrences, inflammatory phenotype, and refractory or dependent on medical treatments. Recurrent pericarditis has been associated with genetic variants for monogenic autoinflammatory diseases (e.g. FMF, TRAPS), but also with genes related to the inflammatory response (Figure 14).^{50,51,152,153}

A recent study performed whole-exome sequencing in 108 patients with RP. Overall, about 15% of patients had variants in genes related to the inflammatory response, while up to 30% of patients carried variants in different cardiac genes, worthy of a deeper investigation.⁵¹ These data suggest a genetic predisposition in at least a subset of patients (positive family history of pericarditis or periodic fever, poor response to colchicine, multiple recurrences with inflammatory phenotype), and counselling may be offered.^{51,152} In these clinical scenarios, prolonged therapy with specific biological agents (e.g. anti-IL-1 agents) should be considered.

Recommendation Table 2 — Recommendations for genetic testing (see Evidence Table 2)

Recommendations	Class ^a	Level ^b
It is recommended to obtain family history including pedigrees in cases of recurrent IMPS to provide clues to the underlying aetiology, determine inheritance pattern, and identify relatives at risk.	I	C
Genetic testing should be considered in patients with definite myocarditis/pericarditis in cases of: ^{50,51,64,94,150} <ul style="list-style-type: none"> • family history of IMPS, inherited or suspected cardiomyopathy • severe ventricular arrhythmia^c • significant left/right LGE (e.g. ring-like pattern or septal LGE) or persistent LVEF systolic dysfunction • recurrent myocarditis or persistent troponin elevation • recurrent pericarditis with an inflammatory phenotype, refractory to conventional treatment^d, with the aim to detect an underlying genetic cause. 	IIa	B

IMPS, inflammatory myopericardial syndrome; IL, interleukin; LGE, late gadolinium enhancement; LVEF, left ventricular ejection fraction.

^aClass of recommendation.

^bLevel of evidence.

^cSee Section 4.

^dEspecially poor response to colchicine and anti-IL-1 agents.

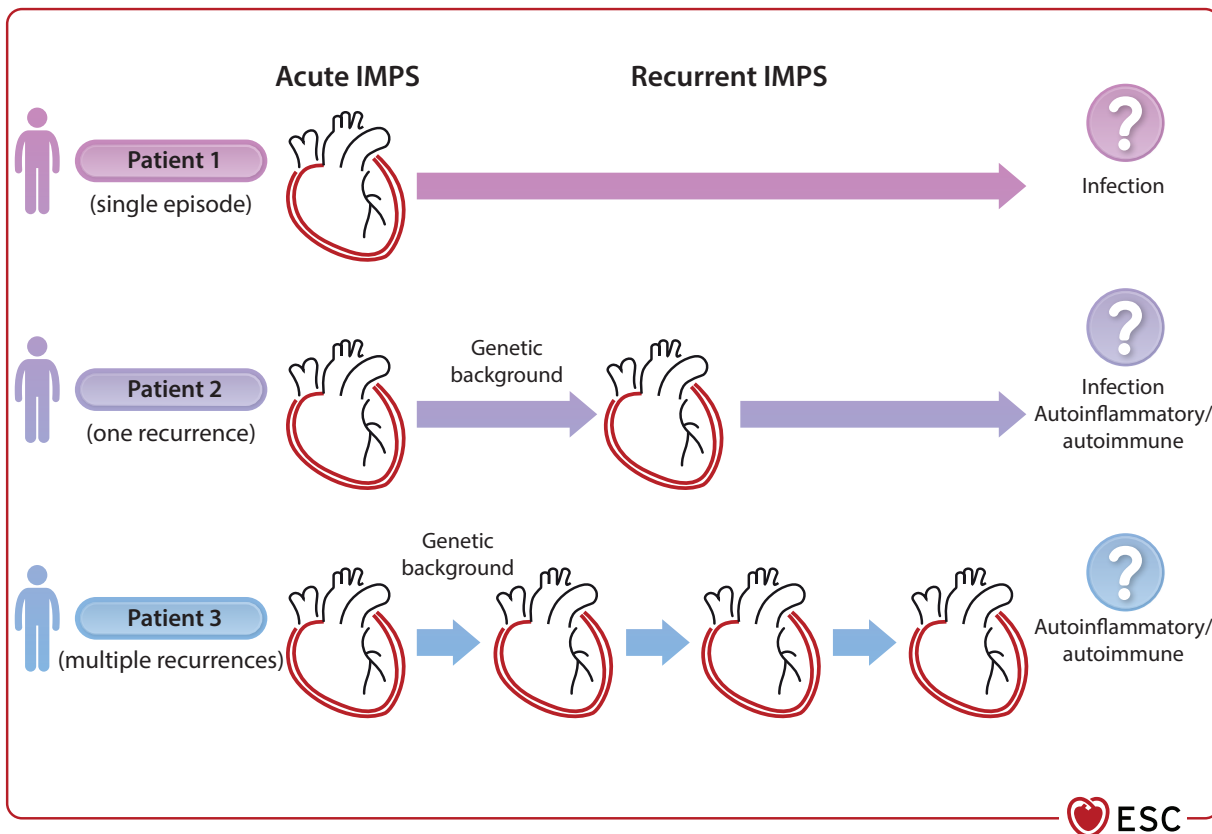


Figure 14 The different courses of inflammatory myopericardial syndrome and the interplay between genetic background inflammation and autoimmunity beyond the initial infectious trigger. IMPS, inflammatory myopericardial syndrome.

5.4. Multimodality imaging

The non-invasive diagnosis of IMPS relies on advanced cardiovascular imaging. An overview of the capabilities of different imaging modalities for the identification of pathophysiological components is provided in [Supplementary data online, Table S5](#). Echocardiography is usually the first-step imaging modality and provides functional and morphological information. Cardiovascular magnetic resonance can better differentiate myocardial tissue and shows myocardial and pericardial inflammation, as well as different patterns of fibrosis. Fluorodeoxyglucose positron emission tomography (FDG-PET) is useful to detect disease activity, especially for CS (see [Section 5.8](#)). Computed tomography allows detection of calcification of the pericardium and its extent, as well as exclusion of CAD. The application of non-invasive imaging should guide therapeutic decision-making (see [Section 4](#)).

5.5. Echocardiography

Transthoracic echocardiography (TTE) is usually the initial imaging modality of choice for individuals with suspected IMPS, given its ability to identify myocardial and pericardial abnormalities, as well as concomitant valvular disease.^{115,124}

5.5.1. Echocardiography in myocarditis

Patients with a suspicion of myocarditis should usually undergo standard TTE including speckle tracking or tissue Doppler imaging (TDI) at presentation. Transthoracic echocardiography helps monitor changes in cardiac chamber size, ventricular function, wall thickness, and PEff. In myocarditis, global ventricular dysfunction, diastolic dysfunction with preserved ejection fraction (EF), and regional WMA may occur.^{154,155}

Tissue Doppler imaging or strain imaging can be used in the setting of myocarditis and may indicate myocardial injury.^{156,157} Recent studies have shown that global longitudinal and circumferential strain (GLS and GCS) and strain rate were decreased in patients with AM, even with preserved EF.¹⁵⁶ Strain may provide important prognostic information in AM.¹⁵⁷ Regional GLS can be associated with scarring on CMR and can predict VA and outcomes in patients with AM.¹⁵⁷ Abnormal RV strain¹⁵⁸ and left atrial (LA) strain¹⁵⁹ have been detected in AM with preserved EF.

5.5.2. Echocardiography in pericarditis

Transthoracic echocardiography can detect the presence of PEff and assess its haemodynamic importance, as well as constrictive pathophysiology ([Supplementary data online, Figure S1](#) and [Table S6](#)).

Table 10 Classification of pericardial effusion

Onset	Acute (≤ 4 weeks)
	Subacute (> 4 weeks to ≤ 3 months)
	Chronic (> 3 months)
Size ^a	Mild: < 10 mm
	Moderate: 10–20 mm
	Large: > 20 mm
Distribution	Circumferential/loculated
Composition	Transudate/exudate

^aMaximal end-diastolic diameter.

Acute pericarditis patients may have a normal-appearing TTE (40%–50% of cases in first episodes); however, the presence of new or worsening PEff is a diagnostic criterion for pericarditis.^{24,115,160} The size of PEff is assessed by the end-diastolic distance of the echo-free space between the epicardium and parietal pericardium (Table 10).^{115,128} It is recommended that images should include the extent and location of each effusion measurement, as this allows follow-up studies. Transthoracic echocardiography enables the recognition of CTP and the presence of constriction.¹¹⁵

5.6. Cardiovascular magnetic resonance

Cardiovascular magnetic resonance is the accepted gold standard for the quantification of biventricular function and detection of WMA. Cardiovascular magnetic resonance has the advantage of tissue differentiation, non-invasively detecting myocardial and pericardial inflammation, as well as fibrosis.³⁰ The diagnostic targets in non-ischaemic myocardial inflammation include myocardial oedema, hyperaemia and capillary leak, and necrosis/fibrosis (see Supplementary data online, Figure S2).^{161–164} The diagnostic accuracy of CMR is higher if performed early in the time course of disease (best within the first 2 weeks). Myocardial oedema and changes due to inflammation lead to increased tissue water content that can be detected as increased signal intensities on T2-weighted imaging and/or T2 mapping; increased tissue free-water content will also lead to an increased signal in T1 mapping and extracellular volume (ECV) quantification. Myocyte necrosis and fibrosis can result in non-ischaemic (e.g. mid-wall, subepicardial, patchy) patterns of LGE, which do not typically follow a coronary artery distribution. The identification of myocarditis with chest pain presentation is less challenging than in HF and arrhythmic scenarios. The updated LLC, which include parametric mapping methods (T1/T2/ECV), should be applied for diagnosis, as the combined approach increases the diagnostic accuracy (see Figure 4).³⁰ It is important to note that imaging evidence of myocardial inflammation does not provide the underlying histotype (see Supplementary data online, Figure S2).

In the case of pericarditis, CMR detects thickening, oedema, and LGE of the pericardium.^{110,129,165} It is important to note that pericardial LGE may imply ongoing inflammation and neovascularization rather than simple scarring (see Supplementary data online, Figure S2). Cardiovascular magnetic resonance is helpful for an objective assessment of the degree of inflammatory involvement of the pericardium, either for first diagnoses or follow-up (for details see Figure 7 and Table 9).

Given its physical properties, CMR is affected by ferromagnetic objects, such as valvular prosthesis and implants, resulting in artefacts. The same holds true for active MR-conditional devices, such as pacemakers, ICDs, and cardiac resynchronization therapy (CRT) pacemakers/defibrillators (P/Ds), but dedicated techniques are now available to achieve better diagnostic image quality in many cases.¹⁶⁶ Cardiovascular magnetic resonance could also be used in patients with non-conditional devices with a clear clinical indication if other imaging modalities are not helpful. In all cases, programming of the implanted device before and after the scan is warranted, as well as patient monitoring.

Even in intubated patients, CMR scans are feasible in order to detect inflammation.¹⁶⁷ If breath-hold capacities are reduced or the patient is uncooperative, fast imaging techniques and/or motion-corrected imaging have to be applied.¹⁶⁸

Recommendation Table 3 — Recommendations for the use of cardiovascular magnetic resonance imaging (see Evidence Table 3)

Recommendations	Class ^a	Level ^b
Myocarditis		
CMR is recommended in patients with suspected myocarditis to reach a clinical diagnosis and to determine the cause of acute myocardial injury, including assessment of oedema, ischaemia, and necrosis/fibrosis/scarring. ^{115,164,169–183}	I	B
CMR is recommended for follow-up at least within the first 6 months in patients with myocarditis to identify a healed or ongoing process, for risk stratification and personalized therapy, and to enable a return to exercise. ^{10,62,184–186}	I	C
Pericarditis		
CMR is recommended in patients with suspected pericarditis when a diagnosis cannot be made using clinical criteria to assess evidence of pericardial thickening, oedema, LGE, and to assess the persistence of disease during follow-up in selected cases. ^{110,129,165,187–194}	I	B

CMR, cardiovascular magnetic resonance; LGE, late gadolinium enhancement.

^aClass of recommendation.

^bLevel of evidence.

5.7. Computed tomography

Computed tomography is an established tool for excluding CAD depending on the risk score and can be used in the diagnostic work-up according to current ESC guidelines.^{65,72,195}

Contrast-enhanced CT may be very useful to make an aetiological diagnosis in patients presenting with large PEff including tamponade.¹⁹⁶ Computed tomography is important before pericardiectomy for constriction to evaluate the anatomy and extent of calcifications as a higher burden of pericardial calcification has been associated with a better post-surgical outcome.¹⁹⁷ Furthermore, anatomical abnormalities, such as pectus excavatum, can be identified.¹⁹⁸ Meanwhile, CT in combination with FDG-PET plays a crucial role in the detection of CS (Section 9.4).

Recommendation Table 4 — Recommendations for computed tomography (see Evidence Table 4)

Recommendations	Class ^a	Level ^b
CT is recommended to evaluate pericardial thickness, calcifications, masses, and loculated pericardial effusions, as well as concomitant pleuropulmonary diseases and chest abnormalities. ^{193,197,199,200}	I	C

CT, computed tomography. Remaining recommendations for CT can be found in Recommendation Table 1.

^aClass of recommendation.

^bLevel of evidence.

5.8. Nuclear medicine

Fluorodeoxyglucose uptake reflects metabolically active inflammatory cells in AM.²⁰¹

Fluorodeoxyglucose positron emission tomography can be considered as an alternative in patients when CMR is unsuitable because of an irregular heartbeat or device-related artefacts.²⁰² Simultaneous/hybrid cardiac PET-CT/CMR imaging complement each other in the assessment of myocarditis compared with either approach alone.^{201,203} Fluorodeoxyglucose positron emission tomography is also a powerful tool to detect and assess the extent of extracardiac involvement in sarcoidosis (see Section 9.4).

Appropriate fasting before FDG-PET is a must to obtain reliable results.²⁰⁴ Typical preparation protocols include a high-fat and low-carbohydrate diet for 12–24 h followed by complete fasting other than water for the 6–12-h period prior to FDG injection.

The role of nuclear imaging in pericarditis is less well established. The use of FDG-PET/CT in pericarditis is generally complementary and is most often implemented in cases where CMR cannot be used.²⁰⁵

Recommendation Table 5 — Recommendations for nuclear medicine (see Evidence Table 5)

Recommendations	Class ^a	Level ^b
Carb-free ¹⁸ F-FDG-PET or ¹⁸ F-FDG-PET/CT should be considered for the diagnostic work-up in patients with suspected myocarditis and/or pericarditis in whom echocardiography and CMR are inconclusive for the clinical diagnosis. ^{201,206}	IIa	C

© ESC 2025

CMR, cardiovascular magnetic resonance; CT, computed tomography; ¹⁸F-FDG-PET, [¹⁸F]-fluorodeoxyglucose positron emission tomography.

^aClass of recommendation.

^bLevel of evidence.

5.9. Endomyocardial and pericardial biopsy

5.9.1. Endomyocardial biopsy

Endomyocardial biopsy enables the identification of the underlying histological subtype of cardiac inflammation.^{10,34,207,208} However, non-invasive imaging methods have significantly improved, allowing the diagnosis of myocarditis by CMR. Therefore, the role of EMB in clinical practice has changed. Endomyocardial biopsy remains important for high-risk patients and in some intermediate cases when the knowledge of the histological subtype and the identification of a possible viral aetiology are important for targeted therapies (Figure 15).^{207,209}

Endomyocardial biopsy has potential complications (e.g. cardiac perforation/tamponade, thromboembolism, valvular trauma, severe arrhythmias, and death).^{9,210} Rates depend on the setting and centre experience and range between 0.6% and 5%,^{63,211} and increase up to 26% in FM cases on mechanical circulatory support (MCS).²¹² Children may have higher complication rates depending on age, the experience of the centre, and the site of the biopsy (LV or RV).^{63,213} On this basis, the clinical use of EMB should be tailored according to the risk–benefit ratio.

Histological and immunohistological investigations, as well as viral genome analysis, allow the identification of viral or immune-mediated LM, EM, GCM, and sarcoidosis.^{33,214,215} Moreover, EMB allows the identification of the inflammatory stages in association with the degree of myocardial necrosis and fibrosis. Endomyocardial biopsy is useful in the differential diagnosis of infiltrative/storage diseases (amyloidosis, haemochromatosis,

glycogenosis), different CMPs, and genetic heart diseases^{33,216} if non-invasive imaging is inconclusive. This approach is consistent with other international position statements.^{9,210} Endomyocardial biopsy can be useful in cases of chronic CMP that is progressive or unresponsive to standard therapy. When FM, GCM or EM are suspected, early EMB is required to start immunosuppressive therapy rapidly and improve outcomes.⁵⁷ In GCM, EMB has high sensitivity (80%–93%) and a positive predictive value (71%), especially if performed within 2–4 weeks from symptom onset.²¹⁷ In CS, EMB may have a low sensitivity (20%–30%) due to the focal nature of inflammatory lesions, but can be improved by guiding the EMB using CMR or electro-anatomical mapping (EAM).^{218–222}

Historically, diagnosis by EMB was based on the histological Dallas criteria in HE-stained heart tissue sections revealing myocytolysis and interstitial immune cells.²²³ However, since there is high interobserver variability, immunohistochemical detection of lymphocytes (CD3) and macrophages (CD68) can definitely increase sensitivity for the diagnosis of myocarditis.^{10,224–226} A recent meta-analysis indicates that the use of immunohistochemistry can increase the detection rate of inflammation in EMB specimens to ~51%.²²⁷ A value of ≥ 14 leucocytes/mm² with T lymphocytes of ≥ 7 cells/mm² has been considered as the cut-off for the diagnosis of myocarditis.¹⁰ In acute LM, the number of T lymphocytes is generally higher (> 25 cells/mm²).²²⁸ Additionally, the expression of MHC class II molecules in antigen-presenting macrophages and endothelial cells is routinely observed in EMB with myocarditis.³³ Endomyocardial biopsy also enables the detection of viruses, such as enteroviruses, B19V,²²⁸ and herpesviruses, e.g. EBV and HHV-6, using quantitative real-time (RT)-PCR and *in situ* hybridization. It is likely that advances in molecular diagnostic techniques, such as next-generation sequencing, will help to identify potential new pathogens. Positive PCR results obtained on EMB have to be accompanied by a parallel investigation of blood samples collected at the time of the EMB to exclude acute systemic virus infection. In cases of acute cardiac and systemic virus infection, immunosuppressive therapy must be avoided.

The most common site of EMB is the RV septum, but occasionally LV or biventricular EMB may be needed. The decision of the EMB site should be based on the clinical indication, findings of pre-procedural imaging, and operator expertise.²²⁹ A study of 755 patients with suspected myocarditis and non-ischaemic CMP (including infiltrative and storage disorders) indicated that biventricular EMB can increase diagnostic accuracy compared with selective LV or RV EMB.²¹¹ Sampling error is the major limitation of the diagnostic accuracy of EMB. The minimal number of required EMB samples for each technique is reported in Table 11.³³

It should be emphasized that PCR in EMB tissue and *in situ* hybridization can be used for identification of the viral agent, because viral serology concurs with the results of PCR in a minority of patients (~4%) with myocarditis.²³⁰ With PCR, the rate of viral sequences detected in EMB specimens is up to 67%, although the rate varies widely among studies.^{63,228,231} The PCR tests for the detection of infectious agents must be performed in laboratories that are accredited and certified for the identification of viruses, bacteria, and parasites. The evaluation of these PCR results must be done in the context of histological/immunohistological findings by pathologists with expertise in cardiovascular diseases.

The timely communication of biopsy results is crucial for optimal therapeutic guidance.

Targeted biopsies of an inflamed heart diagnosed using histology, immunohistochemistry, and molecular virology could be correlated with modern technologies, such as genomics, epigenomics, proteomics, and metabolomics to improve the diagnosis and therapy. Recommendations for EMB can be found in Recommendation Table 1.

Recommendation Table 6 — Recommendations for endomyocardial biopsy (see Evidence Table 6)

Recommendations	Class ^a	Level ^b
EMB ^c is recommended in patients with high-risk myocarditis ^d , and/or haemodynamic instability, and/or in patients with intermediate-risk myocarditis not responding to conventional therapy in order to detect a specific histologic subtype and to assess the presence of viral genome for treatment. ^{34,63,73,131}	I	C

EMB, endomyocardial biopsy.

^aClass of recommendation.

^bLevel of evidence.

^cContemporary evaluation of EMB should be based on histology, immunohistology, and molecular pathology for detection of viral infections in myocardial and blood samples (see also Table 11).

^dSee Table 7.

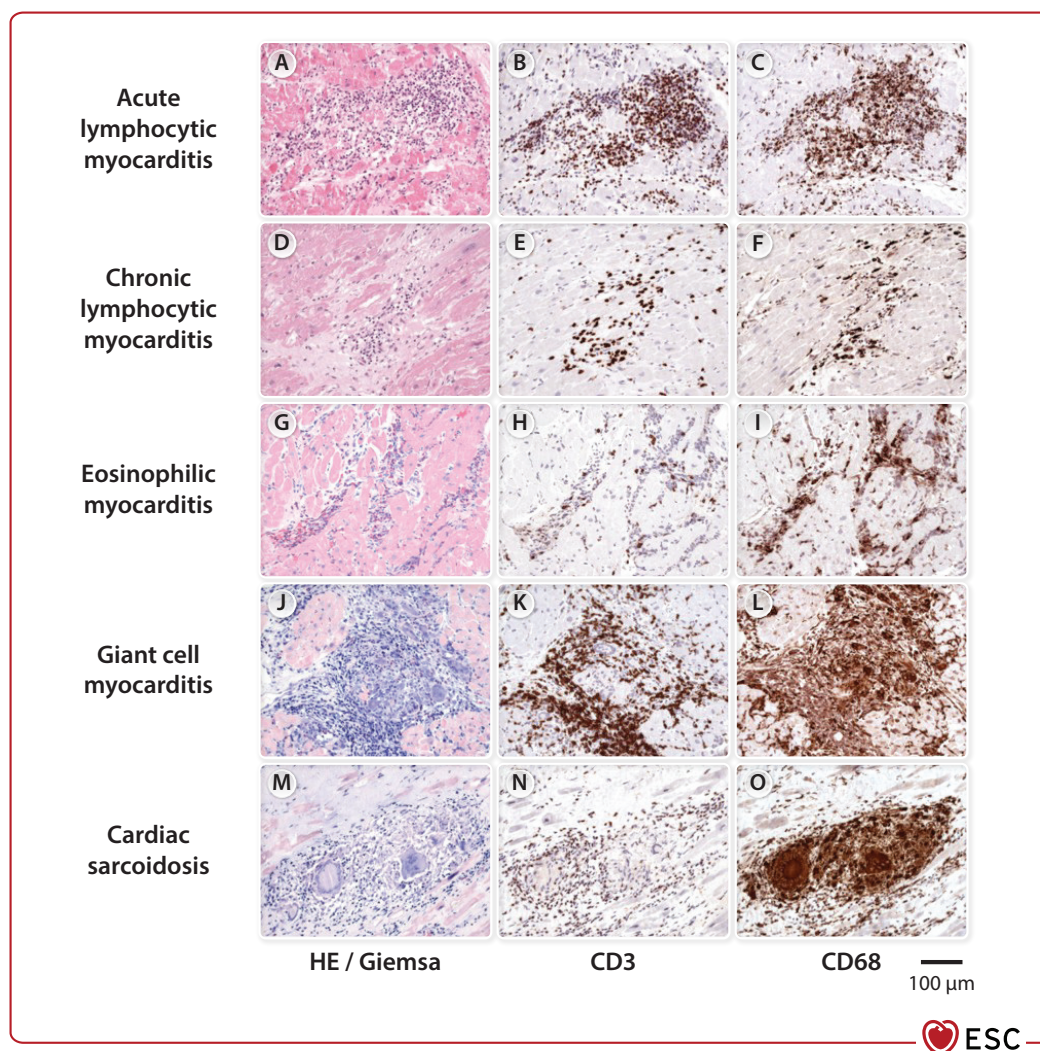


Figure 15 Histopathological findings in myocarditis. HE, haematoxylin eosin. (A–C) Endomyocardial biopsy for acute lymphocytic myocarditis reveals cardiomyocyte necrosis (A, HE stain) and severe focal infiltration of CD3⁺ T cells (B) and CD68⁺ macrophages (C), as detected by immunohistochemistry. (D–F) In chronic lymphocytic myocarditis, no cardiomyocyte injury is observed, but there is focal replacement fibrosis (D, HE) in the presence of CD3⁺ T cells (E) and CD68⁺ macrophages (F). (G–I) In acute eosinophilic myocarditis, necrosis of cardiomyocytes is associated with numerous eosinophilic granulocytes (G, Giemsa stain), some CD3⁺ T cells (H), and numerous CD68⁺ macrophages (I). (J–L) Areas with severe cardiomyocyte necrosis in the presence of extensive focal and diffuse infiltration of eosinophilic granulocytes (J, Giemsa stain), CD3⁺ T cells (K), and CD68⁺ macrophages and CD68⁺ giant cells (L) are typical of giant-cell myocarditis. (M–O) Cardiac sarcoidosis is histologically characterized by the presence of granulomas, usually in the absence of cardiomyocyte necrosis (M, Giemsa stain), but with focal infiltration of CD3⁺ T cells (N) and numerous CD68⁺ macrophages and CD68⁺ giant cells (O).

Table 11 Parameters for reporting by endomyocardial biopsy

Criteria	Parameters for reporting
Histology (paraffin-embedded EMB, at least 3 EMB)	Presence and extent of cardiomyocyte necrosis, inflammation, fibrosis
Immunohistology (paraffin-embedded EMB, at least 3 myocardial samples)	Presence, extent, localization, and typing of immune cells in the myocardium: CD3 ⁺ T lymphocytes, CD68 ⁺ macrophages (≥14 leucocytes/mm ² with T lymphocytes ≥7 cells/mm), ¹⁰ HLA-DR expression in immune cells and endothelial cells
Molecular pathology [infections: RNAlater, snap-frozen tissue (1–2 EMB), paraffin-embedded EMB]	Presence, typing, and quantification of DNA/RNA from infectious agents by q(RT)-PCR Viruses: mainly enteroviruses, parvovirus B19, human herpesvirus 6, Epstein–Barr virus; <i>Borrelia</i> spp., <i>Trypanosoma cruzi</i> ^a
Blood	q(RT)-PCR for detection of systemic infections
Molecular pathology (genetics: RNAlater, frozen tissue, paraffin-embedded EMB, blood)	NGS for detection of pathogenic variants in cardiac genes, traditionally associated with cardiomyopathies (especially desmosomal and sarcomeric/cytoskeletal genes)

© ESC 2025

DNA, deoxyribonucleic acid; EMB, endomyocardial biopsy; HLA-DR, human leucocyte antigen—DR isotype; NGS, next-generation sequencing; q(RT)-PCR, quantitative (real-time) polymerase chain reaction; RNA, ribonucleic acid.

^aSee Supplementary data online, Table S1.

5.9.2. Pericardial biopsy

In clinical practice, pericardial biopsy is rarely indicated in complicated cases not responding to conventional anti-inflammatory therapy and with a high suspicion of a specific aetiology (e.g. primary pericardial tumours and metastases), which cannot be determined by non-invasive diagnostic methods. Pericardial biopsy can be performed by pericardiocopy (an endoscopic study of the pericardium that is available in a limited number of tertiary referral centres). It is more commonly performed with a thoracoscopic or surgical approach, usually during a pericardial drainage or a pericardial window.^{1,232}

5.10. Role of autopsy

In autopsy studies of SCD, myocarditis has been described as a common finding, with incidences of myocarditis in children and adults ranging from 0.3% to 14.8%.^{87,88,233–235} In the majority of these studies, the incidence of myocarditis in SCD was higher in people aged under 35 years.^{236,237} A nationwide unselected cohort of 14 294 deaths in Denmark suggested that 6% of all autopsied SCD was caused by myocarditis. Males have a significantly higher incidence.⁸⁸ In the UK, between 1994 and 2022, myocarditis was reported as a rare cause of SCD in non-hospitalized individuals (1.1%) in 7702 consecutive cases

of SCD. Here, the most common reported form was LM (56%), which corresponds well with data obtained from EMBs of patients with suspected myocarditis.^{10,63,87,238}

In the guidelines for the histopathological diagnosis of myocarditis, ‘fulminant’ or ‘multifocal’ myocarditis can be generally considered as a reliable or acceptable cause of death, especially when inflammation is the only substantial histopathological finding. This approach is endorsed by the Association of European Cardiovascular Pathology.²³⁹

In addition to LM, other types of cardiac inflammation are observed in autopsies. In 558 of 49 612 (1.1%) forensic autopsies, myocarditis was detected by histology. In a Finnish study consisting of 351 patients with CS, 14% experienced fatal and aborted SCD as a presenting manifestation. In 64%, undiagnosed granulomas in the heart were the cause of fatalities.²⁴⁰ The likelihood that a case of unexplained SCD is caused by an underlying inherited disorder has led to the emerging role of genetic testing of DNA obtained at autopsy (also called molecular autopsy or post-mortem genetic testing).²³⁹ Therefore, pathologists play an important role in the identification of families at risk by reporting whether it is recommended to refer first-degree family members for clinical screening and/or to perform additional post-mortem genetic testing to identify the underlying cause of cardiac inflammation.^{241,242} Legal and ethical issues related to genetic testing in deceased subjects who did not give their consent are not universally regulated by law.

Recommendation Table 7 — Recommendations for autopsy (see Evidence Table 7)

Recommendations	Class ^a	Level ^b
Comprehensive autopsy is recommended in all patients <50 years of age with SCD to evaluate the presence of acute myocarditis as a cause and to detect potential underlying inherited cardiac diseases. ^{87,243–246c}	I	B
Retaining samples suitable for DNA extraction and consulting a cardiac pathologist is recommended in cases of SCD, when an inherited cause is suspected, or the cause of death remains unexplained. ^{243,247c}	I	B

© ESC 2025

DNA, deoxyribonucleic acid; SCD, sudden cardiac death.

^aClass of recommendation.

^bLevel of evidence.

^cIn line with the 2022 ESC Guidelines for the management of patients with ventricular arrhythmias and the prevention of sudden cardiac death.⁵⁸

5.11. Role of cardiac catheterization and coronary angiography

Given the overlap of symptoms (especially chest pain), as well as the elevation of biomarkers (such as troponin in the case of myocardial involvement and NT-proBNP) and ECG changes, ACS is the main differential diagnosis for IMPS. Depending on the initial clinical assessment, ACS should be ruled out according to current guidelines (Figure 9). The recommended methods are coronary CT or invasive coronary angiography depending on likelihood of obstructive CAD.^{72,248} Coronary angiography is preferable in patients with a high likelihood of ACS. It should be noted that CAD may coexist with myocarditis in particular scenarios, including EM and ICI-induced myocarditis.^{249–251}

Cardiac catheterization is also indicated to monitor and guide HF therapy, as well as the early need for more advanced support (HT or MCS) in the case of refractory haemodynamic deterioration.¹²

For pericarditis, specific indications for cardiac catheterization include the differential diagnosis between restrictive CMP (RCM) or CP.²⁵² when this differentiation cannot be done by multimodality imaging (see [Supplementary data online, Section 2.6](#)).

5.12. Electro-anatomical mapping

The diagnostic yield of traditional fluoroscopy-guided EMB in patients with suspected myocarditis may decrease with segmental or patchy myocardial involvement, as seen in CS. Electro-anatomical mapping, using bipolar and unipolar voltage mapping, allows the identification of low-voltage areas, which reflects abnormal myocardial tissue (scarring, inflammation), and therefore guides EMB.^{218–222} Unipolar EAM-guided EMB demonstrated a higher diagnostic yield than bipolar EAM (83% compared with 63%), consistent with the epicardial substrate.^{84,218,221}

A meta-analysis of 148 patients showed a higher diagnostic performance of EAM-guided EMB in CS compared with other forms of myocarditis. The sensitivity of any abnormal electrogram for a positive EMB was high (92%) but was associated with moderate specificity (58%).²²¹

Electro-anatomical mapping has demonstrated good sensitivity and specificity compared with CMR for the detection of pathological areas of the myocardium.²¹⁸ The value of EAM to guide biopsy may be lower in AM as low-voltage areas correlate well with LGE, but not with oedema.²⁵³ There may also be discordance between low-voltage areas and LGE on CMR. However, the combination of unipolar/bipolar EAM with CMR findings increased the diagnosis yield of EMB,²¹⁸ especially in CS.²²⁰ The EAM pattern may also help to differentiate between differential diagnoses, especially between CS and ARVC,²⁵⁴ as CS often involves the basal septum and exhibits a higher bipolar/unipolar low-voltage area ratio. The reported complication rate of EAM-guided EMB is <5%.^{218,221}

Programmed ventricular stimulation (PVS) has not been evaluated in the acute setting and should not be performed in the acute phase. It could be useful for arrhythmia stratification in selected patients with non-active myocarditis, with LGE and risk factors for ventricular arrhythmias ([Section 6.5](#)).²⁵⁵

Recommendation Table 8 — Recommendations for electro-anatomical mapping (see [Evidence Table 8](#))

Recommendations	Class ^a	Level ^b
Electro-anatomical mapping should be considered in cases of suspected myocarditis (especially cardiac sarcoidosis) to guide endomyocardial biopsy. ^{218,220,221,253,256–258}	IIa	C

© ESC 2025

^aClass of recommendation.

^bLevel of evidence.

6. Therapy

The aim of medical therapy for IMPS is to relieve symptoms and to prevent complications, especially recurrences and mortality in complicated cases. Medical therapy targets include: (i) infectious agents; (ii) inflammation; (iii) immune-mediated processes; (iv) HF and ventricular dysfunction (in cases of myocarditis); (v) arrhythmias; and (vi)

constriction (in cases of pericarditis). Treatments are individualized according to the specific case and the presumed or diagnosed pathogenesis, and specific therapeutic concepts will be discussed in the section covering specific causes. There may be differences depending on whether an isolated or a combined form is present. The current evidence is more focused on the isolated cases. For combined conditions, the leading one (myopericarditis or perimyocarditis) should guide the therapeutic decision-making and subsequent follow-up.

6.1. Non-pharmacological therapy for inflammatory myopericardial syndrome

An important non-pharmacological concept is the restriction of physical activity beyond sedentary activities until symptom resolution and clinical remission with normalization of inflammatory markers. This temporary limitation of physical activities should be individualized according to each patient, and the response to therapy until clinical remission. According to clinical presentation, at least 1 month is needed to reach clinical remission, but it can last longer. Depending on the stage and risk of the IMPS, physical activity should be tailored, and temporary restriction of physical activity is necessary in the acute phase of the disease (see [Section 7](#)). Previous consensus statements and guidelines¹¹ have tried to provide a fixed time interval. This TF suggests personalizing the treatment until clinical remission based on a multiparametric assessment, which was also supported by the 2024 ACC expert consensus paper.⁹ Clinical remission is defined as full regression of symptoms, as well as normalization of laboratory results (e.g. C-reactive protein, troponin levels) and investigations (ECG, evidence of PEff, CMR evidence of active inflammation) ([Table 3](#)). Additional testing (e.g. exercise testing and Holter monitoring) is recommended for patients with myocarditis for the detection of clinical remission. After a prolonged rest period, a gradual, monitored return to work and physical activity may be helpful, if necessary, guided by a qualified rehabilitation. Currently, evidence-based data are missing on this topic, and the decision must be individualized.

6.2. Pharmacological therapy

6.2.1. Pharmacological therapy for myocarditis

6.2.1.1. General principles

This section will focus on general aspects and non-aetiology-directed therapy. It should be recognized that evidence is very limited in this field and this document will provide guidance for clinical practice.

Medical therapy of myocarditis is based on clinical presentation, case severity, and aetiology. It includes general supportive, non-aetiology-directed therapy (e.g. HF therapy),^{12,259} anti-arrhythmic therapy, and specific therapy (aetiology-directed therapy).^{58,260,261} Corticosteroids are considered for autoimmunity-associated cases to suppress the immune system, as first-line therapy in most cases. Severe cases are considered for MCS and HT.

Uncomplicated cases of myocarditis usually present with chest pain and can be empirically treated with aspirin or non-steroidal anti-inflammatory drugs (NSAIDs) for the control of chest pain, if needed. This is supported by a small study showing no harm for patients treated with anti-inflammatory drugs.²⁶² Concomitant use of colchicine is safe in patients with myopericarditis, preventing recurrences.²⁶³ In clinical practice, β -blockers are often used in patients with myocarditis. In a small study, β -blockers were associated with better outcomes, defined as freedom from cardiac death or HT.²⁶⁴

Several viruses can cause myocarditis and are mentioned in Section 3.4. The specific therapies for viral aetiologies can be found in Section 9.5 for influenza-, severe acute respiratory syndrome coronavirus 2 (SARS-CoV-2)-, and HIV-associated myocarditis. For specific

aetiologies, refer to the subsections on LM (Section 9.1), EM (Section 9.2), GCM (Section 9.3), CS (Section 9.4), LC (Section 9.5.2), CD (Section 9.5.3), and ICI-associated myocarditis (Section 9.6.1.1). Specific medical therapies are summarized in Table 12.

Table 12 Therapy for specific forms of myocarditis

Lymphocytic myocarditis (virus-negative)	
1st line therapy	<u>Non-severe:</u> prednisone 1 mg/kg/day p.o. then tapered <u>Severe:</u> i.v. methylprednisolone 7–14 mg/kg/day for 3 days, then 1 mg/kg/day p.o.
2nd line therapy	Oral corticosteroids + azathioprine ^a or mycophenolate mofetil ^b , cyclosporine ^c , methotrexate ^d
3rd line therapy	IVIg ^e or plasmapheresis ^f
Eosinophilic myocarditis	
1st line therapy	Same as lymphocytic myocarditis + Treat EM-associated condition if identified
2nd line therapy	Same as lymphocytic myocarditis + Treat EM-associated condition if identified
3rd line therapy	–
Giant-cell myocarditis	
1st line therapy	<u>Non-severe:</u> prednisone 1 mg/kg/day p.o. then tapered <u>Severe:</u> i.v. methylprednisolone 7–14 mg/kg/day for 3 days, then 1 mg/kg/day p.o. + immunosuppressive (azathioprine ^a or mycophenolate mofetil ^b , cyclosporine ^c)
2nd line therapy	Antithymocyte Globulin (ATG) ^g cyclophosphamide ^h , rituximab ⁱ
3rd line therapy	–
Cardiac sarcoidosis	
1st line therapy	<u>Non-severe:</u> prednisone 1 mg/kg/day p.o., tapering from 40–60 mg daily <u>Severe:</u> i.v. methylprednisolone 7–14 mg/kg/day for 3 days, then 1 mg/kg/day p.o.
2nd line therapy	Methotrexate ^d (1st choice), or azathioprine ^a mycophenolate mofetil ^b , cyclophosphamide ^h
3rd line therapy	Infliximab ^j or adalimumab ^k , rituximab ⁱ
Lyme carditis	
1st line therapy	(a) Oral antibiotics (mild cases): – Doxycycline 100 mg b.i.d. (14–21 days) – Amoxicillin 500 mg t.i.d. (14–21 days) – Cefuroxime axetil 500 mg b.i.d. (14–21 days) (b) i.v. antibiotics (severe cases): – Ceftriaxone 2 g/day (14–21 days)
2nd line therapy	i.v. antibiotics: Cefotaxime (2 g q8h × 14–21 days) or Penicillin G (18–24 MU/day i.v. q4h × 14–21 day)
3rd line therapy	–
Chagas disease	
1st line therapy	Benznidazole 5–7 mg/kg/day in 2 doses for 60 days Nifurtimox 8–10 mg/kg/day in 3 doses for 60–90 days
2nd line therapy	–
3rd line therapy	–

Continued

ICI-induced myocarditis	
1st line therapy	Withdraw ICI, reassess Non-severe: methylprednisolone 500–1000 mg/day × 3 days, then taper with oral prednisone Severe: i.v. methylprednisolone 7–14 mg/kg/day × 3 days, then 1 mg/kg/day
2nd line therapy	If no response in 24–48 h: mycophenolate mofetil ^b , ATG ^g , abatacept ^l , alemtuzumab ^m
3rd line therapy	Infliximab ^j or adalimumab ^k , rituximab ⁱ

ATG, anti-thymocyte globulins; b.i.d., twice daily; CTLA-4, cytotoxic T-lymphocyte antigen 4; EM, eosinophilic myocarditis; ICI, immune checkpoint inhibitor; IgG, immunoglobulin; IL, interleukin; i.v., intravenous; IVIG, intravenous immunoglobulins; p.o., by mouth; s.c., subcutaneous; t.i.d., three times daily; TNF- α , tumour necrosis factor alpha.

^aAzathioprine (immunosuppressant purine analog): 1–2 mg/kg per day p.o. (typically 100–150 mg daily, in 1–2 divided doses, main target: lymphocytes).

^bMycophenolate mofetil (immunosuppressant that inhibits inosine monophosphate dehydrogenase, main target: lymphocytes): 500–1000 mg p.o. b.i.d. (total 1–2 g/day).

^cCyclosporine (calcineurin inhibitor that prevents IL-2 transcription in activated T-cells): ~3–5 mg/kg/day p.o. (divided b.i.d.) adjusted to target trough levels ~150–250 ng/mL.

^dMethotrexate (antimetabolite that inhibits dihydrofolate reductase and other folate-dependent steps, reducing proliferation of active lymphocytes): 15–20 mg/week p.o. or s.c. (low-dose weekly, with folic acid supplementation).

^eIVIG (immunomodulatory therapy providing pooled IgG antibodies) = standard dose off-label 2 g/kg total dose, typically administered over 1 to 2 days; alternative dosing: 0.4 g/kg/day for 5 consecutive days (less commonly used in myocarditis but sometimes used in autoimmune settings).

^fPlasmapheresis (therapeutic plasma exchange that filters out and removes circulating autoantibodies, immune complexes, and inflammatory mediators) 3–5 sessions in 5–10 days.

^gAntithymocyte Globulin (ATG; polyclonal anti-T-lymphocyte antibody that causes profound T-cell depletion): ~1 mg/kg i.v., often given daily for 3–5 days.

^hCyclophosphamide (cytotoxic alkylating agent that crosslinks DNA in rapidly dividing cells, main target: lymphocytes): 600 mg/m² i.v. bolus on days 1, 15, and 30 (pulse therapy).

ⁱRituximab (monoclonal antibody against CD20 on B cells): 375 mg/m² i.v. weekly × 4 doses (1 month).

^jInfliximab (monoclonal antibody against TNF- α): 5 mg/kg i.v. at weeks 0, 2, 6, then every ~8 weeks (maintenance).

^kAdalimumab (anti-TNF- α fully human monoclonal antibody) 40 mg SC every week (or every 2 weeks, per clinical response).

^lAbatacept (CTLA-4 Ig fusion protein that binds CD80/86 on antigen-presenting cells, blocking the CD28 co-stimulatory signal required for full T-cell activation): 500 mg i.v. every 2 weeks × 5 doses (approximately 10 weeks).

^mAlemtuzumab (monoclonal antibody against CD52 on lymphocytes): 30 mg i.v. once (alternative: 15 mg i.v. daily for 2 days).

Main mechanisms of action:

- T-cell suppression (e.g., corticosteroids, cyclosporine, abatacept)
- B-cell depletion (rituximab)
- Cytokine inhibition (TNF- α blockers like infliximab, adalimumab)
- DNA synthesis inhibition (azathioprine, mycophenolate, methotrexate)
- Immunoglobulin replacement/modulation (IVIG)
- Plasma filtration (plasmapheresis)

6.2.1.2. Fulminant myocarditis

Fulminant myocarditis is a rare and severe presentation of myocarditis and a cause of cardiogenic shock, and should be treated accordingly with inotropic or vasopressor support or, if needed, MCS (see Section 6.3).²⁶⁵ It is crucial to be aware of the condition and, when needed, to refer patients to tertiary referral centres that can institute temporary MCS and perform early EMB. Early EMB has been independently associated with a lower rate of death or HT/left ventricular assist device (LVAD) at 1 year.⁵⁷ The timely communication of biopsy results is crucial. Specific subtypes of FM (e.g. biopsy-proven non-infectious forms) may respond to immunosuppressive therapy in addition to guideline-directed medical care.^{12,34} An ongoing trial is evaluating corticosteroids for FM (ClinicalTrials.gov Identifier: NCT05150704).

6.2.1.3. Acute myocarditis

Acute myocarditis has a high rate of spontaneous recovery, especially in uncomplicated cases. In cases of AM diagnosed by EMB, up to 50% of patients have spontaneous recovery and up to 25% may have a persistent stable cardiac dysfunction. Only 10%–25% have a progressive ventricular dysfunction, which could lead to end-stage DCM, HT, or death.⁹ Treatment of AM depends on severity and clinical presentation. Risk stratification of these patients is mandatory to assess the required level of care.

The acute phase of viral myocarditis (e.g. induced by cytolytic enteroviruses) is characterized by intense virus replication and myocyte necrosis and usually lasts for only a few days.²⁶⁶ Thus, early antiviral therapy directed against an identified virus is a potential therapeutic

avenue to stop the development of viral myocarditis. The evidence on clinical application of antiviral agents is limited, and antiviral treatments should be agreed upon with an infectious disease expert as part of the IMPS team.

Patients with AM show significant activation of the NLR family pyrin domain containing 3 (NLRP3) inflammasome in the heart, thus it is a potential therapeutic target in the acute phase of myocarditis.²⁶⁷ Activation of NLRP3 functions as a rapid inducer of an inflammatory response through the production of IL-1 β and IL-18. Theoretically, promising agents are anti-IL-1 agents (anakinra, rilonacept, canakinumab) and colchicine,²⁶⁷ although human data on the effect of such agents in myocarditis are still limited.

In humans, the first evidence has been reported using anakinra, an IL-1 receptor antagonist (IL-1RA) that improved heart function in selected cases of AM refractory to standard treatment. However, in the ARAMIS trial, anakinra failed to demonstrate a benefit in patients with suspected AM without a specific aetiology (NCT03018834).²⁶⁸ The primary endpoint was the number of days alive free from any complication due to AM. The study had potential limitations related to the limited sample size, the inclusion of a low-risk population, and the short follow-up, but it proved that anakinra was safe in this setting.

Regarding modulation of the immune response, further randomized studies are needed to assess treatment with intravenous immunoglobulins (IVIG) in AM for adults,²⁶⁹ since case series and retrospective analyses suggest a benefit in terms of transplant-free survival. Intravenous immunoglobulins are commonly prescribed in paediatric patients.²⁶⁹ In general, treatment of AM with corticosteroids is controversial, with the exception of ICI-induced myocarditis²⁷⁰ and EM.²⁷¹

The efficacy of combined immunosuppression (prednisone with either cyclosporine or azathioprine), compared with placebo, was assessed in a single randomized controlled trial (RCT) in patients with biopsy-proven AM of unspecified aetiology, since infectious causes were not excluded by PCR.²⁷² The trial was designed to determine whether immunosuppressive therapy improved LV function in patients with AM. There was no significant difference in survival between the two groups ($P = 0.96$). The study had several limitations, such as small sample size and incomplete analysis of EMB based only on histopathology. However, in specific histopathological forms of AM, such as GCM, immunosuppressive drugs are recommended (see Sections 9.2 and 9.3).

6.2.1.4. Subacute and chronic myocarditis

Chronic myocarditis may represent an intermediate stage between subacute myocarditis and inflammatory CMP. During chronic myocarditis, HF may develop, and guideline-directed medical therapy (GDMT) for HF is the cornerstone in the treatment of chronic myocarditis.^{12,259} Antiviral therapy has little benefit in the subacute and chronic stages of myocarditis,²⁷³ and the effects of immunomodulatory drugs on chronic myocarditis of unspecified aetiology are still controversial.

Recommendation Table 9 — Recommendations for medical therapy in myocarditis (see Evidence Table 9)

Recommendations	Class ^a	Level ^b
Management of symptoms		
NSAIDs (together with proton pump inhibition) should be considered in patients with associated symptoms of pericarditis to reduce symptoms.	IIa	C
Colchicine should be considered in patients with myopericarditis to reduce recurrences. ²⁶³	IIa	B
Management of heart failure		
Adherence to the ESC HF guidelines is recommended in cases of myocarditis with LV systolic dysfunction and/or HF to reduce symptoms and to improve LV function. ¹²	I	C
HF therapy should be considered in patients with myocarditis and LV systolic dysfunction for at least 6 months upon complete LV functional recovery to stabilize LV function.	IIa	C
Management of arrhythmias		
β-Blockers, with a continuation for at least 6 months, should be considered in patients with acute myocarditis, especially those with troponin elevation, to control symptoms and prevent arrhythmias.	IIa	C
Anti-arrhythmic treatment should be considered in post-myocarditis patients with recurrent, symptomatic VT to reduce arrhythmic burden. ⁵⁸	IIa	C
Immunosuppressive therapy		
Corticosteroids should be considered in patients with fulminant, non-infectious forms of myocarditis to stabilize the patients.	IIa	C

Continued

Corticosteroids may be considered in patients with acute myocarditis with impaired LVEF if refractory to standard HF therapy to stabilize patients.	IIb	C
Routine use of immunosuppressive therapy is not recommended in acute myocarditis with preserved LV function because no outcome benefit has been shown.	III	C

© ESC 2025

ESC, European Society of Cardiology; HF, heart failure; LV, left ventricle; LVEF, left ventricular ejection fraction; NSAID, non-steroidal anti-inflammatory drug; VT, ventricular tachycardia.

^aClass of recommendation.

^bLevel of evidence.

6.2.2. Pharmacological therapy for pericarditis

6.2.2.1. General principles

The aims of medical therapy for pericarditis are to provide: (i) symptomatic care (mainly control of pericarditis chest pain); (ii) clinical remission; and (iii) prevention of complications, especially recurrences and constriction.

Exercise restriction limits the heart rate and may be useful to reduce pericardial friction, which can be improved using drugs that reduce it (e.g. β-blockers or ivabradine for those who cannot receive or tolerate β-blockers) for patients with a resting heart rate of >75 b.p.m., and symptoms despite empirical anti-inflammatory therapy.²⁷⁴

6.2.2.1.1. Acute pericarditis (first episode). The mainstay of medical therapy is empirical anti-inflammatory therapy using aspirin or NSAIDs at full anti-inflammatory doses with appropriate time intervals of administration (usually every 8 h) plus colchicine to reduce the risk of recurrences.^{24,25,108,275–278} Gastroprotection with a proton pump inhibitor is recommended using NSAIDs.²⁷⁹

When aspirin and NSAIDs are contraindicated, or for specific indications, corticosteroids should be considered at low to moderate doses plus colchicine (see Tables 13 and 14).

In cases of incomplete response to aspirin/NSAIDs and colchicine, corticosteroids may be added at low to moderate doses as triple therapy.¹ In cases of recurrence, every effort should be made not to increase the dose or to reinstate corticosteroids.

The use of colchicine on top of empirical anti-inflammatory therapy is supported by most of the published evidence, with the single exception of a small open-label trial that was probably underpowered to test the study hypothesis for patients with AP.²⁸¹ Specific dosing and duration of therapy are summarized in Table 13. Monitoring of serum C-reactive protein and CMR imaging is recommended to assess clinical remission, guide the treatment length, and evaluate the response to therapy in more complicated and difficult-to-treat cases. In uncomplicated cases, clinical follow-up with/without echocardiography is sufficient.

6.2.2.2. Incessant and recurrent pericarditis

In patients with incessant pericarditis or RP, the mainstay of therapy is always colchicine in association with aspirin/NSAID or low to moderate doses of corticosteroids. For more difficult cases, chest pain can be controlled by a combination of aspirin or an NSAID plus corticosteroids at low to moderate doses and colchicine (triple therapy). The i.v. route should be considered to ensure a clinical response or to control symptoms in more difficult or resistant cases.

Table 13 Specific initial dosing and duration of therapy for acute and recurrent pericarditis

Therapy	Dosing	Duration ^a	Tapering ^a
Aspirin ^b	750–1000 mg 3 times daily	1–2 weeks	Decrease by 250 mg every 1–2 weeks
Ibuprofen ^b	600–800 mg 3 times daily	1–2 weeks	Decrease by 200 mg every 1–2 weeks
Indomethacin	25–50 mg 3 times daily	1–2 weeks	Decrease by 25 mg every 1–2 weeks
Colchicine ^b	0.5 mg once daily (<70 kg or severe renal impairment) or 0.5 mg twice daily	3–6 months	Not required
Prednisone	0.2–0.5 mg/kg/day	2–4 weeks	Several months
Treatment for recurrences only:			
Azathioprine	Starting with 1 mg/kg/day then gradually increased to 2–3 mg/kg/day	Several months	Several months
IVIg	400–500 mg/kg i.v. daily for 5 days	5 days	Not required
Anakinra	1–2 mg/kg/day up to 100 mg/day in adults	At least 6 months/ >12 months	Needed (at least 3–6 months)/ unknown
Rilonacept ^c	320 mg once daily followed by 160 mg weekly		

IVIg, intravenous immunoglobulins; NSAID, non-steroidal anti-inflammatory drug.

Treatment for recurrences only is highlighted in grey.

^aTherapy duration as initial dosing; for all treatments the attack dose is maintained until symptom resolution and normalization of inflammatory markers (e.g. C-reactive protein) and other investigations (electrocardiogram, echocardiogram) then tapering is recommended. It should be tailored to the single patient according to disease severity and patient response. Tapering is especially important for corticosteroids where tapering is particularly slow, especially below 15 mg/day, the common threshold for recurrences (see Table 14). Monitoring is essentially based on the assessment of blood count, creatinine, creatine kinase, transaminases, C-reactive protein, echocardiography. Anakinra should be tapered after clinical remission. Different schemes are adopted: e.g. reducing one dose per week every month; every other day full dose for at least 3 months then half-dose every other day for at least 3 months.

^bAspirin and ibuprofen are common first-level treatments for the first episode of pericarditis (acute pericarditis) associated with colchicine for at least 3 months. Aspirin is the preferred choice for patients with ischaemic heart disease. Indomethacin is usually considered for incessant/recurrent cases. In incessant/recurrent cases, colchicine is maintained for at least 6 months. Aspirin/NSAID full dose is recommended for patients with normal or mildly reduced renal function. For those with moderate to severe renal impairment, dose adjustment or use of corticosteroids is recommended.

^cRilonacept is registered in the USA but is not currently available in Europe. Anakinra, due to its short half-life, may be the preferable choice in patients at increased risk of infections.

Table 14 Tapering of corticosteroids

Prednisone dose ^a	Starting dose 0.20–0.50 mg/kg/day ^a	Tapering ^b
Prednisone daily dose	>50 mg	10 mg/day every 1–2 weeks
	50–25 mg	5–10 mg/day every 1–2 weeks
	25–15 mg	2.5 mg/day every 2–4 weeks
	<15 mg	1.25–2.5 mg/day every 2–6 weeks

^aAvoid higher doses except for special cases, and only for a few days, with rapid tapering to 25 mg/day. Prednisone 25 mg is equivalent to methylprednisolone 20 mg.

^bEvery decrease in prednisone dose should be done only if the patient is asymptomatic and C-reactive protein is normal, particularly for doses of <25 mg/day.

Calcium intake (supplement plus oral intake) of 1200–1500 mg/day and vitamin D supplementation of 800–1000 IU/day should be offered to all patients receiving glucocorticoids. Moreover, bisphosphonates are recommended to prevent bone loss in all men aged ≥50 years and postmenopausal women in whom long-term treatment with glucocorticoids is initiated at a dose of ≥5.0–7.5 mg/day of prednisone or equivalent.²⁸⁰

Patients who develop a recurrence during corticosteroid tapering should continue colchicine and receive an NSAID on top of this treatment instead of increasing the dose of corticosteroids. Which medication should be tapered first (corticosteroids or NSAID) depends on the specific clinical scenario (age, kidney function, haemorrhagic risk, and use of oral anticoagulants).

For patients with corticosteroid dependence, colchicine resistance, and evidence of elevated C-reactive protein (baseline or subsequent episode), clinical trials and an international registry supported the use of an anti-IL-1 agent (anakinra or rilonacept).^{108,275,282–284} An

advantage of these agents is the rapid onset of action and the possibility of rapid withdrawal of corticosteroids.²⁸⁵ There is evidence of efficacy with anti-IL-1 agent (anakinra or rilonacept) monotherapy.^{108,275,282–284}

However, concomitant use of colchicine could be helpful to reduce recurrences and prolong recurrence-free survival, providing a sequential block of the pro-inflammatory pathway leading to the generation of IL-1.²⁸⁶ Colchicine should be maintained and withdrawn as the last drug only after stable remission. Moreover, colchicine has the safest cardiovascular profile and is now proposed to prevent major adverse cardiac events (MACE) in patients with atherosclerotic cardiovascular diseases.²⁴⁸ In patients obtaining stable remission with a chronic low dose of corticosteroids (e.g. prednisone ≤5 mg or equivalent) plus colchicine, the decision of switching to IL-1 blocker treatment should be tailored to the patient on an individualized basis, taking into account several parameters (such as tolerability, age and sex issues, patient preference). The use of anti-IL-1 agents may be associated with a moderate increase in the overall risk of mild to moderate infections. Safety data on anti-IL-1 agents are reassuring when considering new malignancy risk, whereas their safe administration in patients with known active malignancies has not been well investigated to date.

There is limited evidence for other drugs for pericarditis. Azathioprine has been empirically used in patients with recurrences and a lack of response to first- and second-level options such as aspirin/NSAID, colchicine, and corticosteroids.²⁸⁷ However, this drug seems more appropriate as a steroid-sparing agent, and has limited efficacy for those with acute pain. Intravenous immunoglobulins have also been tested in patients with refractory RP after failure of first and second options, as well as anti-IL-1 agents. These drugs may be efficacious either for infectious or non-infectious aetiologies, since they are able to clear infectious agents and modulate the immune response.²⁸⁸ Both corticosteroids and immunoglobulins have been

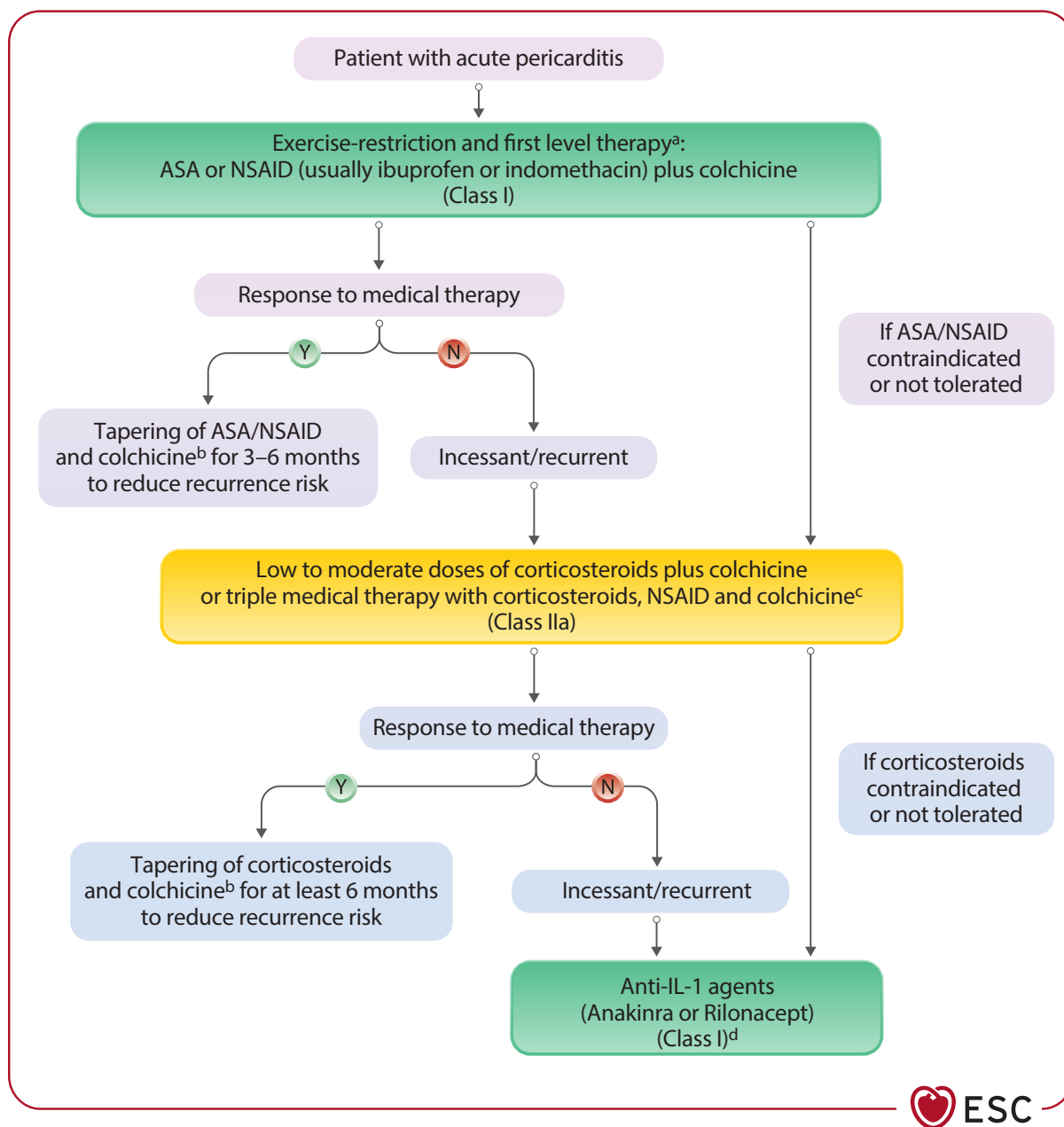


Figure 16 Proposed algorithm of medical therapy for pericarditis in adults (not including interventional therapies and pericardiectomy). ASA, acetylsalicylic acid; IL-1, interleukin-1; CRP, C-reactive protein; CMR, cardiovascular magnetic resonance; LOE, level of evidence; N, no; NSAID, non-steroidal anti-inflammatory drug; Y, yes. ^aASA is the first option if patients are already on antiplatelet therapy with ASA. Ibuprofen is usually preferred as the first NSAID. Try more than one agent to evaluate response. Gastroprotection with a proton pump inhibitor is always recommended with use of aspirin/NSAID. ^bColchicine is recommended to prevent recurrence. Consider at least 3 months for the first episode of pericarditis and at least 6 months for incessant/recurrent cases. Colchicine to be withdrawn as last drug only after stable remission. Tapering is recommended to reduce the persistence/recurrence of symptoms. Tapering is slower for corticosteroids. Colchicine tapering is usually not performed due to the duration of >3–6 months of therapy. Suggested schemes of tapering are reported in [Table 12](#). For response to therapy we considered clinical remission. ^cLow to moderate dose of corticosteroids (e.g. prednisone 0.2–0.5 mg/kg/day or equivalent doses of an alternative corticosteroid). ^dClass I LOE A, Class IIa LOE C regardless of C-reactive protein levels if CMR evidence of pericardial inflammation.

proposed for a non-inflammatory presentation (so-called non-inflammatory phenotype).^{288,289}

More recently, hydroxychloroquine has shown a steroid-sparing effect and increased flare-free survival in RP in patients with colchicine resistance and corticosteroid dependence.²⁹⁰ Treatment duration with aspirin/NSAIDs and steroids should be extended in an individualized

manner, and the tapering process should be slower than for a first episode of AP.¹

The dosing and duration of most common drugs used for pericarditis is summarized in [Table 13](#), while the proposed algorithm of medical therapy for pericarditis (not including interventional therapies and pericardiectomy) is illustrated in [Figure 16](#).

Recommendation Table 10 — Recommendations for medical therapy in pericarditis (see Evidence Table 10)

Recommendations	Class ^a	Level ^b
Colchicine is recommended as first-line therapy in patients with pericarditis as an adjunct to aspirin/NSAID or corticosteroid therapy to reduce subsequent recurrences. ^{24,25,108,275–278}	I	A
Anti-IL-1 agents (anakinra or rilonacept) are recommended for patients with recurrent pericarditis after failure of first-line therapies and corticosteroids and elevation of C-reactive protein levels to reduce recurrences and allow corticosteroid withdrawal. ^{108,275,282–284}	I	A
High-dose aspirin or NSAIDs with proton pump inhibitors are recommended as first-line therapy in patients with pericarditis to control symptoms and reduce recurrences. ^{291,292}	I	B
A β-blocker should be considered in symptomatic patients, despite full anti-inflammatory therapy, and heart rate at rest >75 b.p.m. in order to improve symptom control. ²⁷⁴	IIa	C
Anti-IL-1 agents (anakinra or rilonacept) should be considered in cases of incessant/recurrent pericarditis with evidence of pericardial inflammation on CMR after failure, contraindications, and intolerance to first-line therapies and corticosteroids regardless of C-reactive protein levels to reduce recurrences and allow corticosteroid withdrawal.	IIa	C
Low- to medium-dose ^c corticosteroids should be considered for patients with pericarditis only in cases of contraindication/failure of aspirin/NSAIDs and colchicine, or when there is a specific indication to control symptoms and reduce recurrences ^d .	IIa	C
Hydroxychloroquine may be considered in patients with recurrent pericarditis refractory to standard therapy (including corticosteroids and anti-IL-1 agents) to prolong recurrence-free survival. ²⁹⁰	IIb	B
Corticosteroids are not recommended as the first option for patients with pericarditis therapy without a specific indication ^d .	III	C

© ESC 2025

b.p.m., beats per minute; CMR, cardiovascular magnetic resonance; IL, interleukin; NSAID, non-steroidal anti-inflammatory drug.

^aClass of recommendation.

^bLevel of evidence.

^cSee Table 13.

^dFor example, systemic inflammatory disease on maintenance therapy with corticosteroids, post-pericardiectomy syndromes, post-vaccine pericarditis, severe renal failure, concomitant therapies interacting with NSAIDs such as oral anticoagulant.

6.3. Interventional techniques including circulatory support

6.3.1. Myocarditis

6.3.1.1. Short-term mechanical circulatory support

Myocarditis patients who present with rapid deterioration in haemodynamic status and rapidly progressive myocardial dysfunction are

amongst those who respond best to temporary MCS.²⁹³ Among temporary MCS, veno-arterial extracorporeal membrane oxygenation (VA-ECMO) represents the most frequently applied or recommended approach, ranging from 75% to 85% of AM cases.^{75,294–296} Despite the high risk and markedly compromised state of patients undergoing VA-ECMO support for FM, the prognosis is rather favourable, with a high rate of myocardial recovery and patient survival. Several national and international multicentre studies showed in-hospital survival ranging from 61% to 72%,^{297–300} but no freedom from HT in patients with giant-cell FM.²⁹⁴ Temporary MCS should be performed early and in a timely manner in patients with FM with refractory cardiogenic shock because of the high likelihood of recovery.

6.3.1.2. Intra-aortic balloon pump

As mentioned, EMB should be performed as soon as possible, even in the presence of temporary MCS,^{212,295} and specific immunosuppressive therapy should be considered at least as an initial option, while determining the myocardial response.²⁹⁵ An intra-aortic balloon pump (IABP) should be considered in cardiogenic shock as first-line MCS with prompt escalation to more powerful MCS if haemodynamic and end-organ perfusion improvement is not observed within a short time (1 h maximum).²⁹⁵

Recommendation Table 11 — Recommendations for interventional techniques including circulatory support in myocarditis (see Evidence Table 11)

Recommendations	Class ^a	Level ^b
A timely and dedicated Shock Team discussion is recommended in patients with myocarditis in the presence of haemodynamic compromise, to decide on the need for escalation to MCS and to determine a long-term management plan.	I	C
Temporary MCS ^c should be considered in patients with myocarditis and cardiogenic shock or acute decompensation in chronic myocarditis to stabilize the patients.	IIa	C

IABP, intra-aortic balloon pump; MCS, mechanical circulatory support; PLVAD, percutaneous left ventricular assist device; VA-ECMO, veno-arterial extracorporeal membrane oxygenation.

^aClass of recommendation.

^bLevel of evidence.

^cIABP, PLVAD, VA-ECMO.

6.3.2. Pericarditis

Pericardium-related interventional procedures are increasingly applied and require specific expertise.^{1,301} The use of percutaneous interventional techniques for pericarditis is not limited to perform percutaneous drainage, but also to obtain fluid samples for cytology and other pathological examinations (see [Supplementary data online, Table S7](#)). Moreover, interventional techniques are used to provide alternative treatment, such as balloon pericardiectomy or, less commonly, intrapericardial drug administration (e.g. corticosteroids or chemotherapy).

6.3.2.1. Pericardiocentesis and pericardial drainage

Percutaneous pericardiocentesis guided by echocardiography or fluoroscopy is indicated for CTP and symptomatic moderate to large PEffs

not responding to medical therapy, or when a search for aetiological agents is needed (e.g. suspicion of cancer, bacterial infection). Whenever possible, pericardiocentesis should not drain a large amount of pericardial fluid (usually <500 mL) to prevent pericardial decompression syndrome. Complete drainage of the PEff can be achieved, leaving a drain to be removed when the daily drainage is <30 mL. Surgical drainage is required when percutaneous pericardiocentesis is not feasible or purulent effusion is present, to allow complete drainage of the effusion and prevent its organization. Clinical triage has been proposed to indicate urgent management.¹¹⁸ An overall score of >6 indicates the need for urgent pericardiocentesis, whereas a lower score suggests delaying the intervention (see [Figure 12](#)).

Imaging is an essential component for guiding percutaneous pericardiocentesis. Under echocardiography, CT, or fluoroscopic guidance, a needle (usually 16–20 gauge) should be introduced into the subxyphoid space, although an apical or left-lateral approach might be used. The catheter should usually remain *in situ* for a few days, also based on the type and efficacy of concomitant systemic and/or topic pharmacological treatment.¹

6.3.2.2. Percutaneous balloon pericardiotomy

Percutaneous balloon pericardiotomy represents a percutaneous alternative to the endoscopic or surgical pleuro-pericardial window, which allows relapsing pericardial fluid to be absorbed through the ample pleural serosa, especially as palliative and temporary relief.¹ It should not be used as a first- or second-line intervention, but rather reserved for very rare cases, such as recurrent neoplastic PEff and CTP, as well as for absolute contraindications for surgery or in the case of a very poor quality of life in terminal patients (see [Supplementary data online, Table S8](#)).¹

6.3.2.3. Intrapericardial drug administration

Percutaneous access to the pericardium is done using an intrapericardial catheter following pericardial drainage. It may be used to deliver drugs targeting different conditions. Anti-inflammatory agents have been delivered with some efficacy. Intrapericardial crystalloid triamcinolone, 300 mg/m² of body surface, can be used for autoreactive or recurrent PEffs that do not respond to other conventional therapies, and to avoid or limit systemic side effects of oral corticosteroids. Chemotherapeutics have also been delivered, such as cisplatin and thiotepa (usually for lung and breast cancer, respectively), with demonstrated reduction of PEff relapse.^{302–304} Currently, due to improved chemotherapy, the systemic route is favoured, and therapeutic planning should involve a multidisciplinary team with cardiologists and oncologists.

Sclerosing agents, such as talc, to enhance pericardium–epicardium adherence and to reduce relapsing PEff, should not be used, because of reduced efficacy compared with a pericardial window or pericardiectomy, and the risk of inducing constriction.^{305,306}

6.3.2.4. Pericardioscopy

This procedure is sometimes considered as part of the diagnostic work-up, allowing pericardial biopsy. Pericardial access is also increasingly used for mapping and ablation of the epicardial substrates of VA, with an improved success rate and avoidance of a surgical procedure.

6.3.2.5. Pericardial fluid analysis, pericardial and epicardial biopsy

Percutaneous pericardial access may be used also to provide fluid samples for pathological and pathogen examinations (bacterial or viral aetiology), and/or to perform pericardial as well as epicardial biopsies, particularly in cancer screening (see [Supplementary data online, Table S7](#)).¹

6.3.2.6. Circulatory support

Mechanical circulatory support has been shown to be applied in up to 12% of pericardiectomy patients with pre-procedural RV dilatation/dysfunction,^{307–309} and is sometimes considered peri-operatively.^{307–309} The association of pre-procedural RV dilatation/dysfunction and reduced LV function also represent risk factors for a peri-procedural risk of early mortality, calling for timely and prophylactic MCS.³⁰⁸

Recommendation Table 12 — Recommendations for interventional techniques in pericarditis (see [Evidence Table 12](#))

Recommendations	Class ^a	Level ^b
Pericardiocentesis (echocardiography-, CT-, or fluoroscopy-guided) is recommended for cardiac tamponade, or suspected bacterial or neoplastic pericarditis, or symptomatic moderate to large pericardial effusion despite medical therapy.	I	C
Surgical pericardial drainage is recommended in patients with pericardial effusion when percutaneous pericardiocentesis is not feasible or with purulent pericardial effusion to allow complete drainage and to prevent constriction.	I	C
Surgical pleuro-pericardial window is recommended in patients with relapsing pericardial effusion despite medical therapy.	I	C

CT, computed tomography.

^aClass of recommendation.

^bLevel of evidence.

Downloaded from <https://academic.oup.com/eurheartj/article/46/40/3952/8234483> by guest on 13 April 2026

© ESC 2025

6.4. Surgical therapy

6.4.1. Myocarditis

The surgical treatment of myocarditis mainly accounts for HT, when there is no myocardial recovery. In addition to infective or autoimmune aetiologies, radiation-induced myopericarditis (usually secondary to haematological cancer) may contribute to the indications for such an intervention. Limited series of HTs due to radiation-induced myocarditis have been described with satisfactory results. Secondary malignancy, lung and kidney failure are negative prognostic factors for post-operative morbidity and mortality.³¹⁰ A durable ventricular assist device (VAD) or a total artificial heart are other alternatives for advanced cardiac support.²⁹⁵

6.4.2. Pericarditis

6.4.2.1. Surgical pericardiocentesis

Surgical pericardiocentesis is rarely performed for urgent/emergency conditions, but for large PEff requiring expeditious drainage, not achievable with percutaneous-based drainage (e.g. for purulent PEff or clot aspiration).

6.4.2.2. Pericardiotomy/pericardial window

These surgical procedures are carried out to create a connection, namely a pleuro-pericardial window, usually between the lateral or left posterior pericardium and the left pleura. The indication is relapsing PEff with haemodynamic compromise despite conservative treatment or percutaneous drainage. The pleuro-pericardial window is meant to promote drainage from the pericardium to the left pleural space.¹ Such a window may be created by a small thoracotomy or endoscopically. In selected cases, a pericardial window can also be created in the peritoneal cavity.

6.4.2.3. Pericardiectomy

Pericardiectomy is the mainstay treatment for chronic constriction or CP not responding to anti-inflammatory therapy.³¹¹ Complete pericardiectomy is recommended for the management of CP, as it offers superior long-term outcomes and significantly reduces the risk of recurrences compared with partial anterior or anterophrenic pericardiectomy, which may leave residual constrictive tissue and contribute to persistent or recurrent symptoms. Due to the relative rarity of the condition, and the complexity of patients, pericardiectomy should be performed at high-volume centres that have the required expertise.

Early pericardiectomy within 6 months after the onset of symptoms is associated with the lowest operative mortality.^{312,313} The occurrence of refractory RP and/or pericardial fluid formation, despite optimal medical and interventional therapy, is also considered a possible indication for surgical pericardiectomy. In the absence of a surgical plane for proper decortication, a pragmatic approach, named the waffle procedure, can be considered. This technique utilizes longitudinal and horizontal incisions to allow some relief of constriction. However, it usually offers only temporary improvement, with a high rate of recurrent constriction.^{314,315} Extracorporeal circulation may be required in difficult operative conditions, such as extensive calcifications with a high risk of marked bleeding during pericardiectomy. Previous 2015 ESC guidelines recommended resection 'of as much as possible' of the pericardium with avoidance of cardiopulmonary bypass (CPB), using this only in circumstances of difficult control of bleeding.¹ Cardiopulmonary bypass can play an important role in enabling safe and complete pericardiectomy, particularly in selected complex or high-risk cases.

Pericardiectomy is commonly performed without CPB. However, CPB may be necessary in specific clinical scenarios. These include dense adhesions between the pericardium and the myocardium, particularly involving the posterior surface of the heart. CPB is also indicated in cases of haemodynamic instability during dissection. This is especially relevant when heart lifting is required to access the diaphragmatic or posterior pericardium. Additional indications include calcific constrictive pericarditis with myocardial involvement, challenging anatomical conditions, or the need for concomitant cardiac procedures, such as valve surgery or coronary artery bypass grafting.

Possible benefits of CPB include providing a bloodless field and improved visibility for complete pericardial resection, especially posteriorly, avoiding myocardial injury by decompressing the heart during dissection, maintaining haemodynamic stability, particularly in patients with borderline cardiac output or tamponade physiology. However, the full heparinization required to perform CPB may, in some cases, favour bleeding generated by pericardial resection. Therefore, the indication for the use of CPB must always be taken into consideration intra-operatively and according to the anatomical as well as haemodynamic conditions encountered during the surgical procedure. It is, however, self-explanatory that a radical pericardiectomy, including also the posterior site of the pericardium, would be usually possible and advisable with the application of CPB. However, diaphragmatic pericardial resection may often be performed without CPB use, taking care to perform resection in a stepwise manner, without prolonging heart lifting and avoiding marked haemodynamic compromise.

Heart transplantation is very rarely indicated in patients with CP. However, it may be considered as a last-resort option in highly selected, exceptional cases. This applies when pericardiectomy is not feasible or cannot be completed due to extensive pericardial calcification with myocardial involvement, prior surgeries, radiation therapy, or infections that have caused severe adhesions and scarring. Surgical inaccessibility of

critical regions, such as the posterior pericardium, may also preclude complete resection. In some patients, persistent heart failure symptoms and progressive functional deterioration may occur despite maximal medical therapy and attempted pericardiectomy. In these cases, heart transplantation might be considered.

It is also an option when coexistent myocardial disease or a mixed constrictive–restrictive physiology is present, where pericardial resection would not be expected to improve symptoms or haemodynamic function.

In CP, tricuspid regurgitation (TR) is a common finding due to chronic elevated right-sided pressures, annular dilation secondary to long-standing volume overload and atrial enlargement, tethering of leaflets due to pericardial constraint. When TR is present in patients undergoing pericardiectomy, leaving the valve unrepaired can lead to persistent right HF symptoms (e.g. oedema, ascites, fatigue), poorer functional recovery post-operatively, and higher long-term mortality, as shown in retrospective observational studies. During pericardiectomy, the tricuspid valve is accessible, and repair (usually annuloplasty) can be safely performed with minimal added risk—especially when CP surgery is done under CPB. Thus, repair is recommended when TR is more than mild, and anatomy is suitable, and the patient is already undergoing pericardiectomy (i.e. no added surgery is required beyond access). Supporting evidence is limited. While RCTs are lacking, the recommendation is based on retrospective findings showing improved symptom relief and outcomes with combined surgery, and surgical principles in valve disease management but also the practicality and safety of valve repair when the chest is already open.³¹¹

Contraindications for pericardiectomy may include severe hepatic dysfunction with cirrhosis and ascites, uncontrolled infection or sepsis, and other life-limiting diseases. In some situations, advanced therapy, such as HT, might be the only solution due to unfeasible cardiac decortication, because of extensive calcifications or a high risk of cardiac and major vascular injury during pericardiectomy (for predictors of outcomes after pericardiectomy see also [Supplementary data online, Table S8](#) and [Section 3.2](#)).

Recommendation Table 13 — Recommendations for surgical therapy (see [Evidence Table 13](#))

Recommendations	Class ^a	Level ^b
Surgical pericardiectomy is recommended in patients with chronic pericardial constriction or persistent constrictive pericarditis despite medical therapy to improve symptoms and survival. ^{312,313}	I	C
Tricuspid valve repair is recommended in patients with pericardial constriction and severe tricuspid valve regurgitation to improve symptoms and survival. ³¹⁶	I	C

^aClass of recommendation.

^bLevel of evidence.

6.5. Management of arrhythmias and prevention of sudden cardiac death in myocarditis

Patients with myocarditis are known to be vulnerable to life-threatening arrhythmias, and careful observation and management of patients according to the risk stratification is needed. In the 2022 ESC Guidelines for the management of patients with ventricular arrhythmias and the prevention of sudden cardiac death, significant attention was paid to active

and chronic myocarditis.⁵⁸ In addition to these guidelines, our aim is to provide a special focus on several selected scenarios.

6.5.1. Role of active devices (wearable and implanted devices) in acute myocarditis

In AM, AVB may be reversible, and temporary pacing is often necessary in cases of haemodynamic compromise as a bridge to recovery.³¹⁷ In this setting, temporary transvenous external pacing with an active lead can be used for patients who require prolonged temporary pacing.^{86,318–320} In the absence of recovery within a clinically reasonable period, definitive cardiac pacing is usually necessary in patients with persistent high-degree AVB. In patients with LV dysfunction needing frequent ventricular pacing, CRT or conduction system pacing may be helpful.^{86,321} Permanent pacemaker placement can be considered in patients with AM for persisting high-degree AVB despite medical therapy.

Sustained VA in the context of AM is a rare phenomenon,⁷⁹ yet it poses a substantial risk of recurrence, persisting even after resolution of the acute phase. Studies indicate a high recurrence rate ranging from 28% to 60%, which appears higher in patients with monomorphic VT, chronically active myocarditis, anteroseptal LGE, and reduced LVEF.^{71,79,89,222,322–325} In myocarditis patients, polymorphic and irregular VA are more common during the active inflammatory phase, whereas monomorphic and regular VA are associated with healed myocarditis and scars.^{79,83,325} An arrhythmic presentation may raise suspicion of an underlying inherited CMP.⁹⁵ GCM is associated with a high risk of life-threatening VA and ICD implantation can be considered.³²⁶ The use of a wearable cardioverter-defibrillator (WCD) is feasible in selected patients with AM at higher risk of VA, when waiting for recovery or with a temporary contraindication for ICD.^{327–330} The resolution of inflammation does not necessarily indicate the absence of risk, because myocardial fibrosis may constitute an arrhythmogenic substrate, predisposing a patient to VA long after the acute episode. On this basis, arrhythmia risk stratification should be performed in patients with persistent LGE after the acute phase.³²⁵ In patients with prior myocarditis, sustained or non-sustained VT during an exercise test performed 6 months after the acute episode was found to be more common among those with an arrhythmic presentation, and was associated with subsequent adverse events, including malignant VA.³³¹ Late gadolinium enhancement was also identified as a significant predictor of adverse events, including malignant arrhythmias, irrespective of LVEF, especially in an anteroseptal location.^{332–334} Implantable loop recorders can be useful for early detection of VA in selected patients.⁸⁹ Details regarding oral anticoagulation can be found in the 2019 ESC Guidelines for the management of patients with supraventricular tachycardia, the 2022 ESC Guidelines for the management of patients with ventricular arrhythmias and the prevention of sudden cardiac death, and the 2024 ESC Guidelines for the management of atrial fibrillation.^{58,260,261}

Recommendation Table 14 — Recommendations for management of arrhythmias and prevention of sudden cardiac death in myocarditis (see Evidence Table 14)

Recommendations	Class ^a	Level ^b
Pacing in myocarditis		
Temporary transvenous external pacing should be considered in patients with acute myocarditis and high-degree conduction disorders as a bridge to recovery. ^{86,317,335}	IIa	C

Continued

WCD in myocarditis		
A WCD should be considered for 3–6 months in patients with sustained ventricular arrhythmia during the acute phase of myocarditis as a bridge to recovery. ^{323,325,327–330}	IIa	C
Ablation in myocarditis		
Catheter ablation, performed in specialized centres, should be considered in post-myocarditis patients with recurrent symptomatic SMVT or ICD shocks in whom AAD are ineffective, not tolerated, or not desired. ⁵⁸	IIa	C
ICD in myocarditis		
Secondary prevention		
ICD implantation is recommended in patients with non-active ^c myocarditis and haemodynamically not-tolerated sustained VT to prevent SCD. ^{78,79,322,336}	I	C
ICD implantation should be considered in patients with non-active ^c myocarditis and haemodynamically tolerated sustained VT to prevent SCD. ^{78,79,322,336}	IIa	C
ICD implantation may be considered in patients with acute myocarditis and sustained VA (VT/VF) in the acute phase to prevent SCD. ^{71,79,89,222,323–325}	IIb	C
Primary prevention		
ICD implantation may be considered in patients with myocarditis after the acute phase (3–6 months) and persistent risk factors for VA ^d to prevent SCD. ^{89,332–334,336}	IIb	C

AAAD, anti-arrhythmic drugs; CMR, cardiovascular magnetic resonance; ICD, implantable cardioverter-defibrillator; LGE, late gadolinium enhancement; LVEF, left ventricular ejection fraction; NSVT, non-sustained ventricular tachycardia; PVS, programmed ventricular stimulation; SCD, sudden cardiac death; SMVT, sustained monomorphic ventricular tachycardia; VA, ventricular arrhythmias; VF, ventricular fibrillation; VT, ventricular tachycardia; WCD, wearable cardioverter-defibrillator.

^aClass of recommendation.

^bLevel of evidence.

^cNon-active based on CMR evidence of activity (T2), see Figure 4.

^dNSVT, extensive LGE, unexplained syncope, positive PVS, reduced LVEF <50%.

7. Prognosis

The current literature focuses on the single condition, but one could expect that a patient with concomitant involvement of the myocardium and pericardium will have a worse prognosis. However, current published evidence suggests that patients with uncomplicated pericarditis and myopericarditis have a good overall prognosis, despite combined involvement of the pericardium and myocardium.^{4,337} The TF expects that the introduction of the term IMPS will increase awareness and will lead to dedicated studies in this regard.

7.1. Complications and outcomes for myocarditis

One of the main prognostic factors is the initial clinical presentation of myocarditis (Figure 8). Low-risk myocarditis (about 75% of unselected cases) usually has a chest pain presentation with preserved biventricular function, and an overall benign short- and long-term prognosis.²⁸ Acute complicated myocarditis with arrhythmic presentation, and especially HF presentation, has a worse prognosis.⁵⁶ There is conflicting evidence

on the role of sex in the prognosis of IMPS.⁷³ Women seem to have a more favourable prognosis than men in myocarditis.³³⁸ Young age and a previous myocarditis were independent relapse predictors. Fulminant onset, lower LVEF at presentation, distinct autoimmune features, especially in women, and high-titre organ-specific anti-heart autoantibodies and antinuclear autoantibodies were independent predictors of death and HT.⁷³ Genetic predisposition may also increase the risk (see Section 5.3).

The aetiology also plays a relevant role, e.g. EM, GCM and CS are associated with a worse prognosis (Sections 9.2–9.4). Outcomes are worse in patients with FM, in the case of late diagnosis and delayed interventions.⁵⁷ Factors associated with increased mortality or HT are GCM, QRS duration of >120 ms on initial ECG, or the need for temporary MCS other than IABP.⁵⁶ Biventricular dysfunction has been described as the main predictor of death or HT in myocarditis.^{63,66,73}

Multimodality imaging contributes to the assessment of prognosis. For example, myocarditis patients with normal CMR have a good prognosis.³³⁹ Late gadolinium enhancement on CMR at initial presentation is an important prognostic finding.³⁴⁰ In a multicentre study with AM and preserved EF, the presence of anteroseptal LGE in the mid-wall layer was the best independent predictor of the combined endpoint of cardiac death, appropriate ICD interventions, resuscitated cardiac arrest, and hospitalization for HF [odds ratio (OR) 2.73; 95% confidence interval (CI) 1.2–5.9; $P = .01$]. At a median follow-up of 4.3 years, 7.7% of these patients reached the combined endpoint.³ Anteroseptal LGE was the best independent predictor of SCD [hazard ratio (HR) 4.59; 95% CI 1.38–15.24; $P = .01$]. Myocardial fibrosis was present in 95% of patients with SCD, compared with 41% in patients without SCD.³⁴¹ Additionally, major arrhythmic onset (sustained VT or VF), presence of fibrosis at EMB, and induction of major VA on PVS all predicted major arrhythmic events.^{63,73,255}

In another study, including patients with AM and life-threatening arrhythmias, positive LGE in two or more myocardial segments and absence of oedema on initial CMR were associated with an increased risk for recurrent major arrhythmic events, including SCD [HR 4.51 (95% CI 2.39–8.53) and HR 2.59 (95% CI 1.40–4.79), respectively].⁷¹

Large studies are needed in the future to develop a risk stratification with a high negative predictive value for SCD and the need for ICD implantation. Variables for risk stratification for the progression to DCM are given in [Supplementary data online, Table S9](#).

7.1.1. Sequela and mortality in myocarditis

The main long-term complications are evolution to DCM with subsequent HF and (recurrence of) VA, including SCD.⁷⁶ LVEF recovery after myocarditis can be complete or partial. Recovery rates vary from 50% to 94% depending on the initial presentation.⁷⁴ These patients usually have a gradual deterioration of LVEF and subsequent dilation and might remain unrecognized and asymptomatic until development of overt HF. Myocarditis can cause about 10% of DCM.⁶⁶ Patients with B19V AM present most often with an infarct-like syndrome, and may have a favourable long-term prognosis,³⁴² but there is evidence describing cases with severe fatal outcomes.²²⁸ In contrast, patients with HHV-6 myocarditis (and especially those with B19V and HHV-6 co-infection) usually

present with acute HF symptoms, and frequently progress to chronic HF.³⁴²

Arrhythmias during myocarditis range from mild conduction abnormalities to life-threatening VT or VF, requiring medication and/or device therapy (refer to Section 6.5). The risk of VA is independent of LVEF.^{83,343}

Myocarditis may have a significant mortality. Initial complicated presentation and histological subtype predict the risk. Outcomes are worse in patients with FM, with a reported mortality at 60 days of 24%.^{56,73} Mortality also depends on the underlying cause of FM. In a study of GCM survivors beyond 1 year, the combined rate of death, HT, VAD implantation, or GCM recurrence was 47% at 5 years.³⁴⁴ Reported in-hospital mortality and long-term outcomes after an episode of AM vary.³⁴⁵ In a multicentre registry of patients with AM, complicated AM occurred in 27%, including 9% cases of FM. In-hospital mortality was 8.5%, compared with 0% in uncomplicated cases. Heart transplantation or LVAD was required in 3% and 4% of patients, respectively. Heart transplantation or death occurred in 18% of complicated cases after 5 years. Recurrences or VA occurred in approximately 3%–9% of cases over a period of 19–90 months.²⁸ In the recently reported contemporary ESC multicentre myocarditis registry of 581 patients with myocarditis, 2.7% of patients died, 1.7% received a HT, 0.7% underwent VAD implantation, and 3.9% underwent ICD implantation at 1-year follow-up.^{62,63,73}

7.1.2. Follow-up

Patients with low-risk myocarditis with chest pain presentation can be discharged when cardiac enzymes tend towards normalization. Time to recovery in AM varies from a few days to a few months. Relapses occur in about 10% of cases, with a 1-year recurrence rate of around 5%.^{10,73,346}

Follow-up is recommended in all patients with myocarditis, with clinical assessment, ECG, Holter-ECG registration, exercise test (if no signs of ongoing inflammation), echocardiography, and CMR within at least 6 months after the index hospitalization (see Table 15).^{10,62} The prognosis is determined by baseline and 6-month LV function, regardless of the initial clinical presentation.^{62,63,73} Cardiovascular magnetic resonance should be performed at least within the first 6 months in patients with definite myocarditis to guide the timepoint for return to work, based on the individual case.

It is generally accepted to wait 3–6 months after an acute episode of myocarditis to evaluate the need for an ICD. In some patients at high risk for VA (see Section 6.5.1),⁷¹ a WCD should be considered during follow-up as a bridge to recovery.⁵⁸ Subsequently, after 3–6 months of follow-up, the decision on whether or not to implant a definitive ICD is based on the individual patient, with increasing indication based on risk factors including genetic predisposition (see Section 5.3, Section 6.5.1; see Figure 17). In patients presenting with symptomatic VA, or heart block in GCM or CS, early consideration of an ICD is warranted.⁵⁸ Recommendations concerning arrhythmias and SCD in specific forms of myocarditis are discussed in Section 6.5.⁵⁸ In uncomplicated cases, a follow-up at 6, 12, and 24 months is sufficient, while it should be prolonged and be lifelong in complicated cases or with residuals.

See [Supplementary data online, Section 8](#) for patient communication advice.

Recommendation Table 15 — Recommendations for risk stratification, complications, and outcomes of inflammatory myopericardial syndrome (see Evidence Table 15)

Recommendations	Class ^a	Level ^b
Follow-up with clinical assessment, biomarkers ^c , ECG, exercise test, Holter-ECG monitoring, echocardiography, and CMR at least within 6 months after the index hospitalization is recommended in all patients with myocarditis to identify a potential progression or new risk factors. ⁶²	I	C
Long-term follow-up is recommended for patients with complicated myocarditis ^d to identify a potential progression or new complications. ^{28,74}	I	C
Long-term follow-up is recommended for patients with incessant or recurrent pericarditis to identify a potential progression and new complications. ^{104,347}	I	C

© ESC 2025

CMR, cardiovascular magnetic resonance; ECG, electrocardiogram.

^aClass of recommendation.

^bLevel of evidence.

^cAt least troponin.

^dSee definition of complicated myocarditis in Table 3.

7.2. Complications and outcomes for pericarditis

Risk stratification of patients with pericarditis must be performed at the initial presentation at the emergency department or in an ambulatory setting. Admission is recommended in high-risk cases.^{105,130} Non-high-risk cases can be managed as outpatients with a close follow-up within 1 to 2 weeks (Figure 7). ECG changes (mainly widespread ST-segment elevation) and troponin elevation were usually not negative

prognostic markers in this setting with an infarct-like presentation and preserved biventricular function.^{4,35}

In the real world, approximately 25% of patients diagnosed with AP present with at least one predictor of poor prognosis and require hospitalization.¹³⁰ The in-hospital mortality rate for AP is around 1% on average, but can be higher in older patients and those with severe co-infections.²³

According to the clinical presentation, additional diagnostic work-up should be performed only for a specific clinical suspicion, the presence of high-risk features, or a lack/incomplete response to empirical anti-inflammatory therapy (Table 16).

The usual course of AP is characterized by clinical remission after medical therapy within 4–6 weeks. The most common and problematic complication of pericarditis is RP, which affects 20%–30% of patients not treated with colchicine. About 10% of patients may present with continued symptoms without clinical remission. Such cases have been labelled as ‘incessant’, and may directly progress to constriction in few months,¹⁰⁴ while this complication is extremely rare in idiopathic RP.^{114,347} A course with multiple recurrences is possible, but not usual in simple presumed viral pericarditis, and should prompt a search for an underlying cause (Figure 14).

Cardiac tamponade is relatively rare in AP, as well as CP (<1% of cases). The risk for complications is related to the aetiology. For instance, the risk of CP is low after presumed viral/idiopathic pericarditis, intermediate for immune-mediated aetiologies, as well as PCIS and neoplastic pericarditis (2%–5%), and high for bacterial pericarditis (20%–30%), especially if purulent.³⁴⁷

At least three scores^{43,44,348} have been proposed recently to identify patients at increased risk of developing complicated pericarditis and chronicity, requiring close follow-up (see Supplementary data online, Tables S2 and S3). However, these scores have not been validated or replicated in additional larger studies, and remain investigational.

Table 15 Follow-up in inflammatory myopericardial syndrome after discharge

		Within 1 month	Within 3–6 months	12 months	>1 year and long-term FU ^a
Clinical evaluation and ECG	Myocarditis	X	X	X	X
	Pericarditis	X	X	X	X
Biomarkers (Tnl, C-reactive protein)	Myocarditis	X	X	(X)	(X)
	Pericarditis	X	X	(X)	(X)
Rhythm (stress and/or Holter-ECG)	Myocarditis	–	X	(X)	(X)
	Pericarditis	–	–	–	–
Imaging myocarditis	TTE		X ^b	X ^c	X ^c
	CMR		X ^b	X ^c	X ^c
Imaging pericarditis	TTE		X ^b	X ^c	X
	CMR		(X) ^b	(X) ^d	(X) ^d

CMR, cardiovascular magnetic resonance; ECG, electrocardiogram; FU, follow-up; IMPS, inflammatory myopericardial syndrome; Tnl, troponin I; TTE, transthoracic echocardiography.

All follow-ups should be adapted to the clinical situation and severity. In round brackets, optional testing according to clinical presentation [(X), case-by-case decision].

^aA long-term FU, e.g. after 2 years, is suggested only for complicated cases of IMPS, usually myocarditis.

^bIn complicated cases or if abnormal at 1 month, imaging should be repeated between 3 and 6 months.

^cIf abnormal at 6 months, imaging should be repeated within the next 6 months and/or in the next 12 months.

^dFollow-up proposed for uncomplicated cases of acute pericarditis. Long-term follow-up, tailored to the single patient, is recommended for high-risk cases.

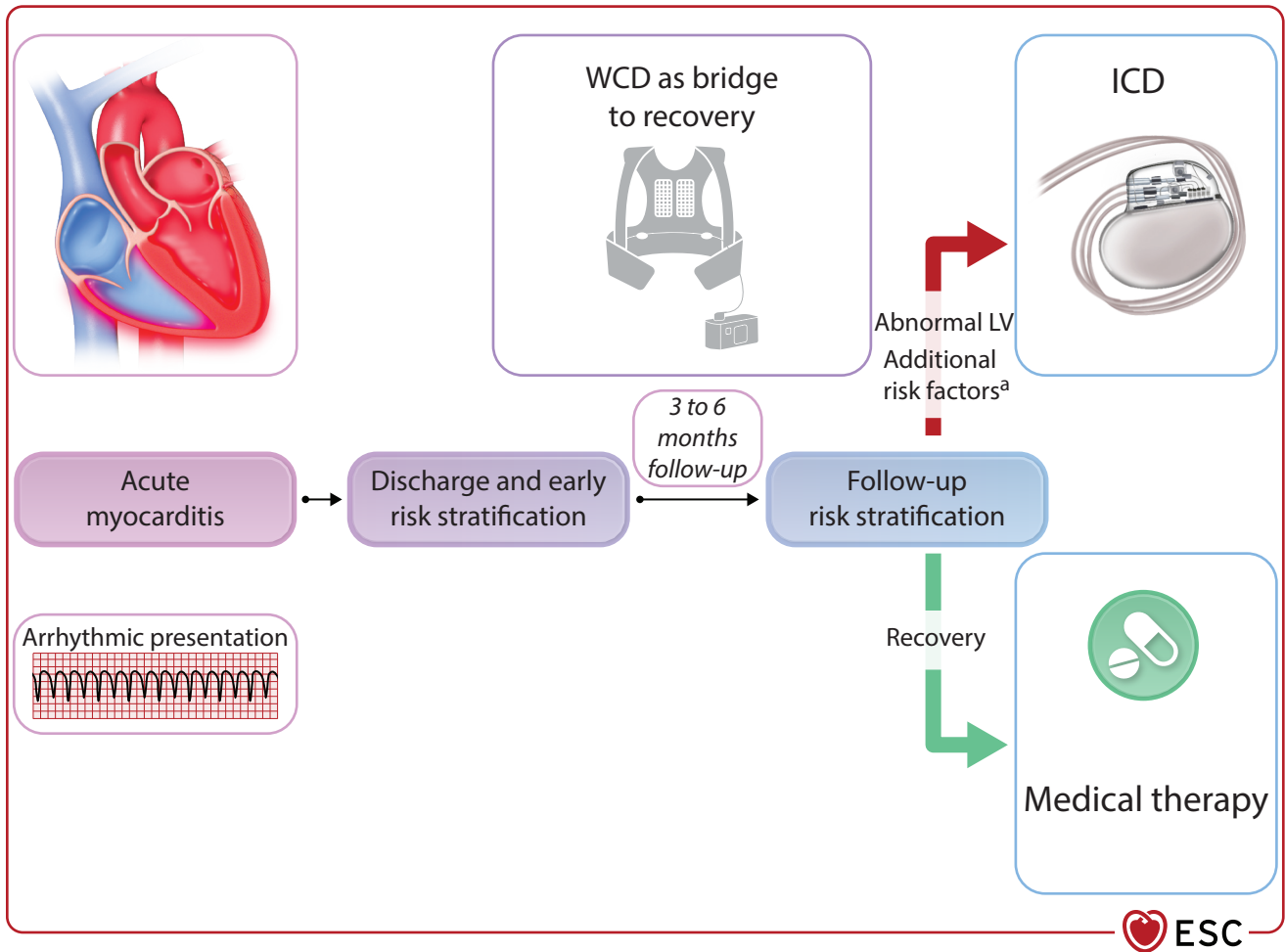


Figure 17 Follow-up and risk stratification after acute myocarditis with arrhythmic presentation. ICD, implantable cardioverter-defibrillator; LGE, late gadolinium enhancement; LV, left ventricle; LVEF, left ventricular ejection fraction; NSVT, non-sustained ventricular tachycardia; PVS, programmed ventricular stimulation; WCD, wearable cardioverter-defibrillator. Rarely for a high risk, cardioverter-defibrillator implantation may be considered before discharge (see text for detailed discussion). ^aAdditional risk factors (at least 1, increasing risk and indication with >1 or more): NSVT, extensive LGE, unexplained syncope, positive PVS, reduced LVEF of <50%.^{327–329}

Table 16 Indicators of non-viral aetiologies and complications (high-risk features or red flags in acute pericarditis)

Major
Fever >38°C (HR 3.56)
Subacute onset (HR 3.97)
Large pericardial effusion (>20 mm on echocardiography) (HR 2.15)
Cardiac tamponade (HR 2.15)
Lack of response to aspirin or NSAID after at least 1 week of therapy (HR 2.50)
Minor
Pericarditis associated with myocarditis
Immunodepression
Trauma
Oral anticoagulant therapy

© ESC 2025

HR, hazard ratio; NSAID, non-steroidal anti-inflammatory drug. Major features have been validated in multivariable analysis in a prospective cohort study of patients with acute pericarditis.¹⁰⁵

8. Inflammatory myopericardial syndrome overlapping types: myopericarditis and perimyocarditis

IMPS includes a spectrum of inflammatory diseases from isolated myocarditis to isolated pericarditis through a combination of both. IMPS should be used as an umbrella term, also covering overlapping forms of myocarditis and pericarditis.¹ The diagnosis of predominant pericarditis with myocardial involvement, or ‘myopericarditis’, can be clinically established if patients with definite criteria for AP show elevated biomarkers of myocardial injury, without newly developed focal or diffuse impairment of LV function on TTE or CMR. The term myopericarditis indicates a primarily pericarditic syndrome with minor myocardial involvement, which describes the majority of combined pericarditis and myocarditis cases encountered in clinical practice. On the other hand, evidence of new-onset focal or diffuse reduction of LV function in patients with elevated myocardial biomarkers, and clinical criteria for AP, suggests predominant myocarditis with pericardial involvement,

termed 'perimyocarditis'. The clinical management and outcomes of mixed forms follow the predominant involvement. At present, patients with myopericarditis can be treated as patients with pericarditis, while patients with perimyocarditis should be managed as patients with pure myocarditis. The knowledge in the field is rapidly evolving and ongoing trials and evidence will provide more updated guidance for clinical management.

A common scenario with overlapping forms of myocarditis and pericarditis is represented by systemic immune disorders, which can affect either the myocardium or pericardium, or both.

Several systemic inflammatory and autoimmune diseases may present with myocarditis, pericarditis, mixed forms, or PEff without pericarditis. Main conditions include RA, SLE, Sjögren's syndrome, SSc, polymyositis and dermatomyositis, and vasculitis (e.g. particularly EGPA).

8.1. Inflammatory myopericardial syndrome in systemic disorders

Inflammatory myopericardial syndrome may complicate several types of systemic diseases, generally immune-mediated,^{349,350} either with myocardial (myocarditis) or pericardial involvement (pericarditis and/or PEff). Symptoms and signs that may raise the suspicion of a rheumatic autoimmune disease are family history, history of low-grade fever, joint symptoms, dry eyes and mouth, headache, lymphadenopathy, Raynaud phenomenon, skin rash, oral and genital aphthae, deep or superficial vein thrombosis, recurrent foetal losses, lymphopenia, and chronic increase of CK and other inflammatory markers. Targeted therapy should be applied, if a specific diagnosis is reached during the diagnostic work-up.

8.1.1. Rheumatoid arthritis

Pericarditis can be seen as part of the inflammatory activity in RA, and is often present concurrently with pleuritis. It is the most common cardiac manifestation, affecting up to 50% of patients, as detected on post-mortem examination. Myocarditis may also be present, and generally resolves if the disease is controlled.³⁵¹ Anakinra, already registered for the treatment of RA, can be used also for related pericardial involvement.

8.1.2. Systemic lupus erythematosus

Pericarditis is the most common cardiac manifestation of SLE, reported in approximately 25% of patients, and it is included in the American Rheumatism Association/American College of Rheumatology (ARA/ACR) classification criteria.³⁵² Myocardial involvement in SLE affects about 5% of patients.^{353,354,355} Symptoms of IMPS are often non-specific, including elevated troponin, alterations on the ECG, LVEF abnormalities, and PEff. These manifestations are usually associated with typical symptoms of SLE, including fever, arthritis, nephritis, and skin rashes.^{356,357} The diagnosis can be supported by specific laboratory markers, as well as multimodality imaging, to guide the therapy.^{358,359} Endomyocardial biopsy could be rarely considered in selected cases.³⁴⁹ Cardiac tamponade occurs in less than 2% of cases, and CP is extremely rare. Cardiomyopathy is uncommon clinically, but autopsy studies found myocardial involvement in 40%–50% of patients.

8.1.3. Antiphospholipid syndrome

Antiphospholipid syndrome is associated with the presence of anti-cardiolipin and/or anti- β_2 -glycoprotein antibodies, and/or lupus anticoagulant, and may be the cause of myocardial dysfunction through various mechanisms. While myocarditis can manifest in this syndrome,

mediated by autoimmune mechanism, myocardial damage can be also caused by microthrombotic phenomena.^{360,361}

8.1.4. Sjögren's syndrome

In Sjögren's syndrome, the most common clinical manifestation of cardiac damage is pericarditis, which has been reported in less than one-third of cases. Myocarditis and myocardial fibrosis are also possible,³⁶² and may occur associated with rhythm disturbances. Specific antibodies (anti-Ro/SSA) could also be identified in unexplained heart blocks.³⁶³

8.1.5. Systemic sclerosis

Inflammatory myopericardial syndrome is frequent in SSc,³⁶⁴ often clinically occult and, when symptomatic, the prognosis is poor. It may be related to ventricular dysfunction and/or structural damage of the microvascular bed, leading to repeated focal ischaemic injuries and irreversible myocardial fibrosis. It can be also due to a primary systemic myositic disease.^{349,365} Damage usually follows two pathways.³⁶⁶ The first one is linked to the production of collagen by activated fibroblasts at the myopericardial level, especially at the subepicardial level, with consequent fibrosis, valve stenosis, coronary spasms, and ischaemic events. The second pathway is caused by renal and pulmonary involvement, with severe cardiac consequences.^{367,368} Further research is needed to improve the understanding of IMPS in SSc.³⁶⁴

8.1.6. Polymyositis and dermatomyositis

The myocardium can be affected in inflammatory myopathies, such as polymyositis and dermatomyositis,³⁶⁹ with consequent myocardial hypertrophy, ischaemia, cardiac enlargement, and systolic and diastolic ventricular dysfunction.³⁷⁰ Cardiac involvement in inflammatory myopathies is clinically occult in most patients, but may be suspected by multimodality imaging^{371,372} and is related to poor outcome.^{370,372} Myocarditis occurs in up to 30% of autopsied patients, with or without concomitant coronary or vessel vasculitis. Pericarditis is rarely reported in these patients.

8.1.7. Vasculitis

Myocardial involvement is prognostically relevant in vasculitis, particularly EGPA. In EGPA, about 15%–60% of patients present with cardiac disease³⁵⁰ including PEff, conduction disturbances, and motion abnormalities, as well as ACS, often due to coronary spasm, and EM (see Section 9.2). While cardiac involvement in EGPA often occurs early, it can be late in the course of the disease, and mainly affects anti-neutrophil cytoplasmic antibody (ANCA)-negative patients with high eosinophil counts. Myocardial and pericardial involvement is also possible in other vasculitis, especially in Kawasaki's disease, where myocarditis is a common cardiovascular complication (see [Supplementary data online, Figure S3](#)).³⁷³

Cooperation with specialists is important in all these systemic conditions to reach the correct diagnosis and to plan appropriate treatment. The diagnosis of EGPA may be particularly challenging.³⁴⁹

8.2. Inflammatory myopericardial syndrome in COVID-19 disease

The COVID-19 pandemic raised the awareness of IMPS, as in many patients the myocardium as well as the pericardium were affected. It is not proven whether the SARS-CoV-2 virus can directly damage cardiomyocytes or pericardiocytes, as it was suggested in cultivated human cardiomyocytes.³⁷⁴ Autopsy studies could only detect small amounts of virus

in the myocardium and pericardium.^{375–379} The true estimate of COVID-19-associated IMPS is variable depending on CMR/EMB-derived diagnosis ranging from 0.1–4.5/1000 cases^{380,381} up to 2%–8% of cases in symptomatic patients.³⁸² Symptoms as well as diagnostic work-up are similar to those described for general IMPS (see Sections 4 and 5).

The predominant management of symptomatic complicated SARS-CoV-2-related IMPS is antiviral treatment for SARS-CoV-2 virus together with supportive therapy. Several immunosuppressive therapies, such as anti-IL-1 (anakinra and canakinumab) and anti-IL-6 (tocilizumab and sarilumab), have demonstrated promising results in critically ill patients hospitalized for COVID-19.^{383–385} In less severe cases, the key elements for treatments are those recommended for IMPS. More details can be found in [Supplementary data online, Section 5.1.2](#).

9. Specific types of myocarditis

9.1. Lymphocytic myocarditis

The diagnosis of LM is based on pathological criteria and reflects an inflammatory disease that may be caused by viruses, but also by other infectious agents, including bacteria (such as *Borrelia* spp.) and protozoa (such as *T. cruzi*).¹⁰ Furthermore, contemporary single-centre and multi-centre cohort studies suggest that LM is more commonly non-infectious or immune-mediated/autoimmune.^{63,73} It is important to note that the aetiopathogenesis and outcome of viral LM varies considerably, based on the different infections. Cytolytic viruses, such as enteroviruses (e.g. coxsackieviruses and echoviruses), destroy cardiomyocytes and induce severe infiltration by macrophages and lymphocytes.³⁸⁶ In contrast to enteroviruses, vasculotropic B19V, which infects cardiac endothelial cells, but not cardiomyocytes, can also induce severe LM, especially in young children.^{228,387} High viral copy numbers (>500 viral DNA copies/μg of cardiac DNA) were found to be associated with cardiac inflammation and/or systemic infection.^{228,388} Low B19V DNA copy numbers in cardiac tissue rather reflect virus persistence, and are usually not related to cardiac inflammation. Lymphotropic viruses of the *Herpesviridae* family [HHV-6, EBV, human cytomegalovirus (CMV)], as well as HCV, influenza viruses, and SARS-CoV-2 may indirectly trigger myocarditis by activating the immune system.³⁸⁹ Regarding the aetiology and pathogenesis of myocarditis, microRNAs (miRNAs) may be promising diagnostic markers, as well as prognostic and therapeutic targets in myocarditis.^{141,390} However, the precise role of miRNAs in myocarditis remains to be determined.³⁹¹ In addition to infectious agents, organ-specific autoimmunity to heart autoantigens,⁶⁶ different systemic immune-mediated diseases, toxic substances, and drugs, including ICIs, are known to induce different forms of acute and chronic LM.⁶⁶ Immune-mediated myocarditis may occur with exclusive cardiac involvement or in the context of systemic immune-mediated diseases, such as SLE, SSC, and others.^{349,392} Interestingly, genetic host susceptibilities have also been linked to cardiac dysfunction following myocarditis.^{91,150}

9.1.1. Presentation

Since LM can be induced by various causes, there is no universal, specific clinical presentation. Instead, it must be considered in the context of the different diseases, in line with the stages of myocarditis.

9.1.2. Diagnosis and therapy

The diagnostic pathways were described above and vary depending on the cause. The diagnostic and therapeutic approach has to follow the clinical situation and the stages as described in Section 4 (see Table 12).

9.2. Eosinophilic myocarditis

Eosinophilic myocarditis is a rare form of myocarditis, characterized by eosinophilic infiltration of the myocardium. Underlying disorders that should be evaluated during the work-up of EM include: hypersensitivity and allergic reactions,²⁷¹ immune-mediated disorders, in particular EGPA; undefined complex HES or its myeloproliferative variant; parasitic infections; and cancer.³⁴⁹ A meta-analysis of single cases or small case series reported a rate of in-hospital death of up to 22%, and a significantly increased occurrence of the hypersensitivity form, up to 36%.²⁷¹

9.2.1. Presentation

The clinical presentation of EM can be variable, ranging from oligosymptomatic to acute FM, or chronic RCM (Loeffler CMP or endomyocarditis).²⁷¹ Nevertheless, prior study demonstrates that EM often has a fulminant presentation with abrupt impairment of LVEF, a high risk of malignant arrhythmias, and a high risk of thromboembolic complications, related to the formation of ventricular thrombi.²⁷¹ Although EM is often accompanied by peripheral eosinophilia, it should be noted that this finding is absent in up to 25% of patients with EM, and may contribute to the underdiagnosis of EM.

9.2.2. Diagnosis

The diagnosis of EM can be established by either the EMB-proven presence of eosinophilic infiltration of the myocardium, or the presence of CMR-proven myocarditis with pathognomonic findings associated with peripheral eosinophilia ([Supplementary data online, Figure S3](#)). Furthermore, general clinical signs related to EGPA or HES disorders should be evaluated, such as an increased number of eosinophilic cells, history of asthma and sinusitis, and characteristic skin lesions. Left ventricular function may be preserved, and DCM can occur, but often the phenotype of RCM is present. On echocardiography, a typical finding is Loeffler endocarditis. In the diagnostic work-up, systemic screening for the above-mentioned aetiologies should be carried out systematically.

9.2.3. Therapy

The first-line therapy for EM is the administration of i.v. corticosteroids, but caution should be exercised if EM is caused by an infectious agent. The optimal dose and duration of corticosteroids are unclear, but it is proposed to administer a daily i.v. bolus of corticosteroids followed by dosage tapering in severe forms, while oral steroid administration (see Table 12) can be considered in patients with mild LV dysfunction.^{39,271} The identification of an EM-associated condition is crucial to administer specific treatments, such as cyclophosphamide or IL-5 inhibitors in EGPA-related EM,³⁴ imatinib in the myeloproliferative variant of platelet-derived growth factor receptor alpha (PDGFRα)-associated HES, or albendazole in *Toxocara canis* infection. In hypersensitivity/allergic EM, first-line therapy is to withdraw the potential cause of eosinophilia.

Since endocavitary thrombi were reported in 12% of EM cases, the use of anticoagulation during the acute phase could be considered for the prevention of endocavitary thrombi.²⁷¹

9.3. Giant-cell myocarditis

Giant-cell myocarditis is a very rare, but often rapidly progressive disease with a poor prognosis, with an ~85% rate of death or HT at 3 years.^{56,82} The incidence of GCM was reported to range from 0.007% to 0.051% in autopsy studies; however, this number might

underestimate the true disease burden.^{393,394} Giant-cell myocarditis generally affects young and middle-aged adults without a sex predominance. In a large multicentre registry of GCM cases, patients were aged from 16 to 69 years at the time of diagnosis.⁸²

Giant-cell myocarditis is recognized as a non-infectious myosin-induced autoimmune form, as experimental models suggest,³⁹⁵ and an association with autoimmune disorders has been reported in ~20% of cases.⁸²

9.3.1. Presentation

Early symptoms of GCM might not differ from other types of myocarditis and vary widely at the time of presentation. In an international registry of 63 GCM patients, HF was the presenting symptom in 75% of cases.⁸² The initial manifestations might be progressive haemodynamic deterioration or cardiogenic shock, intractable arrhythmias, and SCD. The condition often progresses rapidly to death, often within days to months. A systematic analysis including 51 patients with GCM showed that the cumulative incidence of SCD (fatal or aborted) was 22% at 1 year and 26% at 5 years after presentation, and the composite incidence of SCD or VT was 41% at 1 year and 55% at 5 years.³²⁶ Other early GCM manifestations include bradyarrhythmias and cardiac conduction abnormalities, including complete AVB. In a study from Finland, 25% of individuals <55 years of age with clinically idiopathic heart block had GCM or CS on heart biopsy.³⁹⁶ The presence of AM complicated by treatment-resistant HF or cardiogenic shock, VA, and AVB should increase the clinical suspicion of GCM.

9.3.2. Diagnosis

Endomyocardial biopsy remains the gold-standard diagnostic modality for GCM and can identify these patients at an early stage.^{397,398} Patients diagnosed with GCM through EMB had a shorter symptom-onset-to-diagnosis time and milder heart damage than those diagnosed during HT.³⁹⁸

The presence of multinucleated giant cells in the absence of well-organized granulomatous lesions in the myocardial biopsy specimen is the hallmark of GCM. The giant cells are typically located in the interstitium or around blood vessels and are characterized by their large size, multinucleation, and cytoplasmic granules.

Giant-cell myocarditis is characterized by myocardial destruction mediated by a large number of T cells, macrophages, multinucleated giant cells, and eosinophils in EMB.³⁹ Generally, the histological diagnosis of GCM is guided by myocyte necrosis, diffuse infiltration of inflammatory cells, and interstitial fibrosis.^{399,400} The severity of necrosis and fibrosis in EMB predicts the outcome.⁴⁰¹ It is important to understand that one set of non-diagnostic EMB samples does not exclude GCM. The sensitivity of the first biopsy is 68% and increases to 93% when the biopsy is performed up to three times. Thus, repeated EMB should be considered when there is a high clinical suspicion of GCM.²¹⁷ In a single-centre case series of GCM, LGE on CMR was present in 96% of cases, and its distribution correlated with the histology.⁴⁰¹ Prompt EMB in the setting of suspected GCM can affect the choice of MCS, leading to an early listing for HT and consideration of cyclosporine-based immunosuppression.⁴⁰² Administration of i.v. steroids prior to EMB may reduce the diagnostic yield of EMB. There should be an agreement in specialized centres to prioritize the evaluation of EMB, and to provide the results at least within 3 days, optimally within 8 h.

9.3.3. Therapy

As soon as GCM is suspected, immunosuppressive therapy should be initiated promptly to avoid disease progression and delay HT. It is crucial

that the therapy should be initiated based on a strong clinical suspicion. Historically, the survival of patients with GCM without immunosuppression was about 3 months from symptom onset to death or HT. Many studies have shown that immunosuppression is useful for the treatment of GCM. Immunosuppressive therapy typically involves two or three drugs, including corticosteroids, and at least one, and usually two additional immunosuppressive agents (see [Table 12](#)). In GCM patients, immunosuppression with corticosteroid monotherapy is not associated with a prolongation of transplant-free survival.⁸²

Patients with GCM should receive the same guideline-based treatment for HF and arrhythmias as patients with heart disease from other causes.^{12,58}

Cyclosporine is the most commonly used immunosuppressant. In multiple retrospective and prospective studies, concomitant use of cyclosporine was associated with improved prognosis. Combining immunosuppressive therapy with corticosteroids and cyclosporine, azathioprine, or both improved transplant-free survival on average to 12 months, while patients treated with corticosteroids alone survived on average 4 months.⁸² A cases series of GCM reported that 1-year transplant-free survival was 73% in patients who received corticosteroids and cyclosporine with or without muromonab-CD3, with a reported decrease of the degree of necrosis, cellular inflammation, and giant cells after 4 weeks of treatment.⁴⁰³ A systematic review of 27 studies with 43 biopsy-proven GCM cases requiring MCS showed that the administration of immunosuppressive therapy prior to MCS implantation was associated with significantly better survival than treatment with MCS alone. Immunosuppression may reduce the severity of HF in these patients by preventing further autoimmune destruction of the myocardium.⁴⁰⁴

Cessation or reduction of immunosuppression is associated with GCM recurrence as long as 8 years after diagnosis.^{344,403}

In a single-centre study, the risk of life-threatening VA in GCM patients exceeded 50% at 5 years after admission. Permanent ICD effectively terminated life-threatening ventricular tachyarrhythmias, and no GCM patient with the device suffered from a SCD.³²⁶

Transplantation could be considered for GCM patients who fail to respond to GDMT and immunosuppression. A recent systematic review and meta-analysis of 499 patients with CS and 69 with GCM who underwent HT found that 1- and 5-year survival rates in GCM patients were similar to those in transplant recipients with other HF aetiologies.⁴⁰⁵

Recommendation Table 16 — Recommendations for giant-cell myocarditis (see [Evidence Table 16](#))

Recommendations	Class ^a	Level ^b
EMB is recommended in patients with suspected GCM due to unexplained new-onset HF of up to 2 weeks associated with a normal or dilated left ventricle and new ventricular arrhythmias, second- or third-degree AVB, or failure to respond to usual care within 1 to 2 weeks to initiate specific treatment. ⁴⁰²	I	C
Combined immunosuppressive therapy is recommended in patients with a diagnosed GCM. ²¹⁷	I	C

AVB, atrioventricular block; EMB, endomyocardial biopsy; GCM, giant-cell myocarditis; HF, heart failure.

^aClass of recommendation.

^bLevel of evidence.

9.4. Myocarditis in sarcoidosis

Cardiac sarcoidosis is a form of inflammatory heart disease, coexisting with systemic sarcoidosis in 5%–10% of cases,⁴⁰⁶ or rarely, in isolation. The aetiology of sarcoidosis is not well understood, but may involve an autoimmune response after certain trigger(s) and genetic predisposition, which leads to the formation of non-caseating granulomas in multiple organs, typically in the lungs.⁴⁰⁷ On histopathology, the granuloma consists of CD68⁺ macrophages, CD68⁺ giant cells, CD3⁺ T lymphocytes, and CD20⁺ B lymphocytes. It is characterized by inflammation, oedema, lymphocytic infiltration, and replacement fibrosis.⁴⁰⁸ Cardiac sarcoidosis is often subclinical, with an estimated cardiac involvement in around 25% of cases on autopsy series in patients with sarcoidosis.^{409,410}

9.4.1. Presentation

Manifestations of CS may range from cardiac inflammation, conduction system disease, frequent ectopy, tachyarrhythmia, and HF, to SCD.⁴⁰⁷ Cardiac sarcoidosis may mimic different cardiac phenotypes, including ARVC,^{254,411–413} DCM, and hypertrophic CMP (HCM), but may also occur in patients with normal cardiac function.⁴¹⁴ Symptoms are non-specific, and often related to arrhythmias, especially AVBs and VTs. The challenge is to identify patients at risk, since SCD due to malignant arrhythmia is common.^{415,416}

9.4.2. Diagnosis

The diagnostic algorithm of CS is different in patients with or without known extracardiac sarcoidosis. Pathognomonic findings in non-invasive imaging are sufficient for the diagnosis of CS in cases with known systemic sarcoidosis.⁴¹⁷ In contrast, the diagnostic pathway in primary CS is more challenging, but typical multimodality imaging patterns are usually sufficient. Cardiac sarcoidosis can manifest as abnormalities on ECG, echocardiography, CMR, PET, EMB, and cardiac and inflammatory blood biomarkers (see Section 5.4). Electrocardiogram or cardiac rhythm monitoring may demonstrate conduction system abnormalities (such as AVB or bundle-branch block) and arrhythmias, including VT.⁴¹⁸ Echocardiography may reveal regional WMA in a non-coronary distribution, septal thinning, and ventricular aneurysms. Endomyocardial biopsy may be helpful in selected patients, but negative results do not rule out CS due to potential sampling errors.⁴¹⁹ Endomyocardial biopsy guided by imaging or EAM may improve the diagnostic yield (see Section 5.12).

Multimodality advanced cardiac imaging, such as CMR and FDG-PET, plays an increasing role in the management of suspected CS. Overall, compared with FDG-PET, CMR has higher sensitivity of 89%–95% vs 84%, respectively, but similar specificity of 78%–85% vs 82%, respectively, for the diagnosis of CS.^{408,420–428}

On CMR, CS has a wide range of potential findings, and is often considered the 'great mimicker' of various cardiac conditions, but the inter-ventricular septum is often involved⁴⁰⁸ and the 'hook sign'⁴²⁹ is recognized to be associated with a high probability of CS. For more details, see [Supplementary data online, Figure S3](#). A heavy burden of LGE is associated with a poorer prognosis and predisposes to VA, HF, and death in CS, and may guide clinical decision-making.^{430–436} Aside from LGE, the identification of ongoing myocardial inflammation is possible.^{30,437–441}

Fluorodeoxyglucose-positron emission tomography also allows detection of cardiac inflammation in CS.⁴²⁶ It requires careful patient preparation to suppress physiological ¹⁸F-FDG uptake. The classical finding is focal ¹⁸F-FDG uptake in the basal septum, with a concordant perfusion defect. Perfusion defects in the active stage of CS may be due to microvascular obstruction by inflammatory oedema, necrosis, or both, and are

not necessarily located in the same region as the ¹⁸F-FDG uptake.⁴²⁷ Hybrid PET-CMR may enable better detection of cardiac inflammation in a more comprehensive manner,^{440,442,443} but its availability is limited. Both CMR and PET may be used for imaging-guided EMB.

The intensity and extent of FDG uptake on PET is of prognostic relevance.^{443–449} In a meta-analysis of 37 studies of patients with CS, LGE on CMR and FDG uptake on PET were both predictive of MACE (all-cause death, cardiac death and aborted SCD, VA, and HF hospitalization).

Fluorodeoxyglucose-positron emission tomography has proved to be useful in predicting and monitoring the anti-inflammatory therapy response in sarcoidosis;^{204,450} however, the optimal timing for repeating PET studies for the assessment of treatment response is not well established.

In addition to clinical assessment, imaging modalities should be used for the short- and long-term management of patients with CS.

9.4.3. Therapy

The treatment of CS is currently not standardized, and is based on patient-tailored assessment, often with multidisciplinary input.⁴⁵¹ Treatment is targeted at controlling cardiac inflammation, myocardial scarring and dysfunction.^{13,431–436} First-line therapy includes corticosteroids (see Table 12).

Since resolution of conduction abnormalities with anti-inflammatory treatment remains unpredictable, definitive cardiac pacing is usually needed. AVB and the need for cardiac pacing are associated with a higher risk of sustained VA, which reached 31% at 5 years in the Finnish registry.^{416,452,453} Thus, it appears reasonable to propose an ICD with pacing ability rather than a pacemaker in CS patients with pacing indications. The risk of VA during follow-up is high in observational studies, in patients with low LVEF,^{416,452,454,455} presence of LGE on CMR,^{434,456–459} and positive PVS.^{456,460–464} There is a lack of data on the relationship between scarring extent and arrhythmia risk. Positron emission tomography-computed tomography may also help to stratify patients.⁴⁶⁵

Heart transplantation could be considered in a subgroup of patients with CS, similarly to GCM.⁴⁰⁵

Recommendation Table 17 — Recommendations for myocarditis in sarcoidosis (see Evidence Table 17)

Recommendations	Class ^a	Level ^b
Diagnosis		
CMR, using tissue characterization techniques, is recommended in patients with suspected CS to assess cardiac inflammation and myocardial involvement. ^{408,421–425}	I	B
¹⁸ F-FDG-PET is recommended for the diagnostic work-up, including detection of inflammation, as well as for follow-up and assessment of therapeutic response in patients with CS. ^{426–428}	I	B
Therapy		
ICD implantation is recommended in patients with CS and sustained ventricular arrhythmia (VT/VF) or aborted CA to prevent SCD. ^{58,396,416,454,455,466}	I	B
ICD implantation is recommended in patients with CS and LVEF ≤35% to prevent SCD. ^{416,452,454,455}	I	C

Continued

ICD implantation should be considered in patients with CS and LVEF >35% after resolution of the active phase with significant LGE, a history of arrhythmias, unexplained syncope, inducible sustained VA at PVS, or with persistent high-degree AVB to prevent SCD.^{416,434,452,453,456–464,467}

IIa

C

© ESC 2025

AVB, atrioventricular block; CA, cardiac arrest; CMR, cardiovascular magnetic resonance; CS, cardiac sarcoidosis; ¹⁸F-FDG-PET, [¹⁸F]-fluorodeoxyglucose positron emission tomography; ICD, implantable cardioverter-defibrillator; LGE, late gadolinium enhancement; LVEF, left ventricular ejection fraction; PVS, programmed ventricular stimulation; SCD, sudden cardiac death; VA, ventricular arrhythmias; VF, ventricular fibrillation; VT, ventricular tachycardia.

^aClass of recommendation.

^bLevel of evidence.

9.5. Specific infectious myocarditis (Viruses, Lyme, Chagas)

9.5.1. Viruses

A large variety of infectious agents (Supplementary data online, Table S1) can cause myocardial inflammation, but viruses are considered the most common cause among infectious forms of myocarditis. Data on the true prevalence of viral myocarditis are difficult to determine, since EMB is performed only in a subgroup of high-risk patients and in complicated cases. Moreover, a positive viral serological test does not imply myocardial infection and is not routinely recommended. Exceptions are HIV and HCV and for specific infections such as Lyme disease.¹⁰ The epidemiology of viral myocarditis has changed during the past three decades; while enteroviruses and adenoviruses have been considered the most common causes of viral myocarditis,⁴⁶⁸ vasculotropic viruses such as B19V,^{63,66,468} and lymphotropic viruses such as HHV-6 are increasingly found in EMB samples.^{342,469} The prognostic relevance of persistent B19V infection with low viral copy numbers remains controversial because its presence in myocardial tissue may not have direct pathogenetic significance,^{470,471} in contrast to acute B19V infection.²²⁸

9.5.1.1. Presentation

Symptoms vary according to the underlying cause and severity of disease. However, it generally follows the presentation of acute and chronic stages, as presented in Section 4.

9.5.1.2. Diagnosis

The diagnostic approach should follow the description outlined in Section 4 (Figures 5 and 6). The presence of more than 500 copies/μg of DNA in EMB is considered as the threshold for virus-related myocardial inflammation, and usually guides therapeutic choices (e.g. starting immunosuppression). Viral PCR analysis in EMB samples is performed to better characterize the pathological substrate causing myocarditis. If immunosuppression is needed, viral presence has to be ruled out by EMB.¹⁰ Contemporary PCR analysis for viral presence in EMB specimens and blood samples is utilized to rule out possible tissue contamination.^{10,469}

9.5.1.3. Therapy

Data are insufficient to support antiviral therapy for AM, as well as treatment with IVIG for presumed viral myocarditis.⁴⁷² Anti-herpesvirus drugs in patients with CMV or HHV-6 infection can be considered, although their efficacy has not been directly studied in patients with

myocarditis.¹⁰ Treatment with type I IFN in patients with enterovirus has been suggested to increase viral clearance, but large trials are missing.^{273,473–475} Antiviral therapies have to be prescribed and managed in collaboration with an infectious diseases expert with shared decision-making in the IMPS team.^{1,472}

9.5.1.3.1. Influenza virus. Supportive management is the backbone of severe influenza treatment. Myocardial involvement is rare, but should be considered in patients of any age with chest pain, tachycardia, and haemodynamic instability within 2–4 weeks from symptom onset. The effect of antiviral therapy on myocarditis is not clear, although oseltamivir is utilized in both inpatient and outpatient settings. Peramivir and zanamivir are used only for hospitalized patients. There are individual case reports of successful treatment with neuraminidase inhibitors.^{476–479} Peramivir has often been used in combination with either oseltamivir^{480,481} or zanamivir.⁴⁸²

9.5.1.3.2. Human immunodeficiency virus. The pathogenesis of HIV-associated myocarditis involves direct viral infection, co-infection with other viruses or bacteria, cytokine activity, side effects of highly active antiretroviral therapy (HAART), immune system dysregulation, and/or ischaemia. If HIV-associated myocarditis is diagnosed, therapy for HIV infection has to be started or continued. Highly active antiretroviral therapy has been reported to significantly decrease the incidence of cardiac involvement, especially pericarditis, arrhythmias, and DCM compared with patients treated with nucleoside reverse transcriptase inhibitors in a retrospective study of 1042 patients.⁴⁸³

9.5.2. Lyme carditis

Lyme carditis may be an early manifestation of Lyme borreliosis, a tick-borne disease, caused by *Borrelia* spp., which is one of the most common vector-borne diseases in the northern hemisphere.

9.5.2.1. Presentation

In cases of early disseminated infection, AM with possible associated pericarditis may occur, but LC is typically characterized by varying degrees of AVB, with third-degree AVB in approximately 25% of cases.⁴⁸⁴ Chronic LC often shows manifested persistent symptoms and signs, such as fatigue, cognitive dysfunction, headaches, sleep disturbance, neuropsychiatric and musculoskeletal symptoms, electrical conduction delays, and DCM.

9.5.2.2. Diagnosis

The suspicious index in LC score has been proposed to evaluate the likelihood of high-degree AVB to be caused by LC. It allows categorization of patients into low-, intermediate- and high-risk categories.⁴⁸⁵ Continuous ECG monitoring is required for patients presenting with syncope or with a PR interval of >300 ms, since this is a high-risk marker of progression to complete AVB.⁴⁸⁴ Serological tests are recommended for patients presenting with high-degree AVB and suspected LC.

9.5.2.3. Therapy

Atrioventricular block is often transient and typically resolves within 1–2 weeks of antibiotic treatment, therefore permanent pacemaker placement is not warranted for AVB associated with LC before starting therapy. Intravenous therapy with ceftriaxone is the recommended first-line treatment for patients with LC and AV disturbances,⁴⁸⁶ followed by oral antibiotics (doxycycline, amoxicillin, or cefuroxime) for

at least 14 days and up to 21 days (total antibiotic course), depending on the severity of clinical presentation and response to treatment. The prognosis for early-treated disseminated LC is favourable, with complete recovery occurring in most patients treated with antibiotics.^{484,487}

Although LC may resolve spontaneously, antibiotic therapy shortens the disease duration and prevents further complications.

9.5.3. Chagas disease

Chagas disease (CD) is a systemic disorder caused by the protozoan parasite *T. cruzi*, which is transmitted through a haematophagous triatomine insect vector in endemic areas, such as Latin America, and can be transmitted transplacentally, by infected blood, or even orally through ingestion of contaminated food and drinks. Current migration has made CD a global disease, and congenital transmission has become relevant in non-endemic areas, including Europe.

9.5.3.1. Presentation

Acutely infected individuals remain asymptomatic or show mild and non-specific symptoms. Intense direct tissue parasitism may result in AM in less than 5% of cases. Chagas disease may evolve into CMP in 20%–30% of cases. Common findings in patients with Chagas CMP include brady- or tachyarrhythmias, dilated ventricles with regional (mainly inferior, inferolateral, or apical) or global systolic dysfunction, and thromboembolism.

9.5.3.2. Diagnosis

Diagnosis of CD requires a high clinical suspicion. Polymerase chain reaction testing is the most sensitive test in acute infection while, for diagnosing chronic CD, the combination of two serological tests with antigens that detect different antibodies against *T. cruzi* is preferable. Multimodality imaging is able to support the diagnosis, as often apical aneurysms with and without thrombi can be detected by CMR.⁴⁸⁸

9.5.3.3. Therapy

Eradication of the parasite is a target in early phases, and anti-parasitic treatment should be provided as soon as possible, following detection of an acute infection. In the BENEFIT (Benznidazole Evaluation for Interrupting Trypanosomiasis) trial, 2854 patients with Chagas CMP were randomized to either benznidazole or placebo for 80 days. Benznidazole significantly reduced serum parasite detection, but there was no significant reduction in clinical cardiac deterioration at 5 years.⁴⁸⁹ Therefore, anti-trypanosomal treatment should not be routinely used in adult patients with chronic CMP, but it can be considered in early and mild forms^{490,491} (see *Table 12*). Patients with Chagas CMP should be treated according to HF guidelines. Chagas disease is associated with high morbidity and mortality, with an annual rate of cardiovascular death of 6%.⁴⁹² In this population, the benefit of ICD in primary and secondary prevention is controversial, since observational studies did not demonstrate a mortality benefit compared with amiodarone.⁴⁹³ However, a systematic review and meta-analysis showed that, in patients with previous VT, appropriate ICD interventions and electric storms were frequent, occurring at a rate of 25% and 9% per year, respectively, with an overall mortality of 9% per year.⁴⁹⁴ A case-based decision is warranted.

9.6. Drug- or vaccine-induced myocarditis

9.6.1. Drug-induced myocarditis

9.6.1.1. Immune checkpoint inhibitor-induced myocarditis

Immune checkpoint inhibitors have revolutionized cancer treatment and are approved in multiple cancer types. These agents are monoclonal antibodies blocking specific molecules that inhibit the immune response—CTLA-4 (cytotoxic T-lymphocyte antigen 4), PD-1 (programmed cell death protein 1) and its ligand PD-L1 (programmed death ligand 1), and LAG-3 (lymphocyte activation gene 3)—strongly enhancing T-cell responses against cancer. By activating the immune system, ICIs may induce immune-related adverse events, which can affect any organ. Myocarditis is one of the most feared complications,^{495–497} although rare, as it affects approximately 1% of treated patients, within the first weeks following the initiation of therapy.⁴⁹⁵ Since a growing number of patients are eligible for ICI treatment, the absolute number of cases is increasing. One of the largest case series, including 122 patients with ICI-associated myocarditis, recorded early onset after treatment initiation (median 30 days), and up to 50% mortality.⁴⁹⁶ A systematic analysis of the World Health Organization (WHO) pharmacovigilance database confirmed a high mortality rate up to 33%.⁴⁹⁸

The main risk factor for ICI-induced AM is combination therapy with two types of ICI, such as an anti-CTLA-4, e.g. ipilimumab, combined with an anti-PD-1, e.g. nivolumab.⁴⁹⁹

This complication affects mostly men⁴⁹⁵ and older patients (median age 65 years) with more comorbidities.^{28,495} Furthermore, if ICIs are combined with other cancer therapies, their toxicity aggravates.

9.6.1.1.1. Presentation. Immune checkpoint inhibitor-induced myocarditis is especially arrhythmogenic, including a risk of conduction disorders, and HF with reduced EF occurs in about half of patients.⁵⁰⁰ Myocarditis is frequently associated with peripheral myositis, which, when associated with respiratory failure, can negatively affect survival.

9.6.1.1.2. Diagnosis. When suspected, rapid diagnostic triage is needed.^{495–497} Early diagnosis is extremely important, usually including laboratory tests and multimodality imaging (*Section 5*). The detection of a coexisting CAD in older patients should not refrain from further work-up for myocarditis (*Table 4*). In inconclusive cases an EMB can be necessary. For more details, see the 2022 ESC cardio-oncology guidelines.⁵⁰¹

9.6.1.1.3. Therapy. After diagnosis, immediate discontinuation of ICI and early (within the first 24 h) initiation of corticosteroids is warranted. Up to 50% of patients will be refractory to corticosteroids. In this situation, second-line immunosuppression treatments are necessary (see *Table 12*).⁵⁰² In a prospective registry, the combination of ruxolitinib and high doses of abatacept, and screening for concurrent respiratory muscle failure, was associated with improved survival.⁵⁰² Long-term cardiovascular effects of ICIs become more and more relevant since a growing number of cancer patients are exposed to this therapy.^{503,504} Rechallenge with an ICI has to be considered following a multidisciplinary team discussion, based on factors such as the severity of the myocarditis, cancer prognosis, oncology treatment options, and patient preference.^{504,505} Details are given in the 2022 ESC guidelines for cardio-oncology.⁵⁰¹

Recommendation Table 18 — Recommendations for immune checkpoint inhibitor-associated myocarditis (see Evidence Table 18)

Recommendations	Class ^a	Level ^b
Diagnostic triage within 24 h is recommended ^c in patients with suspected myocarditis induced by ICI to initiate treatment rapidly. ^{495,496,501,504}	I	C
Immediate disruption of ICI and administration of high-dosage corticosteroids are recommended in patients with ICI-associated myocarditis in order to stop the inflammatory reaction and stabilize the patient. ⁵⁰⁴	I	C
Second-line immunosuppression treatment should be considered in patients with steroid-refractory ICI-associated myocarditis. ^{501,504}	IIa	C
Second-line immunosuppression treatment may be considered in patients with fulminant/severe ICI-associated myocarditis. ^{501,504}	IIb	C

© ESC 2025

ICI, immune checkpoint inhibitor.

^aClass of recommendation.^bLevel of evidence.^cSee Figure 5.

9.6.1.2. Other drugs associated with myocarditis

Many drugs have been associated with myocarditis (see [Supplementary data online, Table S10](#)), especially clozapine.⁵⁰⁶ The reported incidence of clozapine-associated myocarditis ranges from 0.1% to 5%.^{507,508} Drug-induced myocarditis may be associated with drug reaction with eosinophilia and systemic symptoms (DRESS) syndrome.⁵⁰⁹ Treatment is based on discontinuation of the drug and use of corticosteroids.

9.6.2. Vaccine-induced myocarditis

In 2002 the 'Brighton collaboration' was established with the aim to provide standards for the definition of adverse events after vaccination.⁵¹⁰

In a clinical context, different vaccines, apart from the SARS-CoV-2 vaccine, have been associated with myocarditis. The main association is with smallpox vaccine,⁵¹¹ with data deriving mainly from the US military population.

A systematic review reported cardiac events including IMPS after influenza vaccination, pneumococcal vaccine, and tetanus toxoid.⁵¹²

Few data reported myocarditis after receiving different vaccines (e.g. meningococcus, hepatitis A and B, diphtheria, poliovirus) (see [Supplementary data online, Table S11](#)).^{513–518}

A recent multicentre study reported good mid-term outcomes after COVID-19 vaccine-associated myocarditis without death or need for HT.⁵¹⁹ More detailed information can be found in [Supplementary data online, Section 5.1.2](#).

9.7. Pregnancy-associated myocarditis

Peripartum CMP (PPCM) is sometimes associated with myocardial inflammation, more common particularly in patients presenting with arrhythmias.⁵²⁰ Pregnancy-associated myocarditis (PaM) is a rare condition, and its incidence and prognosis varies regionally.^{521–523} Nutritional deficiencies, viral myocarditis, and autoimmune processes have been postulated as triggers. Recent data support the role of

neurohormonal changes of late pregnancy and delivery, as well as the role of genetic predisposition.⁵²⁴

9.7.1. Presentation

There is no clear distinction between the phenotype of PaM and PPCM. Women develop symptoms of HF during late pregnancy or after delivery, with the majority being diagnosed after delivery, typically in the first month post-partum. A minority of patients may present with pulmonary oedema, cardiogenic shock, severe arrhythmias,⁵²⁵ cardiopulmonary arrest, thromboembolic complications, and brain injury.

9.7.2. Diagnosis

There are no specific studies for PaM, therefore the guidance for PPCM should be followed. Transthoracic echocardiography should be performed in any suspected case. In PPCM, LVEF is typically <45%.⁵²⁶ Careful examination should be undertaken to clearly view the LV apex to detect intracardiac thrombi. Brain natriuretic peptide/N-terminal prohormone of brain natriuretic peptide are usually markedly elevated.^{527–529}

Cardiovascular magnetic resonance imaging is an advanced imaging modality if echocardiogram is inadequate, but gadolinium-based contrast agents should be avoided during pregnancy.^{530–532} Cardiovascular magnetic resonance is crucial to differentiate underlying causes.⁵³³ The detection of active inflammation can be performed without application of contrast media in CMR ([Figure 4](#)).

Peripartum CMP has been associated with a higher rate of recovery than other forms of HF with reduced EF,⁵³⁴ and remission frequently occurs within the first 3 to 6 months.⁵³⁵ Delayed recovery can also occur after 2 years.^{536,537}

9.7.3. Therapy

There are no dedicated studies for PaM, so advice is based on published literature for PPCM.

Treatment of HF is essential, with modifications to ensure foetal safety during pregnancy.^{521,538–540}

Low-molecular-weight heparins do not cross the placenta, and are preferred during pregnancy if the thromboembolic risk is high.⁵⁴¹ Direct oral anticoagulants are less well studied in pregnancy, and should be avoided. Anticoagulation should be continued until recovery of LV function.

Bromocriptine has been shown to improve LVEF at 6 months, but the results are contradictory.^{521,542–545}

Following delivery, most HF medications are compatible with breastfeeding. Many patients may also relapse. Treatment withdrawal and incomplete recovery of LV function are risk factors for recurrences.^{546,547}

Lifelong treatment has not been proven to be necessary. Pre-conception counselling should include discussion of the potential risks of recurrent myocardial dysfunction, even after recovery.⁵⁴⁷

Multidisciplinary teams are warranted for patient management.^{548,549}

10. Inflammatory cardiomyopathy

Inflammatory CMP is defined by chronic myocarditis in association with cardiac dysfunction and ventricular remodelling, with a clinical hypokinetic phenotype, either dilated or non-dilated, with or without arrhythmogenic substrate. It can also manifest as the evolution of a prior myocarditis, whether treated or untreated. Inflammatory CMP is involved in the pathogenesis of DCM. It includes immune-mediated/autoimmune forms and infectious subtypes.^{12,550} A genetic predisposition is

also important for the pathogenesis of inflammatory CMP.⁹ However, the rates, risk factors, and other characteristics of cases progressing from AM to chronic myocarditis or inflammatory CMP remain unknown.

10.1. Presentation

Patients with inflammatory CMP may present with new-onset/acute, subacute, or chronic HF. Although myocarditis resolves in >50% of cases, even spontaneously, approximately 25% of cases may present with persistent ventricular dysfunction, and more severe cases may progress to DCM.¹⁰

10.2. Diagnosis

A variety of clinical assessment, ECG, multimodality imaging, and, if needed, EMB can be used to reach a diagnosis. Persistent or chronic myocardial inflammation should be suspected in cases with non-ischaemic ventricular dysfunction associated with low QRS voltages, and persistent mild elevation of hs-TnT/Tnl. The absence of significant remodelling may be observed in the early phase of the disease. This suspicion can be confirmed by multimodality imaging (echocardiography and CMR) and EMB, especially in the presence of myocardial oedema observed at CMR. Inflammatory CMP may be familial in rare cases. In these patients, genetic testing should be discussed.

10.3. Therapy

Guideline HF treatment is recommended in patients with inflammatory CMP.^{12,259} Medical therapy should be tailored to the underlying cause in case of systemic disorders, especially in autoimmune diseases. Only one RCT showed an improvement of cardiac function with immunosuppressive treatment in patients with virus-negative inflammatory CMP.⁵⁵¹ Other non-randomized studies, often derived from single-centre and/or retrospective studies,^{34,131,551–555} suggest the efficacy of immunosuppression on top of optimized HF therapy, and support its safety. In patients with different immune-mediated myocarditis and HF, immunosuppressive therapy was safe.^{34,131,552–555} Therefore, the treatment should be based on histological/immunohistological and viral PCR examination of the biopsy specimens.

In untreated cases, progression to DCM and transplantation or death are observed.^{10,39}

Recommendation Table 19 — Recommendations for inflammatory cardiomyopathy (see Evidence Table 19)

Recommendations	Class ^a	Level ^b
Guideline-directed heart failure treatments are recommended in patients with inflammatory cardiomyopathy to improve and/or stabilize left ventricular function.	I	C
Specific medical therapy for the potentially underlying systemic disease is recommended in inflammatory cardiomyopathy.	I	C
Immunosuppressive therapy, guided by endomyocardial biopsy, should be considered in virus-negative inflammatory cardiomyopathies to suppress the autoimmune response. ^{34,131,551–555}	IIa	B

© ESC 2025

^aClass of recommendation.
^bLevel of evidence.

11. Specific types of pericarditis

11.1. Tuberculous pericarditis

In high-income countries, TB pericarditis accounts for up to 4% of pericardial disease, but it is increasing due to immigration. On the other hand, TB is the cause of clinically significant PEff in approximately 90% of HIV-infected and 50%–70% of non-HIV-infected individuals living in developing countries with a high prevalence of TB.⁵⁵⁶ It should be emphasized that most of the information on TB pericarditis comes from endemic areas in low-income countries and immunosuppressed patients.¹ Notably, the disease can occur at any age, and men are affected more frequently than women.⁴⁸ Tuberculous pericarditis has an overall mortality rate of 17%–40% at 6 months after diagnosis.⁵⁵⁷

11.1.1. Presentation

Clinical presentations of TB pericardial involvement include AP (most commonly with PEff), ECP, and CP, with these manifestations representing consecutive stages of a unique process rather than independent conditions.^{558,559} Specifically, the evolution of TB pericarditis encompasses four stages (Figure 18). The first stage or dry stage of AP is without effusion, the second stage with PEff (this is the form most commonly encountered in clinical practice) in up to 80% of cases, the third stage with progressive absorption of effusion, and the fourth stage with pericardial constriction. In the effusive phase, pericardiocentesis usually yields bloody effusion, and effusive–constrictive physiology may emerge after pericardial drainage. At this stage, lymphocytic exudate is mainly observed.⁵⁶⁰ The duration of each stage varies and depends on individual factors (e.g. HIV status), and early treatment may prevent progression.

11.1.2. Diagnosis

The diagnosis of TB pericarditis is challenging and in 15%–20% of cases the diagnosis may be missed.⁵⁶¹ A ‘definite’ diagnosis of TB is based on the presence of tubercle bacilli in the pericardial fluid or on a histological sample of the pericardium, by culture or by PCR (Xpert MTB/RIF and RIF ultra) testing. A ‘probable’ diagnosis is made when there is proof of TB elsewhere in a patient with unexplained pericarditis, a lymphocytic pericardial exudate with elevated unstimulated IFN- γ (uIFN- γ), adenosine deaminase or lysozyme levels, and/or an appropriate response to antituberculosis therapy in endemic areas.⁵⁵⁸ In a meta-analysis, the sensitivity and specificity of adenosine deaminase, which is probably the most widely used biomarker, were 90% and 86%, respectively, for the diagnosis of TB pericarditis.⁵⁶² Xpert MTB/RIF is highly specific (100%); however, it has a sensitivity of 64%, which increases to 78% when pericardial biopsy samples are employed.^{563,564} Pericardial fluid culture shows low sensitivity (53%–75%) and it is also time-consuming, needing more than 3 weeks to yield results. Interferon gamma offers superior accuracy for the diagnosis of microbiologically confirmed TB pericarditis compared with the adenosine deaminase (ADA) assay and the Xpert MTB/RIF test.⁵⁶³ In a meta-analysis, values of uIFN- γ in the pericardial fluid from studies using thresholds of 14–200 pg/mL showed very high sensitivity (97%) and specificity (99%) for the diagnosis of TB pericarditis, with a positive likelihood ratio of 187 and a negative likelihood ratio of 0.03.⁵⁶⁵ On the other hand, the tuberculin skin test and IFN- γ release assays are of limited value, especially in areas with a high burden of TB, since they cannot discriminate between previous exposure to *Mycobacterium* and active disease.⁵⁶⁶ A detailed approach is outlined in Supplementary data online, Table S12.

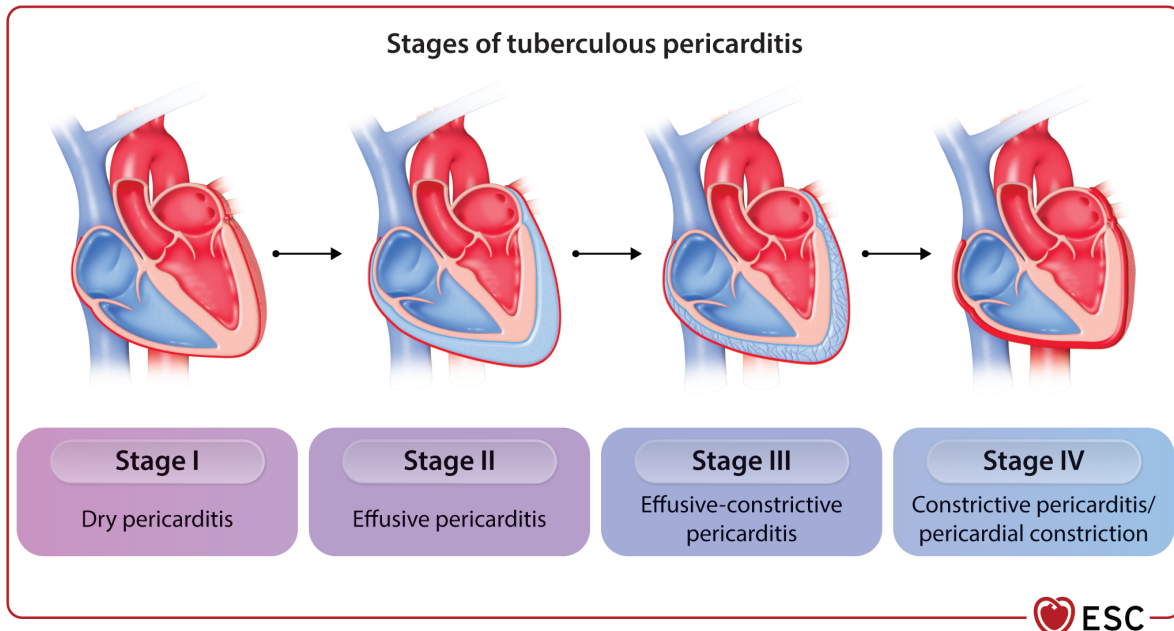


Figure 18 Stages of tuberculous pericarditis.

11.1.3. Therapy

Medical treatment consists of a regimen including rifampicin, isoniazid, pyrazinamide, and ethambutol for at least 2 months, followed by isoniazid and rifampicin for an additional 4 months, which is effective in treating extrapulmonary TB.^{1,567} Treatment for ≥ 9 months gives no better results and has the disadvantages of increased cost and poor compliance.⁵⁶⁷

However, it should be emphasized that, excluding isoniazid, poor drug penetration into the pericardial space is a matter of concern, also considering the emerging evidence of intrapericardial bacillary load and mortality.⁵⁶⁸

With the prompt use of antitubercular medications, steroids (oral or intrapericardial), and the widespread use of pericardial drainage with or without intrapericardial fibrinolysis, the currently reported rates of CP are between 5% and 25%.⁵⁶⁹ Moreover, contemporary treatment has accounted for a 20% reduction in all-cause mortality.^{567,569–572}

Pericardial drainage by any means (pericardiocentesis or pericardial window) is recommended as an essential part of the work-up in patients with suspected TB pericarditis, both for diagnostic and therapeutic purposes.¹

Constriction generally develops in up to 50% of patients within 6 months of presentation prior to the introduction of effective TB therapy.¹ Appropriate antibiotic therapy is essential to prevent this progression.⁵⁷⁰ In addition, two interventions may reduce the incidence of constriction: (i) intrapericardial urokinase; and (ii) high-dose adjunctive prednisolone for 6 weeks.^{569,573}

However, the coexistence of TB and HIV infection requires special attention. Prednisolone was associated with an increased risk of HIV-associated malignancies.⁵⁶⁹ On this basis, it may be reasonable to use adjunctive corticosteroids in patients with TB pericarditis without HIV infection and to avoid them in HIV-infected individuals.⁵⁶⁹

Recommendation Table 20 — Recommendations for tuberculous pericarditis (see Evidence Table 20)

Recommendations	Class ^a	Level ^b
Diagnosis and treatment of tuberculous pericarditis and effusion		
Diagnostic pericardiocentesis is recommended in all patients with suspected tuberculous pericarditis when diagnosis is not confirmed by non-invasive tests to identify the aetiological agent in pericardial fluid. ⁵⁷⁰	I	C
Empirical antituberculosis chemotherapy is recommended in patients living in endemic areas with exudative pericardial effusion after excluding other causes to treat the most likely cause. ^{567,570}	I	C
Standard antituberculosis multidrug treatment for 6 months is recommended in patients with tuberculous pericarditis for the prevention of pericardial constriction. ⁵⁷⁰	I	C
Pericardiectomy is recommended in patients with tuberculous pericarditis if the condition is not improving or is deteriorating after 4–8 weeks of antituberculosis therapy to change the course of disease.	I	C
Adjunctive steroid therapy should be considered in HIV-negative cases to prevent the development of constrictive TB pericarditis. ⁵⁶⁹	IIa	C
In non-endemic areas a pericardial biopsy may be considered in patients with >3 weeks of illness without aetiological diagnosis.	IIb	C
Empirical antituberculosis treatment is not recommended in patients living in non-endemic areas.	III	C

HIV, human immunodeficiency virus; TB, tuberculosis.

^aClass of recommendation.

^bLevel of evidence.

11.2. Pericardial involvement in neoplastic disease

11.2.1. Presentation

Neoplastic pericardial involvement is occasionally manifested by pericarditis or, more commonly, an isolated PEff (usually moderate to large, or CTP) with or without evident masses on imaging. It is usually related to metastatic lymphatic involvement (especially for lung cancer) or haematogenous spread (especially for breast cancer). In addition, lymphomas, leukaemias, and melanoma may affect the pericardium, as may cancer of contiguous organs (e.g. oesophageal cancer).^{574,575} Primary neoplastic disease of the pericardium is rare. Pericardial mesothelioma is the most common form, and it may present as ECP or CP in advanced cases. On this basis, the term 'neoplastic pericarditis' is often used incorrectly instead of 'neoplastic pericardial effusion'.

11.2.2. Diagnosis

The definitive diagnosis is based on the confirmation of malignant infiltration within the pericardial fluid by cytology (pericardiocentesis) or pericardial biopsy. A probable diagnosis may be achieved by the detection of tumour markers in the pericardial fluid (e.g. CEA, CYFRA 21-1, NSE, CA-19-9, CA-72-4, SCC, GATA3, and VEGF), although none of these tumour markers has been proven to be accurate enough for distinguishing malignant from benign effusions.^{576,577} Evidence of malignant disease elsewhere and concomitant pericarditis or PEff is also suggestive, although in almost two-thirds of patients with documented malignancy, pericardial involvement is caused by non-malignant diseases,¹⁵ e.g. radiation,^{578,579} chemotherapy,⁵⁸⁰ or infections. Cytological analyses of pericardial fluid are mandatory for the confirmation of malignant pericardial disease.⁵⁸¹ Analyses of pericardial fluid and less commonly pericardial or epicardial biopsies are essential for the confirmation of malignant pericardial disease.

11.2.3. Therapy

The management of these patients requires a multidisciplinary approach involving oncologists, cardiologists, and radiotherapists, as well as other specific subspecialty experts according to the type of cancer.

General principles of treatment include systemic antineoplastic treatment as baseline therapy. Local antineoplastic treatment is based on tailored intrapericardial therapy according to the type of tumour (e.g. cisplatin is efficacious in lung cancer, thiotepa in breast cancer),⁵⁸² and intrapericardial instillation of cytostatic/sclerosing agents to prevent recurrences. Malignant PEffs show a high recurrence rate (>50%). Extended pericardial drainage can be necessary in patients with suspected or definite neoplastic PEff to prevent effusion recurrence and provide a route for intrapericardial therapy. Additional interventions for recurrent effusions may include pericardiectomy, pericardial window, and percutaneous balloon pericardiectomy. All techniques are palliative and aimed at improving the quality of life of patients with a poor short-term outcome.

Radiation therapy is very effective in controlling malignant PEff in patients with radiosensitive tumours, such as lymphomas and leukaemias.

In clinical practice, management is often palliative at late stages with advanced disease, and it is aimed only at the relief of symptoms rather than treatment of the underlying disease, considering the prognosis, and the overall quality of life of the patient.

Recommendation Table 21 — Recommendations for neoplastic pericardial involvement (see Evidence Table 21)

Recommendations	Class ^a	Level ^b
Pericardiocentesis is recommended for patients with cardiac tamponade to relieve symptoms and establish the diagnosis of malignant pericardial effusion. ^{576,583}	I	C
Extended pericardial drainage (3–6 days) is recommended in patients with suspected or definite neoplastic pericardial effusion to prevent effusion recurrence. ^{576,583}	I	B
Cytological analysis of pericardial fluid is recommended in patients with neoplastic pericarditis for the confirmation of malignant pericardial disease. ⁵⁸¹	I	C
Systemic antineoplastic treatment is recommended in confirmed cases of neoplastic aetiology to treat the primary and secondary metastatic neoplastic involvement. ⁵⁸²	I	C
Pericardiocentesis should be considered in patients with moderate to large pericardial effusion to establish the diagnosis of malignant pericardial effusion when the diagnosis cannot be reached by multimodality imaging. ⁵⁸⁴	IIa	C
Pericardial or epicardial biopsy may be considered in patients with suspected malignant pericardial disease when the diagnosis cannot be reached by multimodality imaging or cytological analysis, to confirm the diagnosis.	IIb	C
Intrapericardial therapy, in agreement with the oncologist, may be considered in cases refractory to systemic antineoplastic treatment.	IIb	C

^aClass of recommendation.

^bLevel of evidence.

11.3. Post-cardiac injury syndrome

The term PCIS is an umbrella term indicating a group of inflammatory pericardial syndromes, including late post-acute myocardial infarction (post-AMI) pericarditis (or Dressler syndrome), post-pericardiectomy syndrome (PPS), and post-traumatic pericarditis with or without bleeding. Currently several post-traumatic cases are iatrogenic and related to cardiovascular interventions.^{585,586} Nowadays, Dressler syndrome appears in <1% of cases, mainly in larger infarctions and/or late reperfusion, typically 1–2 weeks after AMI.⁵⁸⁷ Notably, patients with a post-AMI PEff of >10 mm at end-diastole should be investigated for a possible subacute heart rupture.^{588,589}

In contrast, cases developing after cardiac device implantation or arrhythmia ablation (e.g. pericarditis appears in ~10% of cases after AF ablation) are becoming increasingly common due to the growing number of invasive procedures.^{586,587,590,591}

Such syndromes are presumed to have an autoimmune pathogenesis triggered by pericardial bleeding and/or pleura incision.^{47,592} An immune-mediated pathogenesis is supported by a latent period,

generally a few weeks, until the appearance of the first manifestations, the positive response to anti-inflammatory drugs, and the possibility of recurrences.

11.3.1. Diagnosis

According to proposed diagnostic criteria, the diagnosis of PCIS may be reached in the presence of at least two of the following five criteria: (i) fever without alternative causes; (ii) pericardial or pleuritic chest pain; (iii) pericardial or pleural rubs; (iv) evidence of PEff; and/or (v) pleural effusion with elevated C-reactive protein.^{593–595}

The rationale for proposing specific criteria is that these syndromes may have concomitant pleuro-pericardial involvement and possible pulmonary infiltrates, and are not simply pericarditis.⁵⁹⁵ Moreover, it is sometimes difficult to differentiate PCIS from the simple mechanical consequences of surgery (such as early pericardial or pleural effusion). The demonstration of inflammatory activity (e.g. C-reactive protein elevation) is essential to establish the diagnosis. Multimodality imaging can be helpful for the diagnosis of complicated cases (e.g. loculated effusions, evidence of inflammation).

11.3.2. Therapy

The same therapeutic scheme adopted for AP, essentially based on empirical anti-inflammatory therapy, is effective for all forms of PCIS, and may improve remission rates and reduce the risk of recurrences. In early post-AMI pericarditis, a 5–7-day course of aspirin seems the most reasonable option, in association with colchicine.⁵⁸⁷

Different treatment strategies (namely aspirin, methylprednisolone, dexamethasone, and colchicine) have been adopted for the primary prevention of PPS, and the effects of such treatments have been addressed in a meta-analysis that showed that only colchicine was associated with a decreased risk of PPS (OR 0.38), sometimes, however, with an increased risk of gastrointestinal side effects.^{593,594,596–600} Preventive administration of colchicine can be given after cardiac surgery using weight-adjusted doses (i.e. 0.5 mg once for patients ≤70 kg and 0.5 mg twice daily for patients >70 kg) and without a loading dose for the prevention of PPS and continued for 1 month.⁵⁹⁶

In this guideline document, the LOE for colchicine recommendation for the prevention of PPS is based on analysis of the available evidence from more than one RCT, systematic reviews and the consensus opinion of the TF members.

Neither NSAIDs nor colchicine have to be administered for post-operative effusions in the absence of systemic inflammation.^{601,602} Early post-operative PEffs are relatively common after cardiac surgery, and usually disappear spontaneously in 7–10 days.¹ Asymptomatic small PEffs do not require treatment; however, moderate to large effusions (observed in one-third of cases) can progress to CTP at a rate of 10% within 1 month after surgery and need pericardial decompression.⁶⁰³ Treatment of these asymptomatic effusions by NSAIDs has been shown to be ineffective [e.g. diclofenac in the Post-Operative Pericardial Effusion (POPE) trial], and may be associated with an increased risk of side effects.⁶⁰¹

The prognosis of PPS is generally good.⁶⁰⁰ In the largest published series on PPS patients after cardiac surgery, complication rates were low: <4% for recurrences; <2% for CTP; and no cases of constriction, although hospital stay may be prolonged in these patients.⁵⁹² Moreover, the development of CP has been reported in ~3% of cases.³⁴⁷ Both early post-AMI pericarditis and Dressler syndrome are markers of larger infarct size, but without independent prognostic significance.⁵⁸⁷

Recommendation Table 22 — Recommendations for post-cardiac injury syndrome (see Evidence Table 22)

Recommendations	Class ^a	Level ^b
Anti-inflammatory therapy is recommended in patients with PCIS to hasten symptom remission and reduce recurrences. ^{292,600}	I	B
IL-1 antagonists are recommended in patients with refractory PCIS to prevent recurrences and progression to constriction. ⁶⁰⁴	I	B
High-dose aspirin is recommended as the first-choice anti-inflammatory therapy for post-myocardial infarction pericarditis and in patients being already on antiplatelet therapy.	I	C
Colchicine, started 48 to 72 h before cardiac surgery, should be considered for 1 month in patients after cardiac surgery for the prevention of PCIS if there are no contraindications and if it is tolerated. ^{594,596}	IIa	A
Careful follow-up should be considered in patients with PCIS to exclude possible evolution towards constrictive pericarditis. ³⁴⁷	IIa	C

IL, interleukin; PCIS, post-cardiac injury syndrome.

^aClass of recommendation.

^bLevel of evidence.

11.4. Pericarditis and autoinflammatory diseases

Compared with the previous guidelines, it has become evident that some inflammatory forms of RP share similarities with genetic autoinflammatory diseases characterized by periodic fevers, e.g. FMF and TRAPS.^{50,51}

These are genetic disorders characterized by mutations of genes involved in the regulation of the inflammatory response, without involvement of specific T cells or autoantibodies.⁶⁰⁵ These disorders are usually detected in the paediatric population, although some patients experience disease onset during adulthood. The most common monogenic autoinflammatory syndromes include FMF, in which serositis episodes last only 1–3 days, and TRAPS, in which fever and symptoms last for weeks.⁶⁰⁵ Mutations associated with these disorders have been reported in up to 10% of patients with multiple recurrences, especially with a positive family history, and a poor response to colchicine.¹⁵² Recently, rare deleterious *MEFV* variants were observed more frequently in idiopathic RP than in ancestry-matched controls (allele frequency 9/200 vs 2932/129 200, $P = 0.040$).⁵⁰ These conditions are characterized by the exaggerated production of IL-1 by the inflammasome. Familial occurrence of pericarditis has been reported among the relatives of idiopathic RP patients, ranging from 4%⁵⁰ to 10%.¹¹³ These data suggest a genetic predisposition in at least a subset of patients; counselling may be warranted in these cases.

11.5. Purulent pericarditis

Purulent pericarditis, namely the most serious manifestation of bacterial pericarditis, is characterized by the macro- or microscopic presence of purulent PEff. It is an exceedingly rare form of pericarditis in the Western world, accounting for <1% of AP cases.⁶⁰⁶ It has a high mortality in untreated cases while, in optimally treated patients, the reported survival rate is approximately 15%–40%.⁶⁰⁶

In developed countries, the most common organisms isolated in purulent pericarditis include staphylococci and streptococci, while

the predominant associated lesions are empyema (50%) or pneumonia (33%). In immunosuppressed patients or following thoracic surgery, the most frequently encountered bacterial/fungal agents are *Staphylococcus aureus* (30%) and fungi (20%), while anaerobic bacteria, originating from the oropharynx, have also been reported.^{607,608}

It should be stressed that in the modern era of iatrogenic and HIV-associated immunosuppression, more unusual organisms may account for pericardial infection.^{1,607}

11.5.1. Presentation

Purulent pericarditis has generally manifested as a serious febrile disease, and the underlying sepsis may predominate, including septic shock.^{606–608} Constrictive pericarditis complicates 20%–30% of cases.³⁴⁷

11.5.2. Diagnosis

Suspicion of purulent pericarditis is an indication for pericardial drainage independently from the haemodynamic status. Surgical pericardial drainage is recommended to allow complete removal of the fluid and prevent its organization and progression to constriction. Low pericardial-to-serum glucose ratio (mean 0.3) and elevated pericardial fluid white cell count with a high proportion of neutrophils (mean cell count 2.8/mL, 92% neutrophils) differentiate purulent from tuberculous (glucose ratio 0.7, mean cell count 1.7/mL, 50% neutrophils) and neoplastic pericarditis (glucose ratio 0.8, mean cell count 3.3/mL, 55% neutrophils).

Fluid must be sent for bacterial, fungal, and tuberculous studies along with blood and tissue samples, as guided by the clinical presentation.¹

11.5.3. Therapy

Intravenous antimicrobial therapy should be started empirically until microbiological results are available. Afterwards, pathogen-directed antibiotic therapy is warranted based on antibiotic susceptibility.¹ The duration of antibiotic therapy should be individualized until fever and clinical signs resolve, with the minimum period of administration being 3 weeks.

Purulent effusions are often heavily loculated and likely to rapidly reaccumulate. Subxiphoid pericardiectomy and rinsing of the pericardial cavity should be considered.¹⁵ This allows more complete drainage of the effusion, since loculations can be manually lysed. Intrapericardial fibrinolysis is a possible treatment for cases of loculated effusions to achieve adequate drainage.⁶⁰⁹ Fibrinolysis has been shown to prevent complications in approximately 86% of cases without fatal complications.^{573,609,610} In the unfortunate case that percutaneous measures fail to control infection, and worsening HF occurs along with constrictive physiology features, referral to surgical pericardiectomy is advised.⁶¹⁰

Recommendation Table 23 — Recommendations for purulent pericarditis (see Evidence Table 23)

Recommendations	Class ^a	Level ^b
Urgent pericardiocentesis and/or a surgical window is recommended in patients with suspicion of purulent pericarditis to establish a diagnosis. ⁶⁰⁶	I	C
Intrapericardial fibrinolysis should be considered in patients with purulent pericarditis to allow complete drainage of purulent fluid and to prevent constriction. ^{573,610}	IIa	B

^aClass of recommendation.

^bLevel of evidence.

11.6. Incessant and recurrent pericarditis

The TF proposes to adopt the term ‘incessant’ for cases of persistent symptoms without clear remission, and thus also to include cases of symptom persistence/recurrence during drug tapering. Recognition of these cases is of paramount importance, since they can directly progress to CP within a few months.¹⁰⁴ Recurrent pericarditis is defined as a relapse after a documented first episode of AP, a symptom-free interval, complete discontinuation of anti-inflammatory therapy, and evidence of subsequent recurrence of pericarditis. Recurrence usually occurs within 18 months from the index episode, and is the most common and problematic complication of AP, ranging from 15% to 30% of cases after a first episode of pericarditis. It may increase to 50% after a first recurrence in patients with inadequate treatment of the first episode (e.g. too fast tapering, not treated with colchicine, treated with corticosteroids).^{25,611} In developed countries, the aetiology of recurrences is poorly known, and most cases are labelled as idiopathic. Historically, most cases were probably related to an autoinflammatory/autoimmune pathogenesis. This is based on the inflammatory/non-inflammatory phenotype, the latency from the acute attack (several weeks after the index episode), the presence of autoantibodies, and the response to anti-inflammatory/immunosuppressive treatments.^{52,283,284,287}

11.7. Inflammatory and non-inflammatory pericardial effusion

The normal pericardial sac contains 10–50 mL of pericardial fluid, a plasma ultrafiltrate that acts as a lubricant between the pericardial layers. Any pathological process that causes pericardial inflammation increases the amount of fluid, causing PEff (exudate). Alternative mechanisms causing PEff include decreased reabsorption following increased systemic venous pressure, as observed in congestive HF or pulmonary hypertension (transudate) or alternatively, decreased lymphatic drainage.⁶¹² The regimen of pressures in the epicardium and pericardial cavity is shown in [Supplementary data online, Figure S4](#).

11.7.1. Classification and aetiology

The reported incidence and prevalence of PEff in developed countries is estimated at 3% and 6%–9%, respectively, based on echocardiographic laboratory records.⁶¹³ Pericardial effusion was detected in 14% of subjects in a prospective registry of consecutive patients who underwent chest CT.¹⁹⁸

The classification of PEff is shown in [Table 10](#). Echocardiography provides semiquantitative assessment of the effusion size, which is useful for estimating the risk of having a non-idiopathic aetiology and complications (see [Supplementary data online, Figure S5](#)).¹⁰⁵ In the past three decades, six major surveys have been published on the characteristics of moderate to large PEff (see [Supplementary data online, Table S13](#)).^{556,614–618} According to these series, many cases remain idiopathic in developed countries (up to 50%), while additional aetiologies include cancer (10%–32%), infections (15%–30%), iatrogenic causes (15%–20%), and connective tissue diseases (5%–15%), whereas TB is the dominant cause in developing countries (>60%), where TB is endemic.⁵⁵⁸

11.7.2. Presentation

A significant proportion of patients with PEff are asymptomatic, and PEff is an incidental finding during routine examination. The clinical presentation of PEff varies according to the speed of accumulation of fluid (see [Supplementary data online, Figure S4](#)). Classic symptoms include exertional dyspnoea progressing to orthopnoea, chest pain, and feeling of fullness.

Additional symptoms due to the compression of adjacent structures include nausea (diaphragm), dysphagia (oesophagus), hoarseness (recurrent laryngeal nerve), and hiccups (phrenic nerve).^{118,619}

11.7.3. Diagnosis

Physical examination may be normal in patients without haemodynamic compromise. Echocardiography is the primary diagnostic tool for diagnosis, sizing, assessment of haemodynamic effects, and follow-up

(see [Supplementary data online, Figure S5](#)).^{115,124} Advanced imaging (CT and CMR) provides valuable information concerning local inflammation, masses, associated chest abnormalities (e.g. pectus excavatum), loculated effusions, and systemic diseases.^{196,198,620} Pericardial effusion is often associated with known or unknown medical conditions (e.g. hypothyroidism) in up to 60% of cases, especially if moderate/large.⁶¹⁵ A practical routine evaluation for the triage of PEff is presented in [Figure 19](#).¹

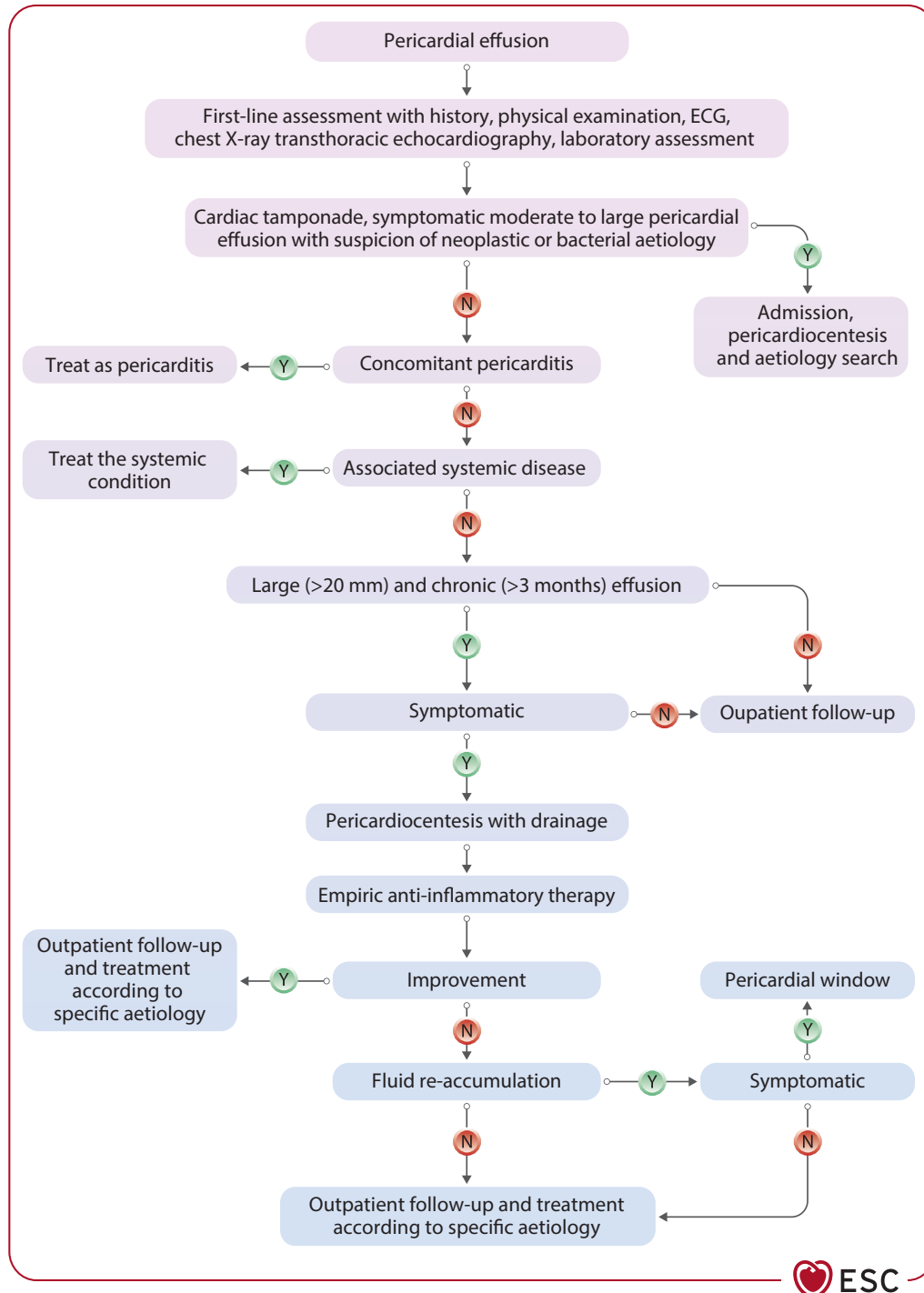


Figure 19 Triage and management of pericardial effusion. ECG, electrocardiogram; N, no; Y, yes.



Patients presenting with PEff without inflammatory marker elevation have an increased risk of a neoplastic aetiology (likelihood ratio 2.9).⁶¹⁵ In chronic effusions with no definite aetiology, and without inflammatory markers, empirical anti-inflammatory treatment is futile.^{1,621} In worsening large effusions without evidence of systemic inflammation, the exclusion of cancer with advanced imaging (mainly CT) is warranted.¹⁹⁶ C-reactive protein should be measured before pericardiocentesis, since it can increase after the procedure.⁶²² Notably, the classical Light criteria used for the classification of pleural effusions should not be applied to PEff due to the high rate of misclassification of fluids as exudates, since pericardial fluid is rich in mesothelial cells, proteins, albumin, and lactate dehydrogenase (LDH).^{623,624}

11.7.4. Therapy

The treatment of PEff is shown in [Figure 19](#). Therapy of PEff should be targeted at the aetiology, as much as possible. In the absence of pericardial inflammation (namely in the absence of C-reactive protein elevation and evidence of pericardial inflammation by an imaging technique) anti-inflammatory treatment is not recommended. According to recent data, the usefulness of pericardial drainage in asymptomatic or oligo-symptomatic, large, chronic, idiopathic effusions without evidence of pericarditis has been revised.^{49,621} Conservative treatment improves outcomes, the risk of CTP being only 2.2%/year without reported deaths.⁶²⁵ In addition, survival after recurrence or complications is significantly better in patients treated conservatively without interventions. Nevertheless, if during follow-up the PEff becomes symptomatic and haemodynamic impairment is observed by echocardiography, drainage is warranted.

11.7.5. Prognosis and follow-up

The prognosis of PEff is essentially related to its aetiology.⁶²⁶ Moderate to large effusions are more common for specific aetiologies.^{105,615} In general, PEff should be considered as a marker of the severity of the underlying disease.⁵⁸⁴ Small, idiopathic, asymptomatic PEff have an overall good prognosis with a very low risk of complications, although not all studies concur.⁶¹³ Those individuals should be reassured about the benign nature of the condition, and should not restrict their physical activity if C-reactive protein is normal.¹¹ The follow-up of PEff is mainly based on the evaluation of symptoms, using focused echocardiography to assess size changes, and haemodynamic issues, as well as C-reactive protein. Asymptomatic patients with mild idiopathic effusions do not generally require specific monitoring. In asymptomatic patients with at least moderate effusions, a reasonable follow-up is every 6 months, ideally in specialized centres. The latter patients should be instructed to seek medical advice in case of symptom appearance, such as dyspnoea or fatigue, and/or chest pain suggesting pericarditis.

11.8. Cardiac tamponade

Cardiac tamponade is a pericardial syndrome occurring when PEff impairs diastolic filling of the heart until cardiac output is reduced. The size of the effusion as well as its distribution may vary. Since the pericardium is relatively stiff, if pericardial fluid collects quickly, such as in haemopericardium, the limit of pericardial stretching is reached quickly with volumes of 200–300 mL. In contrast, slowly accumulating PEff may reach 1 to 2 L before the development of CTP ([Supplementary data online, Figure S4](#)). This pathophysiology explains that CTP is a last-drop phenomenon. Thus, a small increase of pericardial volume may precipitate the

syndrome, and the aspiration of small amounts of pericardial fluid with pericardiocentesis may greatly improve the clinical condition.¹¹⁸

Pericardial effusions are usually circumferential, but after trauma or cardiac surgery, they may be loculated and even be responsible for localized compression and the development of CTP.

11.8.1. Presentation

Beck identified a triad of signs, consisting of hypotension, increased JVP, and quiet heart sounds as presenting symptoms.^{118,619}

This triad was classically identified in 'surgical tamponade' with acute CTP due to intrapericardial haemorrhage because of trauma, or myocardial/aortic rupture. Beck's triad may be lacking in patients with 'medical tamponade' with slowly accumulating pericardial fluid. Acute CTP is usually associated with tachycardia and low blood pressure (<90 mmHg) that is only slightly reduced in subacute, chronic tamponade.^{118,619} On physical examination, classical signs include neck vein distention with elevated JVP, pulsus paradoxus, and diminished heart sounds. Pulsus paradoxus is defined as an inspiratory reduction of the systolic blood pressure by at least 10 mmHg.^{118,619} Pulsus paradoxus is due to exaggerated ventricular interdependence occurring in CTP, when the overall volume of ventricles becomes unable to expand, and any change in the volume on one side of the heart causes opposite changes on the other side. On ECG, the patient usually shows tachycardia, low QRS voltages, and electrical alternans due to the damping effect of pericardial fluid and swinging heart.^{118,619}

11.8.2. Aetiology and diagnosis

Cardiac tamponade shares the same causes of PEff. In clinical practice, the most common aetiologies include cancer, TB, purulent infections, trauma, iatrogenic complications of cardiovascular interventions (e.g. ablation of arrhythmias, device implantation, PCIS), acute aortic disease, systemic inflammatory diseases, and renal failure.¹¹⁸ In the setting of AP with a viral or idiopathic aetiology, CTP is rare (1%–2% of cases) and is more common with pericarditis associated with a non-idiopathic aetiology (20%).³⁴⁷ The diagnosis of CTP is a clinical diagnosis based on the combination of a suggestive history, symptoms, signs, and imaging confirmation by echocardiography ([Table 17](#)).¹¹⁸

Table 17 Echocardiographic signs of cardiac tamponade

Echocardiographic feature	Sensitivity	Specificity
Large pericardial effusion with swinging heart	n.a.	n.a.
Diastolic collapse of the RA	50%–100%	33%–100%
Duration of diastolic collapse of the RA as a ratio of the cardiac cycle length >0.34	>90%	100%
Diastolic collapse of the RV	48%–100%	72%–100%
Respiratory changes of the mitral E velocity >25%–30%, tricuspid E velocity >40%–60%	n.a.	n.a.
Inferior vena cava plethora (dilatation >20 mm and <50% reduction of diameter with respiratory phases), as well as hepatic vein dilatation	97%	40%

n.a., not available; RA, right atrium, RV, right ventricle.

The diagnosis of CTP identifies high-risk patients with an increased risk of complications during follow-up and a high probability of a non-viral aetiology. The patients should be admitted for therapy and monitoring.^{1,105}

The definitive therapy is pericardiocentesis, which should be performed urgently according to the clinical presentation.

11.8.3. Therapy

The treatment for CTP is drainage of the pericardial fluid, preferably by needle pericardiocentesis with the use of echocardiographic or fluoroscopic guidance, and should be performed without delay in unstable patients. Alternatively, drainage is performed by a surgical approach, especially in situations such as purulent pericarditis, or urgent situations with bleeding into the pericardium.

Pericardiocentesis should be performed by experienced operators trained/certified in acute cardiovascular care and carries a variable risk of complications from 4% to 10%, depending on type of monitoring, operator's skill, and setting (emergent vs urgent vs elective). The most common complications include arrhythmias, coronary artery or cardiac chamber puncture, haemothorax, pneumothorax, pneumopericardium, and hepatic injury.¹ Mechanical ventilation with positive airway pressure should be avoided in CTP. In addition, diuretic therapy should be avoided, and temporary fluid administration can be helpful to stabilize the patient while waiting for urgent pericardiocentesis.

11.8.4. Outcomes and prognosis

The prognosis of CTP is essentially related to its aetiology. Cardiac tamponade in patients with cancer and metastatic involvement of the pericardium has a bad short-term prognosis, since this is a sign of advanced disease. In contrast, patients with CTP and a final diagnosis of idiopathic pericarditis generally have a good long-term prognosis.^{1,105}

11.9. Pericardial constriction and constrictive pericarditis (calcified and non-calcified)

11.9.1. Introduction

Pericardial constriction is a chronic condition usually characterized by a thickened, fibrotic, and often calcified pericardium that leads to impaired diastolic filling of the heart. Constrictive pericarditis is

constriction associated with pericarditis.^{114,119,347} There is a high risk of progression in bacterial pericarditis (20%–30%), especially purulent pericarditis, intermediate risk in immune-mediated pericarditis and neoplastic pericardial diseases (2%–5%), and a low risk in viral and idiopathic pericarditis (<1%).³⁴⁷ Cases of CP after pericardiectomy have been reported, especially after partial pericardiectomy.^{627–630} In developed countries, the most common reported causes are: viral or idiopathic (42%–49%); post-cardiac surgery (11%–37%); post-radiation therapy, mostly for breast cancer or Hodgkin's disease (9%–31%); connective tissue disorders (3%–7%); post-infectious causes (purulent pericarditis or TB in 3%–6%); and miscellaneous causes (<10%). TB is a major cause of CP in developing countries.^{630,631}

11.9.2. Presentation

The classical clinical presentation comprises signs and symptoms of right HF with preserved biventricular function without previous or concomitant myocardial disease. Subacute/chronic inflammatory pericarditis can evolve into CP, and the duration of progression from initial pericardial inflammation and the onset of constriction is variable.³⁴⁷ Systolic dysfunction due to myocardial fibrosis or atrophy can aggravate the haemodynamic impairment in more advanced cases.

In up to 20% of cases, constriction might be present with normal pericardial thickness, while advanced and classic cases demonstrate prominent pericardial thickening and calcifications.¹¹⁹

11.9.3. Diagnosis

The diagnosis is made by multimodality imaging methods, such as echocardiography, CT, and CMR (Figure 13). Cardiac catheterization should be considered only if non-invasive multimodality imaging methods are inconclusive.^{115,124,632,633} The Mayo Clinic has proposed specific diagnostic criteria, based on echocardiography to diagnose CP, that have been confirmed by other centres. They include the presence of septal bounce or ventricular septal shift with either medial e' of >8 cm/s or hepatic vein expiratory diastolic reversal ratio of >0.78 (sensitivity 87%, specificity 91%; specificity may increase to 97% if all criteria are present with a corresponding decrease of sensitivity to 64%). In addition, respirophasic variation E-wave mitral inflow of >25%/tricuspid inflow of >40% can be recorded in these patients^{632,634} (see [Supplementary data online, Figures S1, S5, and Table S14](#)). The main reported constrictive syndromes are shown in [Table 18](#).

Table 18 Definitions and therapy of main constrictive pericardial syndromes

Syndrome	Definition	Therapy
Transient constriction (d.d. permanent constrictive pericarditis, restrictive CMP)	Reversible pattern of constriction following spontaneous recovery or anti-inflammatory therapy	A 3–6 month course of empirical anti-inflammatory medical therapy
Effusive–constrictive pericarditis (d.d. cardiac tamponade, constrictive pericarditis)	Failure of the right atrial pressure to fall by 50% or to a level <10 mmHg after pericardiocentesis May be diagnosed also by non-invasive imaging	Pericardiocentesis followed by medical therapy Surgery for persistent cases
Chronic constriction (d.d. transient constriction, restrictive CMP)	Persistent constriction after 3–6 months	Radical pericardiectomy, medical therapy for advanced cases or high risk of surgery or mixed forms with myocardial involvement

CMP, cardiomyopathy; d.d., differential diagnosis.

11.9.4. Therapy

Medical therapy is considered for specific aetiologies, such as TB, to prevent progression to constriction.⁵⁵⁸ Antituberculosis drugs may significantly reduce the risk of constriction from >80% to <10%.⁵⁶⁹ Anti-inflammatory therapy may help to resolve transient constriction in 10%–20% of cases of AP.^{121,122} In such cases, to identify patients with potentially reversible forms of constriction, pericarditis should be excluded by testing markers of inflammation (e.g. C-reactive protein) or looking for imaging evidence of pericardial inflammation (e.g. pericardial oedema and/or LGE on CMR).

In advanced cases, medical therapy is supportive of controlling symptoms of congestion, but surgery should never be delayed to improve outcomes.

Pericardiectomy is the standard therapy for symptomatic chronic constriction without inflammation or not responding to anti-inflammatory therapy (see Section 6.4.2). For milder disease or more advanced disease, or for those with radiation-induced disease, reduced EF, or advanced renal disease, caution is necessary. Radical pericardiectomy rather than anterior phrenic-to-phrenic pericardiectomy is warranted for the best outcomes.^{311,635–637}

In general, pericardiectomy has been seen as a high-risk surgery with operative mortality of 6%–10%. However, recent studies show better results for early surgery in high-volume centres. The risk is related to the aetiologies and other comorbidities. Idiopathic causes have the lowest risk of <1.5%.^{638–640}

Recommendation Table 24 — Recommendations for constrictive pericarditis (see Evidence Table 24)

Recommendations	Class ^a	Level ^b
Diagnosis		
Multimodality imaging is recommended in all patients with suspected constrictive pericarditis to make the diagnosis and assess pericardial thickening, calcifications, and active inflammation. ⁶³²	I	C
Cardiac catheterization for haemodynamic assessment should be considered in patients with suspected constrictive pericarditis when multimodality imaging is inconclusive. ⁶³³	Ila	C
Therapy		
Anti-inflammatory therapy is recommended in haemodynamically stable patients with a transient or new diagnosis of constriction with concomitant evidence of pericardial inflammation ^c to prevent progression to constriction and avoid pericardiectomy. ^{122,123}	I	C
Pericardiectomy is recommended in patients with permanent constriction if there is no active inflammation or anti-inflammatory treatment is not successful after 3–6 months. ^{635,636}	I	C

CMR, cardiovascular magnetic resonance.

^aClass of recommendation.

^bLevel of evidence.

^ci.e. C-reactive protein elevation or pericardial enhancement on CMR.

11.10. Effusive–constrictive pericarditis

11.10.1. Introduction

In ECP, pericardial fluid is present, and the scarred pericardium puts pericardial fluid under increased pressure, constricts the cardiac volumes, and leads to signs of CTP.^{116,117} Classically it is defined haemodynamically as failure of the RAP to fall by 50% or to a level below 10 mmHg after pericardiocentesis.¹¹⁷ Modern multimodality imaging allows a non-invasive diagnosis without cardiac catheterization.

11.10.2. Aetiology

Limited data have been published on ECP, and it appears to be a common condition in developing countries.¹¹⁷ Idiopathic cases are most commonly found in developed countries, while TB appears to be the most common cause in developing countries. The other reported causes are neoplasia, radiation, chemotherapy, infections (mainly TB and purulent type), and post-surgical pericardial disease.⁶⁴¹

11.10.3. Presentation

Clinical features of either CP or CTP, or sometimes both, are typically present in patients with ECP. In patients who appear to have uncomplicated CTP, the diagnosis usually becomes evident during pericardiocentesis.¹¹⁷ Tricuspid regurgitation or right HF may cause persistently elevated RAP after efficient pericardiocentesis.

11.10.4. Diagnosis

To diagnose ECP, non-invasive imaging may be valuable.⁶⁴¹ Thickening of the epicardial–pericardial layer is responsible for the constrictive component. After pericardiocentesis for CTP, careful detection of constriction on Doppler findings can be reported.¹²⁴ Without haemodynamic monitoring, ECP can also be suspected on echocardiography and CMR (see Supplementary data online, Table S14). Cardiovascular magnetic resonance may provide helpful information, especially in differentiating constriction from RCM (Table S14). An accurate evaluation of ventricular interdependence and septal bounce can be made by assessing ventricular coupling with echocardiography and/or real-time cine CMR.¹¹⁵ Echo-Doppler findings indicating effusive constriction may be detected prior to pericardiocentesis.^{116,124} Currently, the diagnosis can be made using multimodality imaging without cardiac catheterization.

11.10.5. Treatment

Effusive constriction can often resolve spontaneously or be treated with anti-inflammatory therapies in the case of evidence of transient constriction.⁶⁴¹ In resistant cases, visceral pericardiectomy must be performed, since the epicardial layer is responsible for constricting the heart. The visceral component of pericardiectomy requires sharp dissection of many small fragments until ventricular motion is improved. Only pericardial centres with experience and competency should perform pericardiectomy for CP.

12. Age- and sex-related aspects in inflammatory myopericardial syndrome

12.1. Sex distribution

Acute myocarditis is more prevalent in males (75%–84%).^{17,28,73,78,642} On the contrary, the male-to-female ratio is similar in fulminant cases (46% females).^{56,75,643} Sex differences in pericarditis are less evident,

with some studies showing a mild prevalence in males of 59% in AP.³⁷ Males aged 16–65 years are at higher risk of pericarditis (relative risk 2.02) than females. On the other hand, the probability of pericarditis recurrence is higher in females (HR 1.67), probably due to the higher frequency of specific causes (e.g. autoimmune diseases).¹⁰⁵

12.2. Paediatric patients

12.2.1. Myocarditis

The annual incidence of myocarditis during childhood is between 1 and 2 cases per 100 000 children.^{21,644,645} In children <6 years of age, the sex distribution was balanced, 50% each,²⁰ but boys had a significantly higher incidence at ages 6 to 15 years.²¹

The proposed diagnostic approach in adults applies also for children, including CMR (e.g. in the MYKKE registry).⁶⁴⁶

There are conflicting data regarding the complication rates of EMB in children, with some studies reporting similar incidence of complications as in adults, both around 5%, mainly from RV sampling.^{40,63} Particular care should be taken in children aged <1 year and in the case of LV biopsies with reported complication rates up to 30%.²¹³

In particular, very young children are predisposed to severe myocarditis. Critically ill children admitted to the intensive care unit (ICU) mostly survived, if receiving high-resource therapies, including MCS.⁶⁴⁷ In a prospective multicentre registry it was shown that in acute HF and FM, MCS including VAD improved survival.⁶⁴⁸ Similar results have also been reported from Japan.⁶⁴⁹

In infants, enteroviruses, such as Coxsackievirus, were found more commonly than in adults.⁶⁴⁹ A presumed viral aetiology was identified in 11%–50%,^{40,63} with a death or HT rate of 2%, similar to adults.²¹ In biopsy-proven myocarditis, the HT rate rises to 7%, and the mortality rate increases to 4%–6%.⁴⁰

Therapy for myocarditis in children is not well defined. In a meta-analysis evaluating corticosteroids, no mortality reduction was observed, but a significant improvement in LVEF was reached with the use of steroids in other studies.^{650–652} In a meta-analysis evaluating IVIG,⁶²⁸ treatment was not associated with better survival. This was also supported by a prospective trial⁶⁵³ and a multicentre cohort study.⁶⁵⁴ On the contrary, another meta-analysis⁶⁵⁵ in FM concluded that IVIG therapy (usually 1–2 g/kg over 24–48 h) significantly reduced in-hospital mortality and improved LVEF.

Genetic evaluation might help in the future in differentiating subsets of children and tailoring therapies.⁹³

12.2.2. Pericarditis

In children aged 12 years or less, the incidence of AP was 2.8/100 000 in a population study from 2009 to 2021.⁶⁴⁴ The diagnostic criteria (see [Table 4](#)), aetiologies, and risk of recurrences (see [Tables S2](#) and [S3](#)) are similar to those reported in adults (see [Supplementary data online, Table S1](#)). Most paediatric cases of pericarditis are related to PPS, particularly after atrial septal defect closure. Compared with adults, children more commonly have an inflammatory phenotype.⁶⁵⁶ Non-steroidal anti-inflammatory drugs remain the mainstay of therapy at high dosages (see [Supplementary data online, Table S15](#)). Most paediatricians avoid aspirin. Colchicine halved recurrences in children, similarly as for adults.^{656,657}

The use of corticosteroids should be restricted even more than in adults, given that their side effects (including striae rubrae and growth impairment) are particularly deleterious in growing children. Anti-interleukin-1 agents have been used for the first time in children with autoinflammatory diseases and then adopted for RP in them, representing a new therapeutic option, especially if they are corticosteroid-dependent. However, it is

often difficult to withdraw these drugs when clinical remission is achieved; for instance, in one study only 15% of children were able to stop anti-IL-1 agents after a mean follow-up of 2.6 years.⁶⁵⁸ Few paediatric patients were enrolled in RCTs testing anakinra and rilonacept.^{283,284}

12.3. Pregnancy, lactation, and reproductive issues

There is very limited published evidence on this topic. There are only case reports for myocarditis,^{659–663} and one case series describing pregnant women with RP.⁶⁶⁴ Pregnancy-associated myocarditis is described in [Section 9.7](#). Pericardial effusion is the most common manifestation of pericardial diseases during pregnancy. Effusions during pregnancy are typically benign, mild or moderate, and well tolerated, with spontaneous resolution after delivery, and no specific treatment is required in such cases. However, PEff may be associated with pre-eclampsia.⁶⁶⁵ Acute pericarditis is the second most common condition. Pre-conception counselling is essential in women of childbearing age with RP or previous myocarditis. In such cases, pregnancy should be planned in a phase of disease remission, and therapy should be reviewed. Pre-conception assessment should include multidisciplinary evaluation. Echocardiography is the preferred imaging method, while X-ray, CT scan, and CMR can be used in selected cases.⁶⁶⁶

In patients with IMPS, vaginal delivery is not excluded in uncomplicated cases, while Caesarean section may be required in the presence of haemodynamic instability.⁶⁶⁶ Appropriate follow-up with a multidisciplinary team with experience in the field is recommended throughout pregnancy to ensure good maternal and foetal outcomes.

High-dose aspirin or NSAIDs, such as ibuprofen and indomethacin, can be used up to the 20th week of gestation. Corticosteroids at the minimal effective dose can be given in patients with active pericarditis throughout pregnancy along with NSAIDs and in selected cases colchicine. Azathioprine and IVIG are compatible with pregnancy and breastfeeding. All these medications, apart from high-dose aspirin, may be used during lactation. Colchicine is compatible with pregnancy and breastfeeding, and it can be continued throughout pregnancy to prevent recurrences.^{664,667–669} The use of IL-1 blockers during pregnancy is controversial. Available literature data seem encouraging; however, the relevant studies are scant and retrospective. Despite the limited evidence, anakinra may be continued through conception, pregnancy, and lactation in women with rheumatic and musculoskeletal diseases who are not able to use alternative therapies.^{668–670} More details regarding drug dosages can be found in [Supplementary data online, Table S16](#).

There are no specific limitations for men with pericarditis who are planning to have children because they can safely continue therapy.^{667,668}

Recommendation Table 25 — Recommendations for pregnancy, lactation, and reproductive issues (see [Evidence Table 25](#))

Recommendations	Class ^a	Level ^b
Pre-conception counselling is recommended in women with recurrent pericarditis or myocarditis to assess disease activity and to review therapy.	I	C
NSAIDs should be considered in pregnant patients with pericarditis until the 20th week to treat an incessant/recurrent course. ⁶⁶⁴	IIa	C

Continued

Anti-inflammatory therapies should be considered in patients with pericarditis during lactation to treat and prevent pericarditis with timing adjusted to reduce drug exposure of the breastfed infant.	IIa	C
During pregnancy and breastfeeding, corticosteroids at the minimal effective dose (preferably up to 20 mg prednisone daily) should be considered in patients with active pericarditis, despite NSAID (if feasible), to prevent an incessant/recurrent course. ⁶⁶⁴	IIa	C
Colchicine may be considered in pregnant patients with pericarditis, especially in patients already receiving this drug to prevent recurrences.	IIb	C
Anakinra may be considered through pregnancy and lactation in pregnant patients with recurrent pericarditis who are not able to use alternative therapies to prevent an incessant/recurrent course.	IIb	C

© ESC 2025

NSAID, non-steroidal anti-inflammatory drug.
^aClass of recommendation.
^bLevel of evidence.

12.4. The elderly

Myocarditis is more prevalent in young people, with a median age between 20 and 40 years.^{28,55,63,73} In a Swedish study, 64% patients were younger than 50 years of age. In this study, HF/DCM and deaths occurred more commonly in patients aged >50 years.¹⁷ Myocarditis is probably more commonly related to drugs in the elderly, e.g. ICLs^{28,495} and clozapine.⁵⁰⁸ Age- and sex-based differences have been evaluated in two studies with AP, and one study with RP.^{45,102,671} In these studies, elderly patients less often had chest pain, fever, ST elevation, and PR depression. They had lower C-reactive protein values but dyspnoea, AF, and PEff were more common. Moreover, they received glucocorticoids more commonly, and had a lower risk of recurrences compared with younger patients. In the elderly, therapy compliance may be problematic, because of cognitive impairment and comorbidities, but the strongest predictor of non-adherence is the number of medications.⁶⁷² Non-steroidal anti-inflammatory drugs should be used cautiously; dosing should be adapted (e.g. colchicine dose should be halved in some cases), and attention should be paid to evaluate renal impairment and drug interactions.

12.5. Physical activity in inflammatory myopericardial syndrome

Patients with active IMPS are advised to restrict physical activity. It has been proposed that exercise can aggravate myocardial and pericardial inflammation through several mechanisms, including a tachycardia-mediated process. The importance of controlling heart rate is confirmed by observational studies, in which the empirical use of β-blockers to control heart rate in patients with pericarditis improved symptom control.²⁷⁴ Previous recommendations have made distinctions between athletes and non-athletes, providing arbitrary times for abstinence from 3 to 6 months. This TF recommends an individualized approach, based on remission times. A complete clinical remission should be considered in athletes/non-athletes with normalization of symptoms, biomarkers, and imaging.

During the acute stage of myocarditis, patients are advised to rest completely, since exercise has been associated with arrhythmias and

SCD. To ensure resolution of the disease, recovery should be monitored, including clinical assessment, rhythm control, laboratory analysis, and multimodality imaging (see [Table 15](#)). A personalized prescription of exercise should be performed, based on the patient (athletes, non-athletes), and type of exercise.

12.5.1. Mental health effect of restricting exercise

Exercise restriction can affect patient mental health, especially in children and young adults. It can lead to frustration, sadness, and depression in patients. Freedom to exercise should be approached with shared decision-making, taking into account the risk vs benefit ratio in the single case.

Recommendation Table 26 — Recommendations for physical activity and myocarditis/pericarditis (see Evidence Table 26)

Recommendation	Class ^a	Level ^b
Restriction of physical exercise until remission, for at least 1 month, is recommended in athletes and non-athletes after IMPS using an individualized approach to accelerate recovery.	I	C

IMPS, inflammatory myopericardial syndrome.
^aClass of recommendation.
^bLevel of evidence.

Downloaded from https://academic.oup.com/eurheartj/article/46/40/3952/18234483 by guest on 13 April 2026 © ESC 2025

12.6. Multidisciplinary teams for the management of inflammatory myopericardial syndrome

It is recommended to have a multidisciplinary team for high-risk cases with IMPS. The team should be composed of a clinical cardiologist, a CMR imaging specialist with expertise in IMPS, a pathologist with expertise in cardiovascular diseases, and additionally, depending on the case, a rheumatologist (or clinical immunologist), an infectious disease specialist, a geneticist (or a cardiologist with expertise in genetics), interventional cardiologists (including electrophysiologists), and a cardiac intensive care specialist. A cardiac surgeon might be involved subsequently when interventional or surgical decisions are anticipated. More details are given in [Figure 20](#). It is of paramount importance that physicians develop competence and skills in IMPS to allow timely diagnosis and therapy for patients, since mixed forms are common in clinical practice. Patient involvement is important, particularly when the evidence is scarce to foster shared decision-making.^{375,673,674}

Recommendation Table 27 — Recommendations for multidisciplinary teams in myopericardial syndromes (see Evidence Table 27)

Recommendations	Class ^a	Level ^b
A multidisciplinary team discussion at a referral centre is recommended in patients with high-risk/complicated IMPS to provide a patient-tailored approach. ^{375,673}	I	C

IMPS, inflammatory myopericardial syndrome.
^aClass of recommendation.
^bLevel of evidence.

© ESC 2025

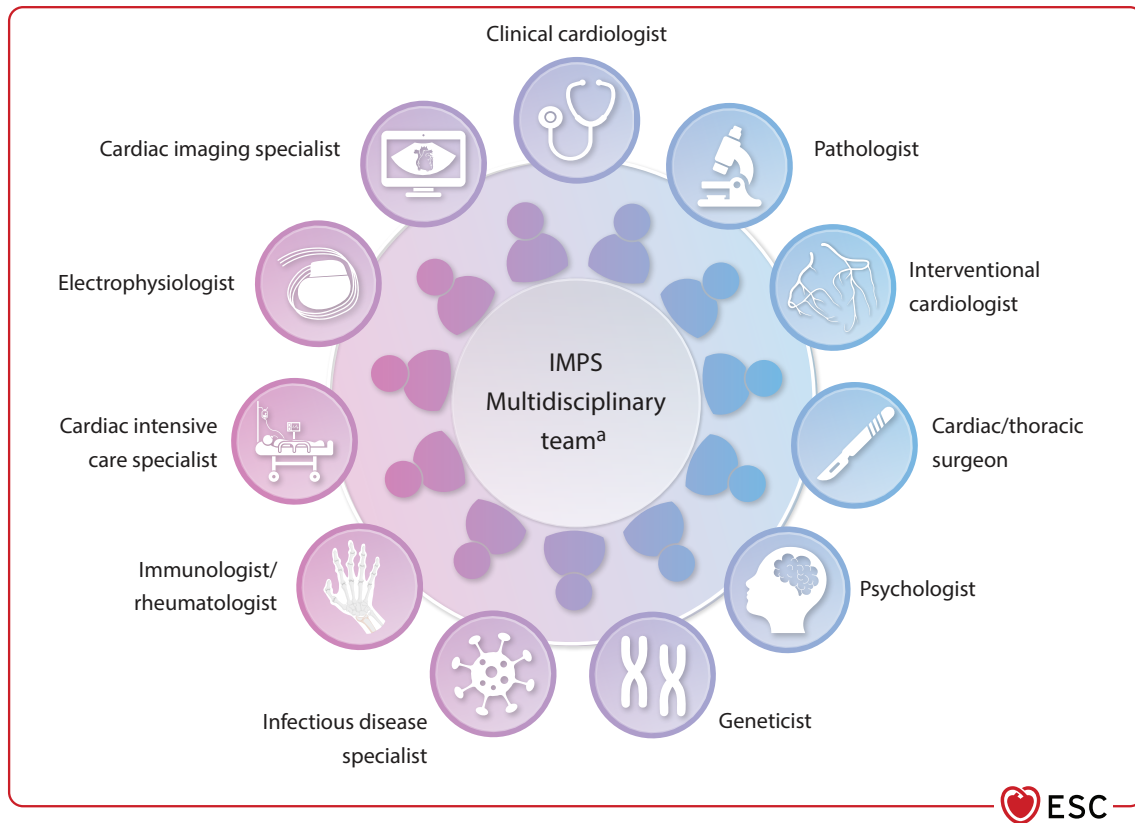


Figure 20 Multidisciplinary teams for inflammatory myopericardial syndrome. ^aFull team—tailored to the specific case.

13. Advice for patients

Specific patient education is mandatory for patients with IMPS. Advice should address the causes, rationale for treatment, possible complications, and outcomes. Inflammatory myopericardial syndrome affects young patients and may severely affect their quality of life. Specific advice should be provided on the need for rest during the acute phase of the disease, and the timing for return to physical activity and work, as well as benefits and risks associated with tailored immunosuppressive/immunomodulatory therapies, and when to contact the multidisciplinary team. Advice must be tailored to the specific social situation. Suitable language should be used, recognizing the patient's educational status. Clarification based on images is preferable. Care should be taken not to aggravate anxiety unnecessarily. An additional description and advice for patients with IMPS is provided in [Supplementary data online, Section 8, Figure S6, and Table S17](#). A separate document dedicated to patients has been developed.

14. Tertiary referral centres for inflammatory myopericardial syndrome: feature and volume of activity

14.1. Tertiary care centres

Tertiary care centres of excellence are extensive, renowned healthcare facilities that house specialized cardiology departments equipped to

manage patients with IMPS. Leading institutions are recognized for their cardiovascular expertise and often handle patients with complex disease.⁶⁷⁴ Such centres have significant expertise in the diagnosis and therapy of myocarditis and pericarditis and are actively involved in research. They should be the referral centre of choice for complicated cases that cannot be managed by regional centres. Endomyocardial biopsy referral centres for deep investigation of EMB samples, including immunochemistry and molecular testing, should be identified at regional or national level.

14.2. Inflammatory myopericardial syndrome in regional centres

Most uncomplicated cases can be handled by regional centres, and depending on the healthcare systems, in outpatient departments. However, the crucial factor is the local expertise. At the same time, those with more severe pericarditis or myocarditis might need treatment at a hospital or tertiary care referral centre that has advanced multimodality imaging capacity and access to new therapeutic agents.⁶⁷⁴

14.3. Hub-and-spoke model

These centres should be capable of managing all care levels and adopt a hub-and-spoke model. Regardless of where care is provided, the goal is to sustain communication and collaboration throughout all healthcare system levels. The hub-and-spoke model aims to ease patient access to suitable care levels, promote care co-ordination, and drive quality enhancement for all patients with IMPS.^{674,675}

14.4. Teamwork, competencies, and advances in imaging techniques

Building a contemporary multidisciplinary team requires knowledge of recent advancements in imaging techniques, as well as evidence-based strategies for drug, interventional, and surgical therapies.^{63,674–676}

The conventional organization of academic or practice departments often operates in isolation, hindering the requirements of diseases that demand the insights and skills of a diverse expert panel. These centres should endorse a comprehensive team setup that encourages regular, ongoing communication among all members. The role of physician-led vs nurse-led tertiary centres should be explored further^{674,675} in view of the increasing number and complexity of these patients, and the utility of monitoring inflammatory markers and serial monitoring of cardiac imaging, even in an outpatient setting.

15. Key messages

The recognition of the whole spectrum of IMPS is increasing within the medical community. This is based on a deeper understanding leading to a more systematic evaluation, as well as more data being generated by prospective trials. Although these entities have been explored for some time, the COVID-19 pandemic was the main trigger to increase the awareness on the spectrum of disease. Advanced multimodality imaging technologies, including CMR, allow a patient-tailored diagnostic and therapeutic approach. A major diagnostic paradigm change is the capability of reaching a clinical diagnosis of certainty by non-invasive multimodality imaging (CMR for myocarditis), while EMB remains important in selected intermediate- and high-risk cases, if a targeted specific therapy, based on specific histotypes or aetiologies, is needed.

15.1. Aetiology

Inflammatory myopericardial syndrome is a spectrum of inflammatory diseases with some common aetiologies, either infectious or non-infectious, that can affect either the myocardium (myocarditis) or pericardium (pericarditis) in isolated forms, or combined (myopericarditis and perimyocarditis).

15.2. Clinical presentation and diagnosis

In a large percentage of cases, myocarditis and pericarditis have a chest pain presentation, and generally preserved biventricular function with good outcomes. For myocarditis, complicated forms include those presenting with severe HF and arrhythmias. Nevertheless, uncomplicated presentations may also develop life-threatening complications, albeit less commonly, and therefore also may need fast management. For pericarditis, complicated cases include those with an incessant or recurrent course. Many cases with persistent symptoms may show constrictive physiology, which can be reversible after appropriate medical therapy. The diagnosis of non-high-risk cases is based on clinical evaluation, including ECG and biomarkers, with non-invasive confirmation of the clinical suspicion by evidence of inflammatory involvement using multimodality imaging (mainly echocardiography and CMR). Endomyocardial biopsy is recommended for intermediate- and high-risk cases on a case-by-case decision, only when results are expected to change management.

15.3. Therapy

The treatment of uncomplicated IMPS is empirical, aiming at the control of symptoms and prevention of complications. Anti-inflammatory

drugs and colchicine are useful to control chest pain, while additional therapies should be guideline-directed for specific complicated courses. If a specific aetiology is identified, treatment should be targeted at the specific cause. In all cases of IMPS, restriction of physical activity is recommended in the acute phase, while return to work and physical activity should be individualized according to clinical remission times.

15.4. Prognosis and outcomes

The prognosis of IMPS varies. Most patients presenting with chest pain have a favourable outcome, although recurrences, especially for pericarditis, may severely affect the quality of life of patients and require long-term follow-up. For complicated cases of myocarditis with HF and arrhythmias, a tailored and individualized approach is warranted. Such patients require long-term follow-up, usually lifetime monitoring.

15.5. Multidisciplinary team

Management of patients with IMPS should usually be guided by a multidisciplinary team, which should be tailored to the specific patient. This team should be composed of different clinicians, all with expertise in cardiovascular diseases (e.g. imaging experts, a pathologist, a rheumatologist, an infectious disease specialist, a geneticist, interventional cardiologists, intensive care specialists, and surgeons). It is of paramount importance that physicians develop competence and skills either in myocarditis or pericarditis to allow timely diagnosis and therapy for patients, because mixed forms are common in clinical practice.

16. Gaps in evidence

The field of IMPS has significant knowledge gaps across all aspects, from pathogenesis to therapy. However, growing awareness has led to numerous ongoing studies. Advances in multimodality imaging have enabled a more comprehensive and non-invasive understanding of disease progression, opening the way to patient-tailored approaches. Despite these advancements, large-scale prospective multicentre trials with predefined outcome measures are lacking. These uncertainties are especially pronounced in chronic conditions, as well as in specific patient groups, such as children, women of childbearing age, during pregnancy, lactating women, and in the elderly.

A further challenge is the handling of the return to work and physical activity as there is a need for a patient-specific approach, taking into consideration the individual risk. Lessons learned from other diseases should lead to less restrictive guidance in comparison with previous advice.

16.1. Myocarditis

Knowledge about myocarditis has evolved during recent years, as the different mechanisms are better understood. Several causes, such as viral and toxic ones, including chemotherapy, as well as systemic disorders, have been investigated, and targeted therapeutic approaches were proposed. However, further research into specific therapy is needed based on advanced diagnostic approaches.

Nevertheless, a specific challenge for myocarditis is related to the low frequency of complications and the high rate of spontaneous remission. On this basis, clinical trials on medical therapy for myocarditis might be currently underpowered to assess the clinical benefit of a specific treatment with small sample sizes. In addition, many antiviral therapies are off-label for myocarditis and controlled trials are missing.

Currently, quantitative immunohistochemistry criteria for the diagnosis of LM are under discussion among cardio-pathologists to present more definite criteria for EMB.

Furthermore, a better understanding of the pathogenic and prognostic role of viral loads is needed (e.g. active/causative vs latent/innocent bystanders in cardiac viral infections).

Moreover, the role of genetic predisposition in recurrent myocarditis is not thoroughly clarified. Research into the role of genetic predisposition is evolving to change the classification of disease and may influence therapeutic pathways in the future. An increase of 'overlapping' conditions, especially DCM and ARVC, can be expected and may change our understanding of the disease in the future.

That means, more research is warranted on the prognosis and SCD risk stratification.

16.2. Pericarditis

There are significant knowledge gaps in individualized treatment and pathogenesis of various types of pericarditis, as well as the understanding of the interaction among genetic background, inflammation, and autoimmune mechanisms. Better knowledge of the pathogenesis of recurrences may also help to develop more targeted and individualized therapies.

The genetic background requires further evaluation in complicated, recurrent cases and could be helpful to elucidate the mechanisms leading to incessant/recurrent forms. New therapeutic options should also be considered and evaluated in clinical trials to explore new drugs for more complicated, incessant, or recurrent cases to develop a more individualized and efficacious approach for the treatment of pericarditis.

A significant management issue is the treatment of patients not responding to colchicine and anti-IL-1 agents, as well as the causes of drug dependence to maintain stable clinical remission, such as for corticosteroids and anti-IL-1 agents.

Additional research is also warranted to understand the prognostic significance of persistent LGE of the pericardium.

There are limited data to support the best timing of return to work and physical activity, and further research is needed on this topic with appropriate clinical trials or observational studies.

17. Sex differences

There is limited published evidence on this topic. Inflammatory myopericardial syndrome seems to affect males more than females from a young age. Myocarditis complicated by VA is more common in males, while in females, a relatively higher proportion of cases presents with complicated forms compared with males, and systemic autoimmune disorders are more commonly diagnosed. This was addressed in the relevant sections. The diagnostic approaches are similar, but care should be taken when applying normal values, especially in imaging. Medication should be adapted in women of childbearing age, pregnancy, and during lactation (more details are specified in specific sections).

18. 'What to do' and 'What not to do' messages from the Guidelines

Table 19 lists all Class I and Class III recommendations from the text alongside their level of evidence.

Table 19 'What to do' and 'What not to do'

Recommendations	Class ^a	Level ^b
Recommendations for clinical evaluation of myocarditis and pericarditis		
Complete clinical evaluation, including history, physical examination, chest X-ray, biomarkers, ECG, and echocardiography is recommended in all patients with a suspicion of myocarditis and/or pericarditis for the initial diagnostic assessment.	I	C
CMR is recommended in patients with the clinical suspicion of myocarditis (using updated LL criteria) and/or pericarditis for the non-invasive diagnosis of inflammatory reaction.	I	B
Hospital admission is recommended for patients with high-risk pericarditis for monitoring and treatment.	I	B
Hospital admission is recommended for patients with moderate- to high-risk myocarditis for monitoring and treatment.	I	C
EMB is recommended in patients with high-risk myocarditis and/or haemodynamic instability, and/or in patients with intermediate-risk myocarditis not responding to conventional therapy in order to detect a specific histologic subtype and to assess the presence of viral genome for treatment.	I	C
Invasive coronary angiography or coronary CT, depending on clinical likelihood, is recommended in patients with IMPS if an acute coronary syndrome is suspected to rule out obstructive coronary artery disease.	I	C
Routine serology is not recommended in patients with myocarditis and/or pericarditis for the evaluation of viral aetiology except for hepatitis C, HIV and Lyme disease.	III	C
Recommendations for genetic testing		
It is recommended to obtain family history including pedigrees in cases of recurrent IMPS to provide clues to the underlying aetiology, determine inheritance pattern, and identify relatives at risk.	I	C
Recommendations for the use of cardiovascular magnetic resonance imaging		
Myocarditis		
CMR is recommended in patients with suspected myocarditis to reach a clinical diagnosis and to determine the cause of acute myocardial injury, including assessment of oedema, ischaemia, and necrosis/fibrosis/scarring.	I	B

Continued

CMR is recommended for follow-up at least within the first 6 months in patients with myocarditis to identify a healed or ongoing process, for risk stratification and personalized therapy, and to enable a return to exercise.	I	C
Pericarditis		
CMR is recommended in patients with suspected pericarditis when a diagnosis cannot be made using clinical criteria to assess evidence of pericardial thickening, oedema, LGE, and to assess the persistence of disease during follow-up in selected cases.	I	B
Recommendations for computed tomography		
CT is recommended to evaluate pericardial thickness, calcifications, masses, and loculated pericardial effusions, as well as concomitant pleuropulmonary diseases and chest abnormalities.	I	C
Recommendations for endomyocardial biopsy		
EMB is recommended in patients with high-risk myocarditis, and/or haemodynamic instability, and/or in patients with intermediate-risk myocarditis not responding to conventional therapy in order to detect a specific histologic subtype and to assess the presence of viral genome for treatment.	I	C
Recommendations for autopsy		
Comprehensive autopsy is recommended in all patients <50 years of age with SCD to evaluate the presence of acute myocarditis as a cause and to detect potential underlying inherited cardiac diseases.	I	B
Retaining samples suitable for DNA extraction and consulting a cardiac pathologist is recommended in cases of SCD, when an inherited cause is suspected, or the cause of death remains unexplained.	I	B
Recommendations for medical therapy in myocarditis		
Management of heart failure		
Adherence to the ESC HF guidelines is recommended in cases of myocarditis with LV systolic dysfunction and/or HF to reduce symptoms and to improve LV function.	I	C
Immunosuppressive therapy		
Routine use of immunosuppressive therapy is not recommended in acute myocarditis with preserved LV function because no outcome benefit has been shown.	III	C
Recommendations for medical therapy in pericarditis		
Colchicine is recommended as first-line therapy in patients with pericarditis as an adjunct to aspirin/NSAID or corticosteroid therapy to reduce subsequent recurrences.	I	A
Anti-IL-1 agents (anakinra or rilonacept) are recommended for patients with recurrent pericarditis after failure of first-line therapies and corticosteroids, and elevation of C-reactive protein levels to reduce recurrences and allow corticosteroid withdrawal.	I	A
High-dose aspirin or NSAIDs with proton pump inhibitors are recommended as first-line therapy in patients with pericarditis to control symptoms and reduce recurrences.	I	B
Corticosteroids are not recommended as the first option for patients with pericarditis therapy without a specific indication.	III	C
Recommendations for interventional techniques, including circulatory support in myocarditis		
A timely and dedicated Shock Team discussion is recommended in patients with myocarditis in the presence of haemodynamic compromise, to decide on the need for escalation to MCS and to determine a long-term management plan.	I	C
Recommendations for interventional techniques in pericarditis		
Pericardiocentesis (echocardiography CT-, or fluoroscopy-guided) is recommended for cardiac tamponade, or suspected bacterial or neoplastic pericarditis, or symptomatic moderate to large pericardial effusion despite medical therapy.	I	C
Surgical pericardial drainage is recommended in patients with pericardial effusion when percutaneous pericardiocentesis is not feasible or with purulent pericardial effusion to allow complete drainage and to prevent constriction.	I	C
Surgical pleuro-pericardial window is recommended in patients with relapsing pericardial effusion despite medical therapy.	I	C
Recommendations for surgical therapy		
Surgical pericardiectomy is recommended in patients with chronic pericardial constriction or persistent constrictive pericarditis despite medical therapy to improve symptoms and survival.	I	C
Tricuspid valve repair is recommended in patients with pericardial constriction and severe tricuspid valve regurgitation to improve symptoms and survival.	I	C
Recommendations for management of arrhythmias and prevention of sudden cardiac death in myocarditis		
ICD in myocarditis—secondary prevention		
ICD implantation is recommended in patients with non-active myocarditis and haemodynamically not-tolerated sustained VT to prevent SCD.	I	C

Continued

Recommendations for risk stratification, complications, and outcomes of inflammatory myopericardial syndrome		
Follow-up with clinical assessment, biomarkers, ECG, exercise test, Holter-ECG monitoring, echocardiography, and CMR at least within 6 months after the index hospitalization is recommended in all patients with myocarditis to identify a potential progression or new risk factors.	I	C
Long-term follow-up is recommended for patients with complicated myocarditis to identify a potential progression or new complications.	I	C
Long-term follow-up is recommended for patients with incessant or recurrent pericarditis to identify a potential progression and new complications.	I	C
Recommendations for giant-cell myocarditis		
EMB is recommended in patients with suspected GCM due to unexplained new-onset HF of up to 2 weeks associated with a normal or dilated left ventricle and new ventricular arrhythmias, second- or third-degree AVB, or failure to respond to usual care within 1 to 2 weeks to initiate specific treatment.	I	C
Combined immunosuppressive therapy is recommended in patients with a diagnosed GCM.	I	C
Recommendations for myocarditis in sarcoidosis		
Diagnosis		
CMR, using tissue characterization techniques, is recommended in patients with suspected CS to assess cardiac inflammation and myocardial involvement.	I	B
¹⁸ F-FDG-PET is recommended for the diagnostic work-up, including detection of inflammation, as well as for follow-up and assessment of therapeutic response in patients with CS.	I	B
Therapy		
ICD implantation is recommended in patients with CS and sustained ventricular arrhythmia (VT/VF) or aborted CA to prevent SCD.	I	B
ICD implantation is recommended in patients with CS and LVEF ≤35% to prevent SCD.	I	C
Recommendations for immune checkpoint inhibitor-associated myocarditis		
Diagnostic triage within 24 h is recommended in patients with suspected myocarditis induced by ICI to initiate treatment rapidly.	I	C
Immediate disruption of ICI and administration of high-dosage corticosteroids are recommended in patients with ICI-associated myocarditis in order to stop the inflammatory reaction and stabilize the patient.	I	C
Recommendations for inflammatory cardiomyopathy		
Guideline-directed HF treatments are recommended in patients with inflammatory cardiomyopathy to improve and/or stabilize left ventricular function.	I	C
Specific medical therapy for the potentially underlying systemic disease is recommended in inflammatory cardiomyopathy.	I	C
Recommendations for tuberculous pericarditis		
Diagnosis and treatment of tuberculous pericarditis and effusion		
Diagnostic pericardiocentesis is recommended in all patients with suspected tuberculous pericarditis when diagnosis is not confirmed by non-invasive tests to identify the aetiological agent in pericardial fluid.	I	C
Empirical antituberculosis chemotherapy is recommended in patients living in endemic areas with exudative pericardial effusion after excluding other causes to treat the most likely cause.	I	C
Standard antituberculosis multidrug treatment for 6 months is recommended in patients with tuberculous pericarditis for the prevention of pericardial constriction.	I	C
Pericardiectomy is recommended in patients with tuberculous pericarditis if the condition is not improving or is deteriorating after 4–8 weeks of antituberculosis therapy to change the course of disease.	I	C
Empirical antituberculosis treatment is not recommended in patients living in non-endemic areas.	III	C
Recommendations for neoplastic pericardial involvement		
Pericardiocentesis is recommended for patients with cardiac tamponade to relieve symptoms and establish the diagnosis of malignant pericardial effusion.	I	C
Extended pericardial drainage (3–6 days) is recommended in patients with suspected or definite neoplastic pericardial effusion to prevent effusion recurrence.	I	B
Cytological analysis of pericardial fluid is recommended in patients with neoplastic pericarditis for the confirmation of malignant pericardial disease.	I	C
Systemic antineoplastic treatment is recommended in confirmed cases of neoplastic aetiology to treat the primary and secondary metastatic neoplastic involvement.	I	C

Continued

Recommendations for post-cardiac injury syndrome		
Anti-inflammatory therapy is recommended in patients with PCIS to hasten symptom remission and reduce recurrences.	I	B
IL-1 antagonists are recommended in patients with refractory PCIS to prevent recurrences and progression to constriction.	I	B
High-dose aspirin is recommended as the first-choice anti-inflammatory therapy for post-myocardial infarction pericarditis and in patients already on antiplatelet therapy.	I	C
Recommendations for purulent pericarditis		
Urgent pericardiocentesis and/or a surgical window is recommended in patients with suspicion of purulent pericarditis to establish a diagnosis.	I	C
Recommendations for constrictive pericarditis		
Diagnosis		
Multimodality imaging is recommended in all patients with suspected constrictive pericarditis to make the diagnosis and assess pericardial thickening, calcifications, and active inflammation.	I	C
Therapy		
Anti-inflammatory therapy is recommended in haemodynamically stable patients with a transient or new diagnosis of constriction with concomitant evidence of pericardial inflammation to prevent progression to constriction and avoid pericardiectomy.	I	C
Pericardiectomy is recommended in patients with permanent constriction if there is no active inflammation or anti-inflammatory treatment is not successful after 3–6 months.	I	C
Recommendations for pregnancy, lactation, and reproductive issues		
Pre-conception counselling is recommended in women with recurrent pericarditis or myocarditis to assess disease activity and to review therapy.	I	C
Recommendations for physical activity and myocarditis/pericarditis		
Restriction of physical exercise until remission, for at least 1 month, is recommended in athletes and non-athletes after IMPS using an individualized approach to accelerate recovery.	I	C
Recommendations for multidisciplinary teams in myopericardial syndromes		
A multidisciplinary team discussion at a referral centre is recommended in patients with high-risk/complicated IMPS to provide a patient-tailored approach.	I	C

AVB, atrioventricular block; CA, cardiac arrest; CMR, cardiovascular magnetic resonance; CS, cardiac sarcoidosis; CT, computed tomography; DNA, deoxyribonucleic acid; ECG, electrocardiogram; EMB, endomyocardial biopsy; ESC, European Society of Cardiology; ¹⁸F-FDG-PET, [¹⁸F]-fluorodeoxyglucose positron emission tomography; GCM, giant-cell myocarditis; HF, heart failure; HIV, human immunodeficiency virus; ICD, implantable cardioverter-defibrillator; ICI, immune checkpoint inhibitor; IL, interleukin; IMPS, inflammatory myopericardial syndrome; LGE, late gadolinium enhancement; LV, left ventricle; LVEF, left ventricular ejection fraction; MCS, mechanical circulatory support; NSAID, non-steroidal anti-inflammatory drug; PCIS, post-cardiac injury syndrome; SCD; sudden cardiac death; VF, ventricular fibrillation; VT, ventricular tachycardia.

^aClass of recommendation.

^bLevel of evidence.

19. Evidence tables

Evidence tables are available at the *European Heart Journal* online.

20. Data availability statement

No new data were generated or analysed in support of this research.

21. Author information

Author/Task Force Member Affiliations: **Valentino Collini**, Cardiology, Cardiothoracic Department, Santa Maria della Misericordia University Hospital, Udine, Italy; **Jan Gröschel**, Charité—Universitätsmedizin Berlin, corporate member of Freie Universität Berlin and Humboldt-Universität zu Berlin, ECRC Experimental and Clinical Research Center, Berlin, Germany, and DZHK (German Centre for Cardiovascular Research), partner site Berlin, Berlin, Germany, and Deutsches Herzzentrum der Charité, Klinik für

Kardiologie, Angiologie und Intensivmedizin, Berlin, Germany; **Yehuda Adler**, Sackler Medical School, Tel Aviv University, Tel Aviv, Israel; **Antonio Brucato**, Department of biomedical and clinical sciences, University of Milano, Fatebenefratelli Hospital, Milano, Italy; **Vanessa Christian** (United Kingdom), ESC Patient Forum, Sophia Antipolis, France; **Vanessa M. Ferreira**, Oxford Centre for Clinical Magnetic Resonance Research (OCMR), University of Oxford, Oxford, United Kingdom; **Estelle Gandjbakhch**, Cardiology Departement, Sorbonne Université, APHP, Hôpital Pitié Salpêtrière, Paris, France, and Referral Center for Inherited Cardiac Diseases, APHP, Hôpital Pitié Salpêtrière, Paris, France, and Inserm 1166, IHU ICAN, Paris, France; **Bettina Heidecker**, Deutsches Herzzentrum der Charité, Universitätsmedizin Berlin, Berlin, Germany, and Berlin Institute of Health (BIH), Charité, Universitätsmedizin Berlin, Berlin, Germany, and DZHK (German Centre for Cardiovascular Research), partner site Berlin, Berlin, Germany; **Mathieu Kerneis**, Sorbonne Université, Paris, France, and ACTION Group, Paris, France, and UMRS 1166 Inserm, Paris, France, and Institute of Cardiology, Hôpital Pitié-Salpêtrière,

Assistance Publique-Hôpitaux de Paris (AP-HP), Paris, France; **Allan L. Klein**, Center for the diagnosis of pericardial disease, department of cardiovascular medicine, heart, vascular and thoracic institute, Cleveland clinic, Cleveland, Ohio, United States of America; **Karin Klingel**, Institute for Pathology and Neuropathology, University Hospital Tuebingen, Tuebingen, Germany; **George Lazaros**, Cardiology, School of medicine, Hippokraton General Hospital, National and Kapodistrian University of Athens, Athens, Greece; **Roberto Lorusso**, Cardio-Thoracic Surgery, Maastricht University Medical Centre, Maastricht, Netherlands, and Cardiovascular Research Institute Maastricht, Maastricht, Netherlands; **Elena G. Nesukay**, Department of non-coronary heart diseases, rheumatology and therapy, National scientific center “The M.D. Strazhesko institute of cardiology, clinical and regenerative medicine”, Kiev, Ukraine; **Kazem Rahimi**, Nuffield department of women’s and reproductive health, University of Oxford, Oxford, United Kingdom; **Arsen D. Ristić**, Department of Cardiology, University Clinical Center of Serbia, Belgrade, Serbia, and Faculty of Medicine, Belgrade University, Belgrade, Serbia; **Marcin Rucinski** (Poland), ESC Patient Forum, Sophia Antipolis, France; **Leyla Elif Sade**, School of Medicine, University of Pittsburgh, Pittsburgh, PA, United States of America, and Department of Cardiology, University of Pittsburgh Medical Center, Pittsburgh, PA, United States of America; **Hannah Schaubroeck**, Intensive Care Unit, Ghent University Hospital, Ghent, Belgium; **Anne Grete Semb**, Department of research and innovation, REMEDY centre, Diakonhjemmet Hospital, Oslo, Norway; **Gianfranco Sinagra**, Center for Diagnosis and Treatment of Cardiomyopathies, Cardiothoracovascular Department, Azienda Sanitaria Universitaria Giuliano-Isontina (ASUGI), University of Trieste, Trieste, Italy; **Jens Jakob Thune**, Department of cardiology, Copenhagen University Hospital—Bispebjerg and Frederiksberg, Copenhagen, Denmark, and Department of clinical medicine, University of Copenhagen, Copenhagen, Denmark.

22. Appendix

ESC Scientific Document Group

Includes Document Reviewers and ESC National Cardiac Societies.

Document Reviewers: Elena Arbelo (CPG Review Co-ordinator) (Spain), Cristina Basso (CPG Review Co-ordinator) (Italy), Marianna Adamo (Italy), Suleman Aktaa (United Kingdom), Enrico Ammirati (Italy), Lisa Anderson (United Kingdom), Eloisa Arbustini (Italy), Emanuele Bobbio (Sweden), Giuseppe Boriani (Italy), Margarita Brida (Croatia), Robert A. Byrne (Ireland), Alida L.P. Caforio (Italy), Gh.-Andrei Dan (Romania), Fernando Domínguez (Spain), Suzanne Fredericks (Canada), Geeta Gulati (Norway), Borja Ibanez (Spain), Stefan James (Sweden), Alexander Kharlamov (Netherlands), Sabine Klaassen (Germany), Jolanda Kluin (Netherlands), Konstantinos C. Koskinas (Switzerland), Petr Kuchynka (Czech Republic), Vijay Kunadian (United Kingdom), Ulf Landmesser (Germany), Gregory Y.H. Lip (United Kingdom), Bernhard Maisch (Germany), Federica Marelli-Berg (United Kingdom), Pilar Martin (Spain), John William McEvoy (Ireland), Borislava Mihaylova (United Kingdom), Richard Mindham (United Kingdom), Inge Moelgaard (Denmark), Saidi A. Mohiddin (United Kingdom), Jens Cosedis Nielsen (Denmark), Agnes A. Pasquet (Belgium), Giovanni Peretto (Italy), Kalliopi Pilichou (Italy), Nicolas Piriou (France), Eva Prescott (Denmark), Amina Rakisheva (Kazakhstan), Bianca Rocca (Italy), Xavier Rossello (Spain), Anna

Sannino (Germany), Franziska Seidel (Germany), Felix C. Tanner (Switzerland), Witold Zbyszek Tomkowski (Poland), Ilonca Vaartjes (Netherlands), Sophie Van Linthout (Germany), Christiaan Vrints (Belgium), Romuald Wojnicz (Poland), Katja Zeppenfeld (Netherlands)

ESC National Cardiac Societies actively involved in the review process of the ESC Guidelines for the management of myocarditis and pericarditis:

Albania: Albanian Society of Cardiology, Albana Doko Banushi; **Algeria:** Algerian Society of Cardiology, Mohammed Chettibi; **Armenia:** Armenian Cardiologists Association, Hamayak S. Sisakian; **Azerbaijan:** Azerbaijan Society of Cardiology, Ogtay Musayev; **Belgium:** Belgian Society of Cardiology, Bernard P. Paelinck; **Bosnia and Herzegovina:** Association of Cardiologists of Bosnia and Herzegovina, Alden Begić; **Bulgaria:** Bulgarian Society of Cardiology, Yvaylo Daskalov; **Croatia:** Croatian Cardiac Society, Bosko Skoric; **Cyprus:** Cyprus Society of Cardiology, Marios Ioannides; **Czechia:** Czech Society of Cardiology, Tomas Palecek; **Denmark:** Danish Society of Cardiology, Kasper Rossing; **Egypt:** Egyptian Society of Cardiology, Haytham Soliman Ghareeb; **Estonia:** Estonian Society of Cardiology, Ulvi Hinto; **Finland:** Finnish Cardiac Society, Markku Kupari; **France:** French Society of Cardiology, Emmanuelle Berthelot; **Georgia:** Georgian Society of Cardiology, Vaja Agladze; **Germany:** German Cardiac Society, Brenda Gerull; **Greece:** Hellenic Society of Cardiology, Alexandros Kasiakogias; **Hungary:** Hungarian Society of Cardiology, Hajnalka Vágó; **Iceland:** Icelandic Society of Cardiology, Inga Jóna Ingimarsdóttir; **Ireland:** Irish Cardiac Society, Emer Joyce; **Israel:** Israel Heart Society, Sorel Goland; **Italy:** Italian Federation of Cardiology, Enrico Fabris; **Kazakhstan:** Association of Cardiologists of Kazakhstan, Murat Amanzholovich Mukarov; **Kosovo (Republic of):** Kosovo Society of Cardiology, Ibadete Bytyçi; **Kyrgyzstan:** Kyrgyz Society of Cardiology, Erkin Mirrakhimov, **Latvia:** Latvian Society of Cardiology, Ginta Kamzola; **Lebanon:** Lebanese Society of Cardiology, Naji J. Abirached; **Libya:** Libyan Cardiac Society, Aiman M. Smer; **Lithuania:** Lithuanian Society of Cardiology, Vaida Mizariene; **Luxembourg:** Luxembourg Society of Cardiology, Andrei Codreanu; **Malta:** Maltese Cardiac Society, Tiziana Felice; **Moldova (Republic of):** Moldavian Society of Cardiology, Eleonora Boris Vataman; **Morocco:** Moroccan Society of Cardiology, Aida Soufiani; **Netherlands:** Netherlands Society of Cardiology, Geertruida Petronella Bijvoet; **North Macedonia:** National Society of Cardiology of North Macedonia, Irena Mitevaska; **Norway:** Norwegian Society of Cardiology, Haavard Ravnstad; **Poland:** Polish Cardiac Society, Karol Kamiński; **Portugal:** Portuguese Society of Cardiology, Nuno Cardim; **Romania:** Romanian Society of Cardiology, Oliviana Geavlete; **San Marino:** San Marino Society of Cardiology, Emidio Troiani; **Serbia:** Cardiology Society of Serbia, Marija Zdravkovic; **Slovakia:** Slovak Society of Cardiology, Marcela Dankova; **Slovenia:** Slovenian Society of Cardiology, Andreja Černe Čerček; **Spain:** Spanish Society of Cardiology, Fernando Domínguez; **Sweden:** Swedish Society of Cardiology, Gabriel Arefalk; **Switzerland:** Swiss Society of Cardiology, Philip Haaf; **Syrian Arab Republic:** Syrian Cardiovascular Association, Mohammed Yassin Bani Marjeh; **Türkiye:** Turkish Society of Cardiology, Baris Kilicaslan; **Ukraine:** Ukrainian Association of Cardiology, Sergii Cherniuk; **United Kingdom of Great Britain and Northern Ireland:** British Cardiovascular Society, Saidi A. Mohiddin, **Uzbekistan:** Association of Cardiologists of Uzbekistan, Amayak Kevorkov

ESC Clinical Practice Guidelines (CPG) Committee: Ulf Landmesser (Chairperson) (Germany), Stefan James (Co-Chairperson) (Sweden), Marianna Adamo (Italy), Suleman Aktaa (United Kingdom), Folkert W. Asselbergs (Netherlands), Colin Baigent (United Kingdom), Michael A. Borger (Germany), Giuseppe Boriani (Italy), Margarita Brida (Croatia), Robert A. Byrne (Ireland), Estelle Gandjbakhch (France), Bettina Heidecker (Germany), Anja Hennemuth (Germany), Borja Ibanez (Spain), Peter Jüni (United Kingdom), Gregory Y.H. Lip (United Kingdom), John William McEvoy (Ireland), Borislava Mihaylova (United Kingdom), Inge Moelgaard (Denmark), Lis Neubeck (United Kingdom), Eva Prescott (Denmark), Bianca Rocca (Italy), Xavier Rossello (Spain), Anna Sannino (Germany), Felix C. Tanner (Switzerland), Wojtek Wojakowski (Poland), Katja Zeppenfeld (Netherlands)

Contributor either withdrew or was engaged in only a part of the review process: Gerhard Poelzl (Austria)

23. References

- Adler Y, Charron P, Imazio M, Badano L, Barón-Esquivias G, Bogaert J, et al. 2015 ESC Guidelines for the diagnosis and management of pericardial diseases: the task force for the diagnosis and management of pericardial diseases of the European Society of Cardiology (ESC) Endorsed by: the European Association for Cardio-Thoracic Surgery (EACTS). *Eur Heart J* 2015;**36**:2921–64. <https://doi.org/10.1093/eurheartj/ehv318>
- Adamopoulos S, Miliopoulos D, Karavidas A, Nikolaou M, Lazaros G, Gkouziouta A, et al. Hellenic Registry on Myocarditis SyndromES on behalf of Hellenic Heart Failure Association: the HERMES-HF registry. *ESC Heart Fail* 2020;**7**:3676–84. <https://doi.org/10.1002/ehf2.12894>
- Aquaro GD, Perfetti M, Camastra G, Monti L, Dellegrattaglia S, Moro C, et al. Cardiac MR with late gadolinium enhancement in acute myocarditis with preserved systolic function: ITAMY study. *J Am Coll Cardiol* 2017;**70**:1977–87. <https://doi.org/10.1016/j.jacc.2017.08.044>
- Imazio M, Brucato A, Barbieri A, Ferroni F, Maestroni S, Ligabue G, et al. Good prognosis for pericarditis with and without myocardial involvement: results from a multicenter, prospective cohort study. *Circulation* 2013;**128**:42–9. <https://doi.org/10.1161/CIRCULATIONAHA.113.001531>
- Puntmann VO, Carej ML, Wieters I, Fahim M, Arendt C, Hoffmann J, et al. Outcomes of cardiovascular magnetic resonance imaging in patients recently recovered from coronavirus disease 2019 (COVID-19). *JAMA Cardiol* 2020;**5**:1265–73. <https://doi.org/10.1001/jamacardio.2020.3557>
- Keren A, Asleh R, Birati EY, Ben Gal T, Arad M. Definition and diagnosis of acute myocarditis: a position statement of the Israel Heart Society. *Isr Med Assoc J* 2023;**25**:519–24.
- Montera MW, Marcondes-Braga FG, Simões MV, Moura LAZ, Fernandes F, Mangine S, et al. Brazilian Society of Cardiology guideline on myocarditis—2022. *Arq Bras Cardiol* 2022;**119**:143–211. <https://doi.org/10.36660/abc.20220412>
- Nagai T, Inomata T, Kohno T, Sato T, Tada A, Kubo T, et al. JCS 2023 guideline on the diagnosis and treatment of myocarditis. *Circ J* 2023;**87**:674–754. <https://doi.org/10.1253/circj.CJ-22-0696>
- Writing Committee; Drazner MH, Bozkurt B, Cooper LT, Aggarwal NR, Basso C, et al. 2024 ACC expert consensus decision pathway on strategies and criteria for the diagnosis and management of myocarditis: a report of the American College of Cardiology Solution Set Oversight Committee. *J Am Coll Cardiol* 2025;**85**:391–431. <https://doi.org/10.1016/j.jacc.2024.10.080>
- Caforio ALP, Pankuweit S, Arbustini E, Basso C, Gimeno-Blanes J, Felix SB, et al. Current state of knowledge on aetiology, diagnosis, management, and therapy of myocarditis: a position statement of the European Society of Cardiology Working Group on Myocardial and Pericardial Diseases. *Eur Heart J* 2013;**34**:2636–48, 2648a–48d. <https://doi.org/10.1093/eurheartj/eh210>
- Pelliccia A, Sharma S, Gati S, Bäck M, Börjesson M, Caselli S, et al. 2020 ESC Guidelines on sports cardiology and exercise in patients with cardiovascular disease. *Eur Heart J* 2021;**42**:17–96. <https://doi.org/10.1093/eurheartj/ehaa605>
- McDonagh TA, Metra M, Adamo M, Gardner RS, Baumbach A, Böhm M, et al. 2021 ESC Guidelines for the diagnosis and treatment of acute and chronic heart failure. *Eur Heart J* 2021;**42**:3599–726. <https://doi.org/10.1093/eurheartj/ehab368>
- Arbelo E, Protonotarios A, Gimeno JR, Arbustini E, Barriales-Villa R, Basso C, et al. 2023 ESC Guidelines for the management of cardiomyopathies. *Eur Heart J* 2023;**44**:3503–626. <https://doi.org/10.1093/eurheartj/ehad194>
- Law YM, Lal AK, Chen S, Čiháková D, Cooper LT, Deshpande S, et al. Diagnosis and management of myocarditis in children: a scientific statement from the American Heart Association. *Circulation* 2021;**144**:e123–35. <https://doi.org/10.1161/CIR.0000000000001001>
- Maisch B, Seferović PM, Ristić AD, Erbel R, Rienmüller R, Adler Y, et al. Guidelines on the diagnosis and management of pericardial diseases executive summary: the task force on the diagnosis and management of pericardial diseases of the European Society of Cardiology. *Eur Heart J* 2004;**25**:587–610. <https://doi.org/10.1016/j.ehj.2004.02.002>
- Patriki D, Gresser E, Manka R, Emmert MY, Lüscher TF, Heidecker B. Approximation of the incidence of myocarditis by systematic screening with cardiac magnetic resonance imaging. *JACC Heart Fail* 2018;**6**:573–9. <https://doi.org/10.1016/j.jchf.2018.03.002>
- Fu M, Kontogeorgos S, Thunström E, Zverkova Sandström T, Kroon C, Bollano E, et al. Trends in myocarditis incidence, complications and mortality in Sweden from 2000 to 2014. *Sci Rep* 2022;**12**:1810. <https://doi.org/10.1038/s41598-022-05951-z>
- Roth GA, Mensah GA, Johnson CO, Addolorato G, Ammirati E, Baddour LM, et al. Global burden of cardiovascular diseases and risk factors, 1990–2019: update from the GBD 2019 study. *J Am Coll Cardiol* 2020;**76**:2982–3021. <https://doi.org/10.1016/j.jacc.2020.11.010>
- Global Burden of Disease Study 2013 Collaborators. Global, regional, and national incidence, prevalence, and years lived with disability for 301 acute and chronic diseases and injuries in 188 countries, 1990–2013: a systematic analysis for the Global Burden of Disease Study 2013. *Lancet* 2015;**386**:743–800. [https://doi.org/10.1016/S0140-6736\(15\)60692-4](https://doi.org/10.1016/S0140-6736(15)60692-4)
- Messroghli DR, Pickardt T, Fischer M, Oppen-Rhein B, Papakostas K, Böcker D, et al. Toward evidence-based diagnosis of myocarditis in children and adolescents: rationale, design, and first baseline data of MYKKE, a multicenter registry and study platform. *Am Heart J* 2017;**187**:133–44. <https://doi.org/10.1016/j.ahj.2017.02.027>
- Arola A, Pikkarainen E, Sipilä JO, Pykärä J, Rautava P, Kytö V. Occurrence and features of childhood myocarditis: a nationwide study in Finland. *J Am Heart Assoc* 2017;**6**:e005306. <https://doi.org/10.1161/JAHA.116.005306>
- Imazio M, Cecchi E, Demichelis B, Chinaglia A, Ierna S, Demarie D, et al. Myopericarditis versus viral or idiopathic acute pericarditis. *Heart* 2008;**94**:498–501. <https://doi.org/10.1136/hrt.2006.104067>
- Kytö V, Sipilä J, Rautava P. Clinical profile and influences on outcomes in patients hospitalized for acute pericarditis. *Circulation* 2014;**130**:1601–6. <https://doi.org/10.1161/CIRCULATIONAHA.114.010376>
- Imazio M, Brucato A, Cemin R, Ferrua S, Maggolini S, Beqaraj F, et al. A randomized trial of colchicine for acute pericarditis. *N Engl J Med* 2013;**369**:1522–8. <https://doi.org/10.1056/NEJMoa1208536>
- Imazio M, Belli R, Brucato A, Cemin R, Ferrua S, Beqaraj F, et al. Efficacy and safety of colchicine for treatment of multiple recurrences of pericarditis (CORP-2): a multicentre, double-blind, placebo-controlled, randomised trial. *Lancet* 2014;**383**:2232–7. [https://doi.org/10.1016/S0140-6736\(13\)62709-9](https://doi.org/10.1016/S0140-6736(13)62709-9)
- Charpentier S, Beaune S, Joly LM, Khoury A, Duchateau F-X, Briot R, et al. Management of chest pain in the French emergency healthcare system: the prospective observational EPIDOLTHO study. *Eur J Emerg Med* 2018;**25**:404–10. <https://doi.org/10.1097/MEJ.0000000000000481>
- Sexson Tejtel SK, Munoz FM, Al-Ammouri I, Savorgnan F, Guggilla RK, Khuri-Bulos N, et al. Myocarditis and pericarditis: case definition and guidelines for data collection, analysis, and presentation of immunization safety data. *Vaccine* 2022;**40**:1499–511. <https://doi.org/10.1016/j.vaccine.2021.11.074>
- Ammirati E, Cipriani M, Moro C, Raineri C, Pini D, Sormani P, et al. Clinical presentation and outcome in a contemporary cohort of patients with acute myocarditis: Multicenter Lombardy Registry. *Circulation* 2018;**138**:1088–99. <https://doi.org/10.1161/CIRCULATIONAHA.118.035319>
- Delgado V, Ajmone Marsan N, de Waha S, Bonaros N, Brida M, Burri H, et al. 2023 ESC Guidelines for the management of endocarditis. *Eur Heart J* 2023;**44**:3948–4042. <https://doi.org/10.1093/eurheartj/ehad193>
- Ferreira VM, Schulz-Menger J, Holmvang G, Kramer CM, Carbone I, Sechtem U, et al. Cardiovascular magnetic resonance in nonischemic myocardial inflammation: expert recommendations. *J Am Coll Cardiol* 2018;**72**:3158–76. <https://doi.org/10.1016/j.jacc.2018.09.072>
- Aretz HT. Myocarditis: the Dallas criteria. *Hum Pathol* 1987;**18**:619–24. [https://doi.org/10.1016/s0046-8177\(87\)80363-5](https://doi.org/10.1016/s0046-8177(87)80363-5)
- Tschöpe C, Ammirati E, Bozkurt B, Caforio ALP, Cooper LT, Felix SB, et al. Myocarditis and inflammatory cardiomyopathy: current evidence and future directions. *Nat Rev Cardiol* 2021;**18**:169–93. <https://doi.org/10.1038/s41569-020-00435-x>
- Leone O, Veinot JP, Angelini A, Baandrup UT, Basso C, Berry G, et al. 2011 Consensus statement on endomyocardial biopsy from the Association for European Cardiovascular Pathology and the Society for Cardiovascular Pathology. *Cardiovasc Pathol* 2012;**21**:245–74. <https://doi.org/10.1016/j.carpath.2011.10.001>
- Caforio ALP, Giordani AS, Baritussio A, Marcolongo D, Vicenzetto C, Tarantini G, et al. Long-term efficacy and safety of tailored immunosuppressive therapy in immune-mediated biopsy-proven myocarditis: a propensity-weighted study. *Eur J Heart Fail* 2024;**26**:1175–85. <https://doi.org/10.1002/ehfj.3220>

35. Imazio M, Squarotti GB, Andreis A, Agosti A, Millesimo M, Frea S, et al. Diagnostic and prognostic role of the electrocardiogram in patients with pericarditis. *Heart* 2022;**108**: 1474–8. <https://doi.org/10.1136/heartjnl-2021-320443>
36. Imazio M, Brucato A, Maestroni S, Cumetti D, Dominelli A, Natale G, et al. Prevalence of C-reactive protein elevation and time course of normalization in acute pericarditis: implications for the diagnosis, therapy, and prognosis of pericarditis. *Circulation* 2011;**123**:1092–7. <https://doi.org/10.1161/CIRCULATIONAHA.110.986372>
37. Pisacreta AM, Mascolo R, Nivuori M, Dominioni CC, Gabiati C, Trotta L, et al. Acute pericarditis with pleuropulmonary involvement, fever and elevated C-reactive protein: a systemic autoinflammatory disease? A cohort study. *Eur J Intern Med* 2023;**113**:45–8. <https://doi.org/10.1016/j.ejim.2023.03.034>
38. Tombetti E, Casarin F, Bizzi E, Bezer S, Mascolo R, Pallini G, et al. Relapsing pericarditis: peripheral blood neutrophilia, lymphopenia and high neutrophil-to-lymphocyte ratio herald acute attacks, high-grade inflammation, multiserosal involvement, and predict multiple recurrences. *Int J Rheum Dis* 2023;**26**:337–43. <https://doi.org/10.1111/1756-185X.14523>
39. Ammirati E, Frigerio M, Adler ED, Basso C, Birnie DH, Brambatti M, et al. Management of acute myocarditis and chronic inflammatory cardiomyopathy: an expert consensus document. *Circ Heart Fail* 2020;**13**:e007405. <https://doi.org/10.1161/CIRCHEARTFAILURE.120.007405>
40. Seidel U, Opgen-Rhein B, Rentzsch A, Boehne M, Wannemacher B, Boecker D, et al. Clinical characteristics and outcome of biopsy-proven myocarditis in children—results of the German prospective multicentre registry 'MYKKE'. *Int J Cardiol* 2022;**357**: 95–104. <https://doi.org/10.1016/j.ijcard.2022.03.026>
41. Kühl U, Pauschinger M, Noutsias M, Seeberg B, Bock T, Lassner D, et al. High prevalence of viral genomes and multiple viral infections in the myocardium of adults with 'idiopathic' left ventricular dysfunction. *Circulation* 2005;**111**:887–93. <https://doi.org/10.1161/01.CIR.0000155616.07901.35>
42. Ukimura A, Satomi H, Ooi Y, Kanzaki Y. Myocarditis associated with influenza A H1N1pdm2009. *Influenza Res Treat* 2012;**2012**:351979. <https://doi.org/10.1155/2012/351979>
43. Lazarou E, Lazaros G, Antonopoulos AS, Imazio M, Vasileiou P, Karavidas A, et al. A risk score for pericarditis recurrence. *Eur J Clin Invest* 2021;**51**:e13602. <https://doi.org/10.1111/eci.13602>
44. Imazio M, Andreis A, Lubian M, Lazaros G, Lazarou E, Brucato A, et al. The Torino Pericarditis Score: a new-risk stratification tool to predict complicated pericarditis. *Intern Emerg Med* 2021;**16**:1921–6. <https://doi.org/10.1007/s11739-021-02803-y>
45. Lazaros G, Antonopoulos AS, Lazarou E, Vlachopoulos C, Vogiatzi G, Vassilopoulos D, et al. Age- and sex-based differences in patients with acute pericarditis. *Eur J Clin Invest* 2021;**51**:e13392. <https://doi.org/10.1111/eci.13392>
46. Vecchié A, Chiabrandi JG, Dell MS, Bonaventura A, Mauro AG, Wohlford G, et al. Clinical presentation and outcomes of acute pericarditis in a large urban hospital in the United States of America. *Chest* 2020;**158**:2556–67. <https://doi.org/10.1016/j.chest.2020.07.039>
47. Gouriet F, Levy P-Y, Casalta J-P, Zandotti C, Collart F, Lepidi H, et al. Etiology of pericarditis in a prospective cohort of 1162 cases. *Am J Med* 2015;**128**:784.e1–e8. <https://doi.org/10.1016/j.amjmed.2015.01.040>
48. Mayosi BM, Wiysonge CS, Ntseke M, Volmink JA, Gumede F, Maartens G, et al. Clinical characteristics and initial management of patients with tuberculous pericarditis in the HIV era: the Investigation of the Management of Pericarditis in Africa (IMPI Africa) registry. *BMC Infect Dis* 2006;**6**:2. <https://doi.org/10.1186/1471-2334-6-2>
49. Conte E, Tamani S, Bizzi E, Maestroni S, Cumetti D, Novembre ML, et al. Post-cardiac injury syndrome and pericardial effusion recurrence after pericardial effusion drainage in chronic idiopathic pericardial effusion. *Eur J Intern Med* 2024;**123**: 132–7. <https://doi.org/10.1016/j.ejim.2024.01.024>
50. Peet CJ, Rowczenio D, Omoyinmi E, Papadopoulou C, Mapalo BRR, Wood MR, et al. Pericarditis and autoinflammation: a clinical and genetic analysis of patients with idiopathic recurrent pericarditis and monogenic autoinflammatory diseases at a national referral center. *J Am Heart Assoc* 2022;**11**:e024931. <https://doi.org/10.1161/JAHA.121.024931>
51. Imazio M, Faletra F, Zucco J, Mio C, Carraro M, Gava AM, et al. Genetic variants in patients with recurrent pericarditis. *J Cardiovasc Med (Hagerstown)* 2024;**25**:799–804. <https://doi.org/10.2459/JCM.0000000000001669>
52. Caforio ALP, Brucato A, Doria A, Brambilla G, Angelini A, Ghirardello A, et al. Anti-heart and anti-intercalated disk autoantibodies: evidence for autoimmunity in idiopathic recurrent acute pericarditis. *Heart* 2010;**96**:779–84. <https://doi.org/10.1136/hrt.2009.187138>
53. Basso C. Myocarditis. *N Engl J Med* 2022;**387**:1488–500. <https://doi.org/10.1056/NEJMr2114478>
54. Ammirati E, Moslehi JJ. Diagnosis and treatment of acute myocarditis: a review. *JAMA* 2023;**329**:1098–113. <https://doi.org/10.1001/jama.2023.3371>
55. Younis A, Matetzky S, Mulla VV, Masalha E, Afel Y, Chernomordik F, et al. Epidemiology characteristics and outcome of patients with clinically diagnosed acute myocarditis. *Am J Med* 2020;**133**:492–9. <https://doi.org/10.1016/j.amjmed.2019.10.015>
56. Ammirati E, Veronese G, Brambatti M, Merlo M, Cipriani M, Potena L, et al. Fulminant versus acute nonfulminant myocarditis in patients with left ventricular systolic dysfunction. *J Am Coll Cardiol* 2019;**74**:299–311. <https://doi.org/10.1016/j.jacc.2019.04.063>
57. Huang F, Ammirati E, Ponnaiah M, Montero S, Raimbault V, Abrams D, et al. Fulminant myocarditis proven by early biopsy and outcomes. *Eur Heart J* 2023;**44**:5110–24. <https://doi.org/10.1093/eurheartj/ehad707>
58. Zeppenfeld K, Tfelt-Hansen J, de Riva M, Winkel BG, Behr ER, Blom NA, et al. 2022 ESC Guidelines for the management of patients with ventricular arrhythmias and the prevention of sudden cardiac death: developed by the task force for the management of patients with ventricular arrhythmias and the prevention of sudden cardiac death of the European Society of Cardiology (ESC) Endorsed by the Association for European Paediatric and Congenital Cardiology (AEPC). *Eur Heart J* 2022;**43**: 3997–4126. <https://doi.org/10.1093/eurheartj/ehac262>
59. Berg J, Kottwitz J, Baltensperger N, Kissel CK, Lovrincic M, Mehra T, et al. Cardiac magnetic resonance imaging in myocarditis reveals persistent disease activity despite normalization of cardiac enzymes and inflammatory parameters at 3-month follow-up. *Circ Heart Fail* 2017;**10**:e004262. <https://doi.org/10.1161/CIRCHEARTFAILURE.117.004262>
60. Schwuchow-Thonke S, Göbel S, Emrich T, Schmitt VH, Fueting F, Klank C, et al. Increased C reactive protein, cardiac troponin I and GLS are associated with myocardial inflammation in patients with non-ischemic heart failure. *Sci Rep* 2021;**11**:3008. <https://doi.org/10.1038/s41598-021-82592-8>
61. Krumm P, Brendel JM, Klingel K, Müller KAL, Kübler J, Gräni C, et al. Using multiparametric cardiac magnetic resonance to phenotype and differentiate biopsy-proven chronic from healed myocarditis and dilated cardiomyopathy. *J Clin Med* 2022;**11**: 5047. <https://doi.org/10.3390/jcm11175047>
62. Anzini M, Merlo M, Sabbadini G, Barbati G, Finocchiaro G, Pinamonti B, et al. Long-term evolution and prognostic stratification of biopsy-proven active myocarditis. *Circulation* 2013;**128**:2384–94. <https://doi.org/10.1161/CIRCULATIONAHA.113.003092>
63. Caforio ALP, Kaski JP, Gimeno JR, Elliott PM, Laroche C, Tavazzi L, et al. Endomyocardial biopsy: safety and prognostic utility in paediatric and adult myocarditis in the European Society of Cardiology EURObservational Research Programme Cardiomyopathy and Myocarditis Long-Term Registry. *Eur Heart J* 2024;**45**: 2548–69. <https://doi.org/10.1093/eurheartj/ehae169>
64. Lopez-Ayala JM, Pastor-Quirante F, Gonzalez-Carrillo J, Lopez-Cuenca D, Sanchez-Munoz JJ, Oliva-Sandoval MJ, et al. Genetics of myocarditis in arrhythmogenic right ventricular dysplasia. *Heart Rhythm* 2015;**12**:766–73. <https://doi.org/10.1016/j.hrthm.2015.01.001>
65. Collet J-P, Thiele H, Barbato E, Barthélémy O, Bauersachs J, Bhatt DL, et al. 2020 ESC Guidelines for the management of acute coronary syndromes in patients presenting without persistent ST-segment elevation. *Eur Heart J* 2021;**42**:1289–367. <https://doi.org/10.1093/eurheartj/ehaa575>
66. Caforio ALP, Calabrese F, Angelini A, Tona F, Vinci A, Bottaro S, et al. A prospective study of biopsy-proven myocarditis: prognostic relevance of clinical and aetiopathogenetic features at diagnosis. *Eur Heart J* 2007;**28**:1326–33. <https://doi.org/10.1093/eurheartj/ehm076>
67. Buiatti A, Merlo M, Pinamonti B, De Biasio M, Bussani R, Sinagra G. Clinical presentation and long-term follow-up of perimyocarditis. *J Cardiovasc Med (Hagerstown)* 2013;**14**:235–41. <https://doi.org/10.2459/JCM.0b013e328351da6e>
68. Abdel-Aty H, Boyé P, Zagrosek A, Wassmuth R, Kumar A, Messroghli D, et al. Diagnostic performance of cardiovascular magnetic resonance in patients with suspected acute myocarditis: comparison of different approaches. *J Am Coll Cardiol* 2005;**45**:1815–22. <https://doi.org/10.1016/j.jacc.2004.11.069>
69. Zagrosek A, Abdel-Aty H, Boyé P, Wassmuth R, Messroghli D, Utz W, et al. Cardiac magnetic resonance monitors reversible and irreversible myocardial injury in myocarditis. *JACC Cardiovasc Imaging* 2009;**2**:131–8. <https://doi.org/10.1016/j.jcmg.2008.09.014>
70. Gröschel J, Bhojroo Y, Blaszczyk E, Trauzeddel RF, Viezzer D, Saad H, et al. Different impacts on the heart after COVID-19 infection and vaccination: insights from cardiovascular magnetic resonance. *Front Cardiovasc Med* 2022;**9**:916922. <https://doi.org/10.3389/fcvm.2022.916922>
71. Gentile P, Merlo M, Peretto G, Ammirati E, Sala S, Della Bella P, et al. Post-discharge arrhythmic risk stratification of patients with acute myocarditis and life-threatening ventricular tachyarrhythmias. *Eur J Heart Fail* 2021;**23**:2045–54. <https://doi.org/10.1002/ehf.2288>
72. Byrne RA, Rossello X, Coughlan JJ, Barbato E, Berry C, Chieffo A, et al. 2023 ESC Guidelines for the management of acute coronary syndromes. *Eur Heart J* 2023;**44**: 3720–826. <https://doi.org/10.1093/eurheartj/ehad191>
73. Baritussio A, Schiavo A, Basso C, Giordani AS, Cheng C-Y, Pontara E, et al. Predictors of relapse, death or heart transplantation in myocarditis before the introduction of immunosuppression: negative prognostic impact of female gender, fulminant onset, lower ejection fraction and serum autoantibodies. *Eur J Heart Fail* 2022;**24**:1033–44. <https://doi.org/10.1002/ehf.2496>

74. Ammirati E, Cipriani M, Lilliu M, Sormani P, Varrenti M, Raineri C, et al. Survival and left ventricular function changes in fulminant versus nonfulminant acute myocarditis. *Circulation* 2017;**136**:529–45. <https://doi.org/10.1161/CIRCULATIONAHA.117.026386>
75. Kondo T, Okumura T, Shibata N, Imaizumi T, Dohi K, Izawa H, et al. Differences in prognosis and cardiac function according to required percutaneous mechanical circulatory support and histological findings in patients with fulminant myocarditis: insights from the CHANGE PUMP 2 study. *J Am Heart Assoc* 2022;**11**:e023719. <https://doi.org/10.1161/JAHA.121.023719>
76. Peretto G, Sala S, Rizzo S, De Luca G, Campochiaro C, Sartorelli S, et al. Arrhythmias in myocarditis: state of the art. *Heart Rhythm* 2019;**16**:793–801. <https://doi.org/10.1016/j.hrthm.2018.11.024>
77. Imazio M, Lazaros G, Picardi E, Vasileiou P, Orlando F, Carraro M, et al. Incidence and prognostic significance of new onset atrial fibrillation/flutter in acute pericarditis. *Heart* 2015;**101**:1463–7. <https://doi.org/10.1136/heartjnl-2014-307398>
78. Shah Z, Mohammed M, Vuddanda V, Ansari MW, Masoomi R, Gupta K. National trends, gender, management, and outcomes of patients hospitalized for myocarditis. *Am J Cardiol* 2019;**124**:131–6. <https://doi.org/10.1016/j.amjcard.2019.03.036>
79. Rosier L, Zouaghi A, Barré V, Martins R, Probst V, Marijon E, et al. High risk of sustained ventricular arrhythmia recurrence after acute myocarditis. *J Clin Med* 2020;**9**:848. <https://doi.org/10.3390/jcm9030848>
80. Birnie DH, Sauer WH, Bogun F, Cooper JM, Culver DA, Duvernoy CS, et al. HRS expert consensus statement on the diagnosis and management of arrhythmias associated with cardiac sarcoidosis. *Heart Rhythm* 2014;**11**:1305–23. <https://doi.org/10.1016/j.hrthm.2014.03.043>
81. Bobbio E, Hjalmarsson C, Björkenstam M, Polte CL, Oldfors A, Lindström U, et al. Diagnosis, management, and outcome of cardiac sarcoidosis and giant cell myocarditis: a Swedish single center experience. *BMC Cardiovasc Disord* 2022;**22**:192. <https://doi.org/10.1186/s12872-022-02639-0>
82. Cooper LT, Berry GJ, Shabetai R. Idiopathic giant-cell myocarditis—natural history and treatment. *N Engl J Med* 1997;**336**:1860–66. <https://doi.org/10.1056/NEJM199706263362603>
83. Peretto G, Sala S, Rizzo S, Palmisano A, Esposito A, De Cobelli F, et al. Ventricular arrhythmias in myocarditis: characterization and relationships with myocardial inflammation. *J Am Coll Cardiol* 2020;**75**:1046–57. <https://doi.org/10.1016/j.jacc.2020.01.036>
84. Peretto G, Sala S, Basso C, Rizzo S, Radinovic A, Frontera A, et al. Inflammation as a predictor of recurrent ventricular tachycardia after ablation in patients with myocarditis. *J Am Coll Cardiol* 2020;**76**:1644–56. <https://doi.org/10.1016/j.jacc.2020.08.012>
85. van der Linde MR. Lyme carditis: clinical characteristics of 105 cases. *Scand J Infect Dis Suppl* 1991;**77**:81–4. <https://doi.org/10.3109/inf.1991.23.suppl-77.01>
86. Glikson M, Nielsen JC, Kronborg MB, Michowitz Y, Auricchio A, Barbash IM, et al. 2021 ESC guidelines on cardiac pacing and cardiac resynchronization therapy: developed by the Task Force on cardiac pacing and cardiac resynchronization therapy of the European Society of Cardiology (ESC) With the special contribution of the European Heart Rhythm Association (EHRA). *Eur Heart J* 2021;**42**:3427–520. <https://doi.org/10.1093/eurheartj/ehab364>
87. Bhatia RT, Finocchiaro G, Westaby J, Chatrath N, Behr ER, Papadakis M, et al. Myocarditis and sudden cardiac death in the community: clinical and pathological insights from a national registry in the United Kingdom. *Circ Arrhythm Electrophysiol* 2023;**16**:e012129. <https://doi.org/10.1161/CIRCEP.123.012129>
88. Lyngé TH, Nielsen TS, Gregers Winkel B, Tfelt-Hansen J, Banner J. Sudden cardiac death caused by myocarditis in persons aged 1–49 years: a nationwide study of 14 294 deaths in Denmark. *Forensic Sci Res* 2019;**4**:247–56. <https://doi.org/10.1080/20961790.2019.1595352>
89. Peretto G, Mazzone P, Paglino G, Marzi A, Tsitsinakis G, Rizzo S, et al. Continuous electrical monitoring in patients with arrhythmic myocarditis: insights from a referral center. *J Clin Med* 2021;**10**:5142. <https://doi.org/10.3390/jcm10215142>
90. Baritussio A, Cheng C-Y, Simeti G, Ocagli H, Lorenzoni G, Giordani AS, et al. CMR predictors of favorable outcome in myocarditis: a single-center experience. *J Clin Med* 2024;**13**:1229. <https://doi.org/10.3390/jcm13051229>
91. Ammirati E, Raimondi F, Piriou N, Sardo Infirri L, Mohiddin SA, Mazzanti A, et al. Acute myocarditis associated with desmosomal gene variants. *JACC Heart Fail* 2022;**10**:714–27. <https://doi.org/10.1016/j.jchf.2022.06.013>
92. Kontorovich AR, Tang Y, Patel N, Georgievskaya Z, Shadrina M, Williams N, et al. Burden of cardiomyopathic genetic variation in lethal pediatric myocarditis. *Circ Genom Precis Med* 2021;**14**:e003426. <https://doi.org/10.1161/CIRCGEN.121.003426>
93. Seidel F, Holtgrewe M, Al-Wakeel-Marquard N, Opgen-Rhein B, Dartsch J, Herbst C, et al. Pathogenic variants associated with dilated cardiomyopathy predict outcome in pediatric myocarditis. *Circ Genom Precis Med* 2021;**14**:e003250. <https://doi.org/10.1161/CIRCGEN.120.003250>
94. Lota AS, Hazebroek MR, Theotokis P, Wassall R, Salmi S, Halliday BP, et al. Genetic architecture of acute myocarditis and the overlap with inherited cardiomyopathy. *Circulation* 2022;**146**:1123–34. <https://doi.org/10.1161/CIRCULATIONAHA.121.058457>
95. Monda E, Bakalakis A, Cannie D, O'Mahony C, Syrris P, Kaski JP, et al. Prevalence of pathogenic variants in cardiomyopathy-associated genes in acute myocarditis: a systematic review and meta-analysis. *JACC Heart Fail* 2024;**12**:1101–11. <https://doi.org/10.1016/j.jchf.2024.02.012>
96. Belkaya S, Kontorovich AR, Byun M, Mulero-Navarro S, Bajolle F, Cobat A, et al. Autosomal recessive cardiomyopathy presenting as acute myocarditis. *J Am Coll Cardiol* 2017;**69**:1653–65. <https://doi.org/10.1016/j.jacc.2017.01.043>
97. Smith ED, Lakdawala NK, Papoutsidakis N, Aubert G, Mazzanti A, McCanta AC, et al. Desmoplakin cardiomyopathy, a fibrotic and inflammatory form of cardiomyopathy distinct from typical dilated or arrhythmogenic right ventricular cardiomyopathy. *Circulation* 2020;**141**:1872–84. <https://doi.org/10.1161/CIRCULATIONAHA.119.044934>
98. Peretto G, De Luca G, Villatore A, Di Resta C, Sala S, Palmisano A, et al. Multimodal detection and targeting of biopsy-proven myocardial inflammation in genetic cardiomyopathies: a pilot report. *JACC Basic Transl Sci* 2023;**8**:755–65. <https://doi.org/10.1016/j.jacmts.2023.02.018>
99. Bariani R, Cipriani A, Rizzo S, Celeghin R, Bueno Marinas M, Giorgi B, et al. 'Hot phase' clinical presentation in arrhythmogenic cardiomyopathy. *Europace* 2021;**23**:907–17. <https://doi.org/10.1093/eurpace/eaab343>
100. Bariani R, Rigato I, Cipriani A, Bueno Marinas M, Celeghin R, Basso C, et al. Myocarditis-like episodes in patients with arrhythmogenic cardiomyopathy: a systematic review on the so-called hot-phase of the disease. *Biomolecules* 2022;**12**:1324. <https://doi.org/10.3390/biom12091324>
101. Bassetto G, Merlo M, Dal Ferro M, Setti M, Paldino A, Collesi C, et al. Apoptosis, a useful marker in the management of hot-phase cardiomyopathy? *Eur J Heart Fail* 2024;**26**:590–7. <https://doi.org/10.1002/ehfj.3173>
102. Collini V, Siega Vignut L, Angriman F, Braidotti G, De Biasio M, Imazio M. Age-stratified patterns in clinical presentation, treatment and outcomes in acute pericarditis: a retrospective cohort study. *Heart* 2024;**110**:1139–44. <https://doi.org/10.1136/heartjnl-2024-324214>
103. Lazaros G, Antonopoulos AS, Imazio M, Solomou E, Lazarou E, Vassilopoulos D, et al. Clinical significance of pleural effusions and association with outcome in patients hospitalized with a first episode of acute pericarditis. *Intern Emerg Med* 2019;**14**:745–51. <https://doi.org/10.1007/s11739-019-02041-3>
104. Imazio M, Pivetta E, Andreis A, Serra C, Carbone F, Masoero M, et al. Incessant pericarditis as a risk factor for complicated pericarditis and hospital admission. *Circulation* 2021;**143**:401–2. <https://doi.org/10.1161/CIRCULATIONAHA.120.051156>
105. Imazio M, Cecchi E, Demichelis B, Ierna S, Demarie D, Ghisio A, et al. Indicators of poor prognosis of acute pericarditis. *Circulation* 2007;**115**:2739–44. <https://doi.org/10.1161/CIRCULATIONAHA.106.662114>
106. Imazio M, Brucato A, Cumetti D, Brambilla G, Demichelis B, Ferro S, et al. Corticosteroids for recurrent pericarditis: high versus low doses: a nonrandomized observation. *Circulation* 2008;**118**:667–71. <https://doi.org/10.1161/CIRCULATIONAHA.107.761064>
107. Lazaros G, Antonopoulos AS, Vlachopoulos C, Oikonomou E, Karavidas A, Chrysochoou C, et al. Predictors of switching from nonsteroidal anti-inflammatory drugs to corticosteroids in patients with acute pericarditis and impact on clinical outcome. *Hellenic J Cardiol* 2019;**60**:357–63. <https://doi.org/10.1016/j.hjc.2018.04.001>
108. Melendo-Viu M, Marchán-Lopez A, Guarch CJ-L, Roubin SR, Abu-Assi E, Meneses RT, et al. A systematic review and meta-analysis of randomized controlled trials evaluating pharmacologic therapies for acute and recurrent pericarditis. *Trends Cardiovasc Med* 2023;**33**:319–26. <https://doi.org/10.1016/j.tcm.2022.02.001>
109. Artom G, Koren-Morag N, Spodick DH, Brucato A, Guindo J, Bayes-de-Luna A, et al. Pretreatment with corticosteroids attenuates the efficacy of colchicine in preventing recurrent pericarditis: a multi-centre all-case analysis. *Eur Heart J* 2005;**26**:723–27. <https://doi.org/10.1093/eurheartj/ehi197>
110. Klein AL, Wang TKM, Cremer PC, Abbate A, Adler Y, Asher C, et al. Pericardial diseases: international position statement on new concepts and advances in multimodality cardiac imaging. *JACC Cardiovasc Imaging* 2024;**17**:937–88. <https://doi.org/10.1016/j.jcmg.2024.04.010>
111. Chiabrando JG, Bonaventura A, Vecchié A, Wohlford GF, Mauro AG, Jordan JH, et al. Management of acute and recurrent pericarditis: JACC state-of-the-art review. *J Am Coll Cardiol* 2020;**75**:76–92. <https://doi.org/10.1016/j.jacc.2019.11.021>
112. Cremer PC, Tariq MU, Karwa A, Alraies MC, Benatti R, Schuster A, et al. Quantitative assessment of pericardial delayed hyperenhancement predicts clinical improvement in patients with constrictive pericarditis treated with anti-inflammatory therapy. *Circ Cardiovasc Imaging* 2015;**8**:e003125. <https://doi.org/10.1161/CIRCIMAGING.114.003125>
113. Brucato A, Brambilla G, Moreo A, Alberti A, Munforti C, Ghirardello A, et al. Long-term outcomes in difficult-to-treat patients with recurrent pericarditis. *Am J Cardiol* 2006;**98**:267–71. <https://doi.org/10.1016/j.amjcard.2006.01.086>
114. Imazio M, Brucato A, Adler Y, Brambilla G, Artom G, Cecchi E, et al. Prognosis of idiopathic recurrent pericarditis as determined from previously published reports. *Am J Cardiol* 2007;**100**:1026–8. <https://doi.org/10.1016/j.amjcard.2007.04.047>
115. Klein AL, Abbara S, Agler DA, Appleton CP, Asher CR, Hoit B, et al. American Society of Echocardiography clinical recommendations for multimodality cardiovascular imaging of patients with pericardial disease: endorsed by the Society for Cardiovascular Magnetic Resonance and Society of Cardiovascular Computed

- Tomography. *J Am Soc Echocardiogr* 2013;**26**:965–1012.e15. <https://doi.org/10.1016/j.echo.2013.06.023>
116. Miranda WR, Newman DB, Sinak LJ, Espinosa RE, Anavekar NS, Goel K, et al. Pre- and post-pericardiocentesis echo-Doppler features of effusive-constrictive pericarditis compared with cardiac tamponade and constrictive pericarditis. *Eur Heart J Cardiovasc Imaging* 2019;**20**:298–306. <https://doi.org/10.1093/ehjci/ey081>
 117. Sagristà-Sauleda J, Angel J, Sánchez A, Permyer-Miralda G, Soler-Soler J. Effusive-constrictive pericarditis. *N Engl J Med* 2004;**350**:469–75. <https://doi.org/10.1056/NEJMoa035630>
 118. Ristić AD, Imazio M, Adler Y, Anastasakis A, Badano LP, Brucato A, et al. Triage strategy for urgent management of cardiac tamponade: a position statement of the European Society of Cardiology Working Group on Myocardial and Pericardial Diseases. *Eur Heart J* 2014;**35**:2279–84. <https://doi.org/10.1093/eurheartj/ehu217>
 119. Talreja DR, Edwards WD, Danielson GK, Schaff HV, Tajik AJ, Tazelaar HD, et al. Constrictive pericarditis in 26 patients with histologically normal pericardial thickness. *Circulation* 2003;**108**:1852–7. <https://doi.org/10.1161/01.CIR.0000087606.18453.FD>
 120. Sagristà-Sauleda J, Permyer-Miralda G, Candell-Riera J, Angel J, Soler-Soler J. Transient cardiac constriction: an unrecognized pattern of evolution in effusive acute idiopathic pericarditis. *Am J Cardiol* 1987;**59**:961–6. [https://doi.org/10.1016/0002-9149\(87\)91134-9](https://doi.org/10.1016/0002-9149(87)91134-9)
 121. Haley JH, Tajik AJ, Danielson GK, Schaff HV, Mulvagh SL, Oh JK. Transient constrictive pericarditis: causes and natural history. *J Am Coll Cardiol* 2004;**43**:271–75. <https://doi.org/10.1016/j.jacc.2003.08.032>
 122. Sato K, Ayache A, Kumar A, Cremer PC, Griffin B, Popovic ZB, et al. Improvement in left ventricular mechanics following medical treatment of constrictive pericarditis. *Heart* 2021;**107**:828–35. <https://doi.org/10.1136/heartjnl-2020-317304>
 123. Feng D, Glockner J, Kim K, Martinez M, Syed IS, Araoz P, et al. Cardiac magnetic resonance imaging pericardial late gadolinium enhancement and elevated inflammatory markers can predict the reversibility of constrictive pericarditis after antiinflammatory medical therapy: a pilot study. *Circulation* 2011;**124**:1830–7. <https://doi.org/10.1161/CIRCULATIONAHA.111.026070>
 124. Cosyns B, Plein S, Nihoyanopoulos P, Smiseth O, Achenbach S, Andrade MJ, et al. European Association of Cardiovascular Imaging (EACVI) position paper: multimodality imaging in pericardial disease. *Eur Heart J Cardiovasc Imaging* 2015;**16**:12–31. <https://doi.org/10.1093/ehjci/jeu128>
 125. Lopalco G, Venerito V, Brucato A, Emmi G, Giacomelli R, Cauli A, et al. Anakinra effectiveness in refractory polyserositis: an Italian multicenter study. *Joint Bone Spine* 2022;**89**:105299. <https://doi.org/10.1016/j.jbspin.2021.105299>
 126. Kilic A, Varkal MA, Durmus MS, Yildiz I, Yildirim ZNY, Turunc G, et al. Relationship between clinical findings and genetic mutations in patients with familial Mediterranean fever. *Pediatr Rheumatol Online J* 2015;**13**:59. <https://doi.org/10.1186/s12969-015-0057-1>
 127. Kumar S, Khubber S, Reyalden R, Agrawal A, Cremer PC, Imazio M, et al. Advances in imaging and targeted therapies for recurrent pericarditis: a review. *JAMA Cardiol* 2022;**7**:975–85. <https://doi.org/10.1001/jamacardio.2022.2584>
 128. Habib G, Bucciarelli-Ducci C, Caforio ALP, Cardim N, Charron P, Cosyns B, et al. Multimodality imaging in restrictive cardiomyopathies: an EACVI expert consensus document in collaboration with the 'Working group on myocardial and pericardial diseases' of the European Society of Cardiology Endorsed by The Indian Academy of Echocardiography. *Eur Heart J Cardiovasc Imaging* 2017;**18**:1090–121. <https://doi.org/10.1093/ehjci/jex034>
 129. Imazio M, Pivetta E, Palacio Restrepo S, Sormani P, Pedrotti P, Quarta G, et al. Usefulness of cardiac magnetic resonance for recurrent pericarditis. *Am J Cardiol* 2020;**125**:146–51. <https://doi.org/10.1016/j.amjcard.2019.09.026>
 130. Imazio M, Demichelis B, Parrini I, Giuggia M, Cecchi E, Gaschino G, et al. Day-hospital treatment of acute pericarditis: a management program for outpatient therapy. *J Am Coll Cardiol* 2004;**43**:1042–46. <https://doi.org/10.1016/j.jacc.2003.09.055>
 131. Chimenti C, Russo MA, Frustaci A. Immunosuppressive therapy in virus-negative inflammatory cardiomyopathy: 20-year follow-up of the TIMIC trial. *Eur Heart J* 2022;**43**:3463–73. <https://doi.org/10.1093/eurheartj/ehac348>
 132. Rao K, De Silva K, Sood A, Denniss AR, Hsu C-J. Predicting patients with troponin positive chest pain and unobstructed coronary arteries with electrocardiogram, troponin kinetics and GRACE score. *Heart Lung Circ* 2022;**31**:1219–27. <https://doi.org/10.1016/j.hlc.2022.05.040>
 133. De Lazzari M, Zorzi A, Baritussio A, Siciliano M, Migliore F, Susana A, et al. Relationship between T-wave inversion and transmural myocardial edema as evidenced by cardiac magnetic resonance in patients with clinically suspected acute myocarditis: clinical and prognostic implications. *J Electrocardiol* 2016;**49**:587–95. <https://doi.org/10.1016/j.jelectrocard.2016.04.002>
 134. Nucifora G, Miani D, Di Chiara A, Piccoli G, Artico J, Puppato M, et al. Infarct-like acute myocarditis: relation between electrocardiographic findings and myocardial damage as assessed by cardiac magnetic resonance imaging. *Clin Cardiol* 2013;**36**:146–52. <https://doi.org/10.1002/clc.22088>
 135. Wang Z, Wang Y, Lin H, Wang S, Cai X, Gao D. Early characteristics of fulminant myocarditis vs non-fulminant myocarditis: a meta-analysis. *Medicine (Baltimore)* 2019;**98**:e14697. <https://doi.org/10.1097/MD.00000000000014697>
 136. Ukena C, Mahfoud F, Kindermann I, Kandolf R, Kindermann M, Böhm M. Prognostic electrocardiographic parameters in patients with suspected myocarditis. *Eur J Heart Fail* 2011;**13**:398–405. <https://doi.org/10.1093/eurjhf/hfq229>
 137. Jhamnani S, Fuisz A, Lindsay J. The spectrum of electrocardiographic manifestations of acute myocarditis: an expanded understanding. *J Electrocardiol* 2014;**47**:941–7. <https://doi.org/10.1016/j.jelectrocard.2014.07.018>
 138. Baritussio A, Cheng C-Y, Lorenzoni G, Basso C, Rizzo S, De Gaspari M, et al. A machine-learning model for the prognostic role of C-reactive protein in myocarditis. *J Clin Med* 2022;**11**:7068. <https://doi.org/10.3390/jcm11237068>
 139. Lazaros G, Vlachakis PK, Theofilis P, Dasoula FE, Imazio M, Lazarou E, et al. D-dimer as a diagnostic and prognostic plasma biomarker in patients with a first episode of acute pericarditis. *Eur J Intern Med* 2023;**19**:2133–9. <https://doi.org/10.1016/j.ejim.2023.06.017>
 140. Mauro A, Bizzi E, Wu MA, Mascolo R, Chirico C, Conte E, et al. D-dimer and procalcitonin in patients with recurrent pericarditis: a prospective study. *Intern Emerg Med* 2024;**19**:2133–9. <https://doi.org/10.1007/s11739-024-03712-6>
 141. Blanco-Domínguez R, Sánchez-Díaz R, de la Fuente H, Jiménez-Borreguero LJ, Matesanz-Marín A, Reláño M, et al. A novel circulating microRNA for the detection of acute myocarditis. *N Engl J Med* 2021;**384**:2014–27. <https://doi.org/10.1056/NEJMoa2003608>
 142. Caforio ALP, De Luca G, Baritussio A, Seguso M, Gallo N, Bison E, et al. Serum organ-specific anti-heart and anti-intercalated disk autoantibodies as new autoimmune markers of cardiac involvement in systemic sclerosis: frequency, clinical and prognostic correlates. *Diagnostics (Basel)* 2021;**11**:2165. <https://doi.org/10.3390/diagnostics11112165>
 143. Coronado MJ, Bruno KA, Blauwet LA, Tschöpe C, Cunningham MW, Pankuweit S, et al. Elevated sera sST2 is associated with heart failure in men <50 years old with myocarditis. *J Am Heart Assoc* 2019;**8**:e008968. <https://doi.org/10.1161/JAHA.118.008968>
 144. Müller I, Vogl T, Kühl U, Krannich A, Banks A, Trippel T, et al. Serum alarmin S100A8/S100A9 levels and its potential role as biomarker in myocarditis. *ESC Heart Fail* 2020;**7**:1442–51. <https://doi.org/10.1002/ehf2.12760>
 145. Müller I, Vogl T, Pappritz K, Miteva K, Savvatis K, Rohde D, et al. Pathogenic role of the damage-associated molecular patterns S100A8 and S100A9 in Coxsackievirus B3-induced myocarditis. *Circ Heart Fail* 2017;**10**:e004125. <https://doi.org/10.1161/CIRCHEARTFAILURE.117.004125>
 146. Ader F, Surget E, Charron P, Redheuil A, Zouaghi A, Maltret A, et al. Inherited cardiomyopathies revealed by clinically suspected myocarditis: highlights from genetic testing. *Circ Genom Precis Med* 2020;**13**:e002744. <https://doi.org/10.1161/CIRCGEN.119.002744>
 147. Poller W, Haas J, Klingel K, Kühnisch J, Gast M, Kaya Z, et al. Familial recurrent myocarditis triggered by exercise in patients with a truncating variant of the desmoplakin gene. *J Am Heart Assoc* 2020;**9**:e015289. <https://doi.org/10.1161/JAHA.119.015289>
 148. Ollitrault P, Al Khoury M, Troadeq Y, Calcagno Y, Champ-Rigot L, Ferchoud V, et al. Recurrent acute myocarditis: an under-recognized clinical entity associated with the later diagnosis of a genetic arrhythmogenic cardiomyopathy. *Front Cardiovasc Med* 2022;**9**:998883. <https://doi.org/10.3389/fcvm.2022.998883>
 149. Piriou N, Marteau L, Kyndt F, Serfaty JM, Toquet C, Le Gloan L, et al. Familial screening in case of acute myocarditis reveals inherited arrhythmogenic left ventricular cardiomyopathies. *ESC Heart Fail* 2020;**7**:1520–33. <https://doi.org/10.1002/ehf2.12686>
 150. Artico J, Merlo M, Delcaro G, Cannatà A, Gentile P, De Angelis G, et al. Lymphocytic myocarditis: a genetically predisposed disease? *J Am Coll Cardiol* 2020;**75**:3098–100. <https://doi.org/10.1016/j.jacc.2020.04.048>
 151. Verdonschot JA, Heymans SRB. Dilated cardiomyopathy: second hits knock-down the heart. *Eur Heart J* 2024;**45**:500–1. <https://doi.org/10.1093/eurheartj/ehad778>
 152. Cantarini L, Lucherini OM, Brucato A, Barone L, Cumetti D, Iacoponi F, et al. Clues to detect tumor necrosis factor receptor-associated periodic syndrome (TRAPS) among patients with idiopathic recurrent acute pericarditis: results of a multicentre study. *Clin Res Cardiol* 2012;**101**:525–31. <https://doi.org/10.1007/s00392-012-0422-8>
 153. Brucato A, Shinar Y, Brambilla G, Robbiolo L, Ferrioli G, Patrosso MC, et al. Idiopathic recurrent acute pericarditis: familial Mediterranean fever mutations and disease evolution in a large cohort of Caucasian patients. *Lupus* 2005;**14**:670–4. <https://doi.org/10.1191/0961203305lu2197oa>
 154. Felker GM, Boehmer JP, Hubran RH, Hutchins GM, Kasper EK, Baughman KL, et al. Echocardiographic findings in fulminant and acute myocarditis. *J Am Coll Cardiol* 2000;**36**:227–32. [https://doi.org/10.1016/s0735-1097\(00\)00690-2](https://doi.org/10.1016/s0735-1097(00)00690-2)
 155. Pinamonti B, Alberti E, Cigalotto A, Dreas L, Salvi A, Silvestri F, et al. Echocardiographic findings in myocarditis. *Am J Cardiol* 1988;**62**:285–91. [https://doi.org/10.1016/0002-9149\(88\)90226-3](https://doi.org/10.1016/0002-9149(88)90226-3)
 156. Uppu SC, Shah A, Weigand J, Nielsen JC, Ko HH, Parness IA, et al. Two-dimensional speckle-tracking-derived segmental peak systolic longitudinal strain identifies regional myocardial involvement in patients with myocarditis and normal global left ventricular systolic function. *Pediatr Cardiol* 2015;**36**:950–9. <https://doi.org/10.1007/s00246-015-1105-9>
 157. Sperlongano S, D'Amato A, Tagliamonte E, Russo V, Desiderio A, Iardi F, et al. Acute myocarditis: prognostic role of speckle tracking echocardiography and comparison with cardiac magnetic resonance features. *Heart Vessels* 2022;**37**:121–31. <https://doi.org/10.1007/s00380-021-01893-0>

158. Ben-Joya D, Kaplan A, Baruch G, Rothschild E, Beer G, Banai S, et al. The prevalence of abnormal right ventricle speckle strain in the setting of acute myocarditis and preserved left ventricle function. *Int J Cardiovasc Imaging* 2023;**39**:1231–8. <https://doi.org/10.1007/s10554-023-02829-7>
159. Meindl C, Paulus M, Poschenrieder F, Hamer OW, Zeman F, Maier LS, et al. Left atrial strain parameters derived by echocardiography are impaired in patients with acute myocarditis and preserved systolic left ventricular function. *Int J Cardiovasc Imaging* 2023;**39**:1157–65. <https://doi.org/10.1007/s10554-023-02827-9>
160. Imazio M, Bobbio M, Cecchi E, Demarie D, Demichelis B, Pomari F, et al. Colchicine in addition to conventional therapy for acute pericarditis: results of the COlchicine for acute PEricarditis (COPE) trial. *Circulation* 2005;**112**:2012–6. <https://doi.org/10.1161/CIRCULATIONAHA.105.542738>
161. Iles LM, Ellims AH, Llewellyn H, Hare JL, Kaye DM, McLean CA, et al. Histological validation of cardiac magnetic resonance analysis of regional and diffuse interstitial myocardial fibrosis. *Eur Heart J Cardiovasc Imaging* 2015;**16**:14–22. <https://doi.org/10.1093/ehjci/jeu182>
162. Miller CA, Naish JH, Bishop P, Coutts G, Clark D, Zhao S, et al. Comprehensive validation of cardiovascular magnetic resonance techniques for the assessment of myocardial extracellular volume. *Circ Cardiovasc Imaging* 2013;**6**:373–83. <https://doi.org/10.1161/CIRCIMAGING.112.000192>
163. Voigt A, Elgeti T, Durmus T, Idiz ME, Butler C, Beling M, et al. Cardiac magnetic resonance imaging in dilated cardiomyopathy in adults—towards identification of myocardial inflammation. *Eur Radiol* 2011;**21**:925–35. <https://doi.org/10.1007/s00330-010-1985-2>
164. Lurz P, Luecke C, Eitel I, Föhrenbach F, Frank C, Grothoff M, et al. Comprehensive cardiac magnetic resonance imaging in patients with suspected myocarditis: the MyoRacer-Trial. *J Am Coll Cardiol* 2016;**67**:1800–11. <https://doi.org/10.1016/j.jacc.2016.02.013>
165. Zurick AO, Bolen MA, Kwon DH, Tan CD, Popovic ZB, Rajeswaran J, et al. Pericardial delayed hyperenhancement with CMR imaging in patients with constrictive pericarditis undergoing surgical pericardiectomy: a case series with histopathological correlation. *JACC Cardiovasc Imaging* 2011;**4**:1180–91. <https://doi.org/10.1016/j.jcmg.2011.08.011>
166. Kramer CM, Barkhausen J, Bucciarelli-Ducci C, Flamm SD, Kim RJ, Nagel E. Standardized cardiovascular magnetic resonance imaging (CMR) protocols: 2020 update. *J Cardiovasc Magn Reson* 2020;**22**:17. <https://doi.org/10.1186/s12968-020-00607-1>
167. Muehlberg F, Blaszczyk E, Will K, Wilczek S, Brederlau J, Schulz-Menger J. Characterization of critically ill patients with septic shock and sepsis-associated cardiomyopathy using cardiovascular MRI. *ESC Heart Fail* 2022;**9**:2147–56. <https://doi.org/10.1002/ehf2.13938>
168. Gröschel J, Ammann C, Zange L, Viezzer D, Forman C, Schmidt M, et al. Fast acquisition of left and right ventricular function parameters applying cardiovascular magnetic resonance in clinical routine—validation of a 2-shot compressed sensing cine sequence. *Scand Cardiovasc J* 2022;**56**:266–75. <https://doi.org/10.1080/14017431.2022.2099010>
169. Mileva N, Paolisso P, Gallinoro E, Fabricatore D, Munhoz D, Bergamaschi L, et al. Diagnostic and prognostic role of cardiac magnetic resonance in MINOCA: systematic review and meta-analysis. *JACC Cardiovasc Imaging* 2023;**16**:376–89. <https://doi.org/10.1016/j.jcmg.2022.12.029>
170. Machanahalli Balakrishna A, Ismayl M, Thandra A, Walters R, Ganesan V, Anugula D, et al. Diagnostic value of cardiac magnetic resonance imaging and intracoronary optical coherence tomography in patients with a working diagnosis of myocardial infarction with non-obstructive coronary arteries—a systematic review and meta-analysis. *Curr Probl Cardiol* 2023;**48**:101126. <https://doi.org/10.1016/j.cpcardiol.2022.101126>
171. Hausvater A, Smilowitz NR, Li B, Redel-Traub G, Quien M, Qian Y, et al. Myocarditis in relation to angiographic findings in patients with provisional diagnoses of MINOCA. *JACC Cardiovasc Imaging* 2020;**13**:1906–13. <https://doi.org/10.1016/j.jcmg.2020.02.037>
172. Tornvall P, Gerbaud E, Behaghel A, Chopard R, Collste O, Larauodogoitia E, et al. Myocarditis or 'true' infarction by cardiac magnetic resonance in patients with a clinical diagnosis of myocardial infarction without obstructive coronary disease: a meta-analysis of individual patient data. *Atherosclerosis* 2015;**241**:87–91. <https://doi.org/10.1016/j.atherosclerosis.2015.04.816>
173. Bohnen S, Radunski UK, Lund GK, Kandolf R, Stehning C, Schnackenburg B, et al. Performance of T1 and T2 mapping cardiovascular magnetic resonance to detect active myocarditis in patients with recent-onset heart failure. *Circ Cardiovasc Imaging* 2015;**8**:e003073. <https://doi.org/10.1161/CIRCIMAGING.114.003073>
174. Khanna S, Amarasekera AT, Li C, Bhat A, Chen HHL, Gan GCH, et al. The utility of cardiac magnetic resonance imaging in the diagnosis of adult patients with acute myocarditis: a systematic review and meta-analysis. *Int J Cardiol* 2022;**363**:225–39. <https://doi.org/10.1016/j.ijcard.2022.06.047>
175. Jia Z, Wang L, Jia Y, Liu J, Zhao H, Huo L, et al. Detection of acute myocarditis using T1 and T2 mapping cardiovascular magnetic resonance: a systematic review and meta-analysis. *J Appl Clin Med Phys* 2021;**22**:239–48. <https://doi.org/10.1002/acm2.13365>
176. Blissett S, Chocron Y, Kovacina B, Afilalo J. Diagnostic and prognostic value of cardiac magnetic resonance in acute myocarditis: a systematic review and meta-analysis. *Int J Cardiovasc Imaging* 2019;**35**:2221–9. <https://doi.org/10.1007/s10554-019-01674-x>
177. Pan JA, Lee YJ, Salerno M. Diagnostic performance of extracellular volume, native T1, and T2 mapping versus Lake Louise criteria by cardiac magnetic resonance for detection of acute myocarditis: a meta-analysis. *Circ Cardiovasc Imaging* 2018;**11**:e007598. <https://doi.org/10.1161/CIRCIMAGING.118.007598>
178. Wei S, Fu J, Chen L, Yu S. Performance of cardiac magnetic resonance imaging for diagnosis of myocarditis compared with endomyocardial biopsy: a meta-analysis. *Med Sci Monit* 2017;**23**:3687–96. <https://doi.org/10.12659/msm.902155>
179. Greenwood JP, Maredia N, Younger JF, Brown JM, Nixon J, Everett CC, et al. Cardiovascular magnetic resonance and single-photon emission computed tomography for diagnosis of coronary heart disease (CE-MARC): a prospective trial. *Lancet* 2012;**379**:453–60. [https://doi.org/10.1016/S0140-6736\(11\)61335-4](https://doi.org/10.1016/S0140-6736(11)61335-4)
180. Greenwood JP, Ripley DP, Bery C, McCann GP, Plein S, Bucciarelli-Ducci C, et al. Effect of care guided by cardiovascular magnetic resonance, myocardial perfusion scintigraphy, or NICE guidelines on subsequent unnecessary angiography rates: the CE-MARC 2 randomized clinical trial. *JAMA* 2016;**316**:1051–60. <https://doi.org/10.1001/jama.2016.12680>
181. Nagel E, Greenwood JP, McCann GP, Bettencourt N, Shah AM, Hussain ST, et al. Magnetic resonance perfusion or fractional flow reserve in coronary disease. *N Engl J Med* 2019;**380**:2418–28. <https://doi.org/10.1056/NEJMoa1716734>
182. Arai AE, Schulz-Menger J, Berman D, Mahrholdt H, Han Y, Bandettini WP, et al. Gadobutrol-enhanced cardiac magnetic resonance imaging for detection of coronary artery disease. *J Am Coll Cardiol* 2020;**76**:1536–47. <https://doi.org/10.1016/j.jacc.2020.07.060>
183. Kwong RY, Ge Y, Steel K, Bingham S, Abdullah S, Fujikura K, et al. Cardiac magnetic resonance stress perfusion imaging for evaluation of patients with chest pain. *J Am Coll Cardiol* 2019;**74**:1741–55. <https://doi.org/10.1016/j.jacc.2019.07.074>
184. Bohm P, Scharhag J, Meyer T. Data from a nationwide registry on sports-related sudden cardiac deaths in Germany. *Eur J Prev Cardiol* 2016;**23**:649–56. <https://doi.org/10.1177/2047487315594087>
185. Pelliccia A, Solberg EE, Papadakis M, Adami PE, Biffi A, Caselli S, et al. Recommendations for participation in competitive and leisure time sport in athletes with cardiomyopathies, myocarditis, and pericarditis: position statement of the Sport Cardiology Section of the European Association of Preventive Cardiology (EAPC). *Eur Heart J* 2019;**40**:19–33. <https://doi.org/10.1093/eurheartj/ehy730>
186. Maron BJ, Udelson JE, Bonow RO, Nishimura RA, Ackerman MJ, Estes NAM, et al. Eligibility and disqualification recommendations for competitive athletes with cardiovascular abnormalities: Task Force 3: hypertrophic cardiomyopathy, arrhythmogenic right ventricular cardiomyopathy and other cardiomyopathies, and myocarditis: a scientific statement from the American Heart Association and American College of Cardiology. *Circulation* 2015;**132**:e273–80. <https://doi.org/10.1161/CIR.0000000000000239>
187. Sechtem U, Tscholakoff D, Higgins CB. MRI of the normal pericardium. *AJR Am J Roentgenol* 1986;**147**:239–44. <https://doi.org/10.2214/ajr.147.2.239>
188. Stark DD, Higgins CB, Lanzer P, Lipton MJ, Schiller N, Crooks LE, et al. Magnetic resonance imaging of the pericardium: normal and pathologic findings. *Radiology* 1984;**150**:469–74. <https://doi.org/10.1148/radiology.150.2.6691103>
189. Tscholakoff D, Sechtem U, de Geer G, Schmidt H, Higgins CB. Evaluation of pleural and pericardial effusions by magnetic resonance imaging. *Eur J Radiol* 1987;**7**:169–74.
190. Power JA, Thompson DV, Rayarao G, Doyle M, Biederman RWW. Cardiac magnetic resonance radiofrequency tissue tagging for diagnosis of constrictive pericarditis: a proof of concept study. *J Thorac Cardiovasc Surg* 2016;**151**:1348–55. <https://doi.org/10.1016/j.jtcvs.2015.12.035>
191. Gastl M, Sokolska JM, Polacin M, Gotschy A, von Spiczak Brzezinski J, Alkadhhi H, et al. Parametric mapping CMR for the measurement of inflammatory reactions of the pericardium. *Open Heart* 2022;**9**:e001919. <https://doi.org/10.1136/openhrt-2021-001919>
192. Conte E, Agalbatto C, Lauri G, Mushtaq S, Cia AD, Bonomi A, et al. Cardiac MRI after first episode of acute pericarditis: a pilot study for better identification of high risk patients. *Int J Cardiol* 2022;**354**:63–7. <https://doi.org/10.1016/j.ijcard.2022.03.007>
193. Young PM, Glockner JF, Williamson EE, Morris MF, Araoz PA, Julsrud PR, et al. MR imaging findings in 76 consecutive surgically proven cases of pericardial disease with CT and pathologic correlation. *Int J Cardiovasc Imaging* 2012;**28**:1099–109. <https://doi.org/10.1007/s10554-011-9916-0>
194. Taylor AM, Dymarkowski S, Verbeken EK, Bogaert J. Detection of pericardial inflammation with late-enhancement cardiac magnetic resonance imaging: initial results. *Eur Radiol* 2006;**16**:569–74. <https://doi.org/10.1007/s00330-005-0025-0>
195. Knuuti J, Wijns W, Saraste A, Capodanno D, Barbato E, Funck-Brentano C, et al. 2019 ESC guidelines for the diagnosis and management of chronic coronary syndromes. *Eur Heart J* 2020;**41**:407–77. <https://doi.org/10.1093/eurheartj/ehz425>
196. Maggiolini S, De Carlini CC, Ferri LA, Colombo GI, Gentile G, Meles E, et al. The role of early contrast-enhanced chest computed tomography in the aetiological diagnosis of patients presenting with cardiac tamponade or large pericardial effusion. *Eur Heart J Cardiovasc Imaging* 2016;**17**:421–8. <https://doi.org/10.1093/ehjci/jev225>
197. Lee Y-H, Kim SM, Kim EK, Park S-J, Lee S-C, Park SW, et al. Pattern of pericardial calcification determines mid-term postoperative outcomes after pericardiectomy in

- chronic constrictive pericarditis. *Int J Cardiol* 2023;**387**:131133. <https://doi.org/10.1016/j.ijcard.2023.131133>
198. Conte E, Agalato C, Lauri G, Mushtaq S, Carollo C, Bonomi A, et al. Prevalence and prognosis of pericardial effusion in patients affected by pectus excavatum: a case-control study. *Int J Cardiol* 2021;**344**:179–83. <https://doi.org/10.1016/j.ijcard.2021.10.005>
 199. Bogaert J, Meyns B, Dymarkowski S, Sinnaeve P, Meuris B. Calcified constrictive pericarditis: prevalence, distribution patterns, and relationship to the myocardium. *JACC Cardiovasc Imaging* 2016;**9**:1013–4. <https://doi.org/10.1016/j.jcmg.2015.08.011>
 200. Azzu A, Morosin M, Antonopoulos AS, Capoccia M, Rosendahl U, Mohiaddin R. Cardiac decompression by pericardiectomy for constrictive pericarditis: multimodality imaging to identify patients at risk for prolonged inotropic support. *J Cardiovasc Imaging* 2021;**29**:361–72. <https://doi.org/10.4250/jcvi.2020.0223>
 201. Peretto G, Busnardo E, Ferro P, Palmisano A, Vignale D, Esposito A, et al. Clinical applications of FDG-PET scan in arrhythmic myocarditis. *JACC Cardiovasc Imaging* 2022;**15**:1771–80. <https://doi.org/10.1016/j.jcmg.2022.02.029>
 202. Palmisano A, Vignale D, Peretto G, Busnardo E, Calcagno C, Campochiaro C, et al. Hybrid FDG-PET/MR or FDG-PET/CT to detect disease activity in patients with persisting arrhythmias after myocarditis. *JACC Cardiovasc Imaging* 2021;**14**:288–92. <https://doi.org/10.1016/j.jcmg.2020.03.009>
 203. Hanneman K, Kadoch M, Guo HH, Jamal M, Quon A, Igaru A, et al. Initial experience with simultaneous 18F-FDG PET/MRI in the evaluation of cardiac sarcoidosis and myocarditis. *Clin Nucl Med* 2017;**42**:e328–34. <https://doi.org/10.1097/RLU.0000000000001669>
 204. Chareonthaitawee P, Beanlands RS, Chen W, Dorbala S, Miller EJ, Murthy VL, et al. Joint SNMMI-ASNC expert consensus document on the role of ¹⁸F-FDG PET/CT in cardiac sarcoid detection and therapy monitoring. *J Nucl Med* 2017;**58**:1341–53. <https://doi.org/10.2967/jnumed.117.196287>
 205. Salomäki SP, Hohenthal U, Kempainen J, Pirilä L, Saraste A. Visualization of pericarditis by fluorodeoxyglucose PET. *Eur Heart J Cardiovasc Imaging* 2014;**15**:291. <https://doi.org/10.1093/ehjci/jet179>
 206. Nensa F, Kloth J, Tezghah E, Poeppel TD, Heusch P, Goebel J, et al. Feasibility of FDG-PET in myocarditis: comparison to CMR using integrated PET/MRI. *J Nucl Cardiol* 2018;**25**:785–94. <https://doi.org/10.1007/s12350-016-0616-y>
 207. Basso C, Calabrese F, Angelini A, Carturan E, Thiene G. Classification and histological, immunohistochemical, and molecular diagnosis of inflammatory myocardial disease. *Heart Fail Rev* 2013;**18**:673–81. <https://doi.org/10.1007/s10741-012-9355-6>
 208. Murphy L, McGuckin M, Giblin G, Keogh A, McGovern B, Fabre A, et al. The role of endomyocardial biopsy in suspected myocarditis in the contemporary era: a 10-year National Transplant Centre experience. *Cardiovasc Pathol* 2021;**54**:107366. <https://doi.org/10.1016/j.carpath.2021.107366>
 209. Lu ZA, Aubry MC, Fallon JT, Fishbein MC, Giordano C, Klingel K, et al. Myocarditis and endomyocardial biopsy: achieving consensus diagnosis on 100 cases. *Cardiovasc Pathol* 2023;**62**:107492. <https://doi.org/10.1016/j.carpath.2022.107492>
 210. Seferović PM, Tsutsui H, McNamara DM, Ristić AD, Basso C, Bozkurt B, et al. Heart Failure Association of the ESC, Heart Failure Society of America and Japanese Heart Failure Society position statement on endomyocardial biopsy. *Eur J Heart Fail* 2021;**23**:854–71. <https://doi.org/10.1002/ejhf.2190>
 211. Yılmaz A, Kindermann I, Kindermann M, Mahfoud F, Ukena C, Athanasiadis A, et al. Comparative evaluation of left and right ventricular endomyocardial biopsy: differences in complication rate and diagnostic performance. *Circulation* 2010;**122**:900–9. <https://doi.org/10.1161/CIRCULATIONAHA.109.924167>
 212. van der Boon R, den Dekker W, Meuwese CL, Lorusso R, von der Thüsen J, Constantinescu AC, et al. Safety of endomyocardial biopsy in new-onset acute heart failure requiring veno-arterial extracorporeal membrane oxygenation. *Circ Heart Fail* 2021;**14**:e008387. <https://doi.org/10.1161/CIRCHEARTFAILURE.121.008387>
 213. Mueller GC, Michel-Behnke I, Knirsch W, Haas NA, Abdul-Khaliq H, Gitter R, et al. Feasibility, safety and diagnostic impact of endomyocardial biopsies for the diagnosis of myocardial disease in children and adolescents. *EuroIntervention* 2018;**14**:1089–95. <https://doi.org/10.4244/EIJ-D-18-00128>
 214. De Gaspari M, Larsen BT, d'Amati G, Kreutz K, Basso C, Michaud K, et al. Diagnosing myocarditis in endomyocardial biopsies: survey of current practice. *Cardiovasc Pathol* 2023;**64**:107494. <https://doi.org/10.1016/j.carpath.2022.107494>
 215. Gartshteyn Y, Tamargo M, Fleischer S, Kapoor T, Li J, Askanase A, et al. Endomyocardial biopsies in the diagnosis of myocardial involvement in systemic lupus erythematosus. *Lupus* 2020;**29**:199–204. <https://doi.org/10.1177/0961203319897116>
 216. Heymans S, Lakdawala NK, Tschöpe C, Klingel K. Dilated cardiomyopathy: causes, mechanisms, and current and future treatment approaches. *Lancet* 2023;**402**:998–1011. [https://doi.org/10.1016/S0140-6736\(23\)01241-2](https://doi.org/10.1016/S0140-6736(23)01241-2)
 217. Kandolin R, Lehtonen J, Salmenkivi K, Räisänen-Sokolowski A, Lommi J, Kupari M. Diagnosis, treatment, and outcome of giant-cell myocarditis in the era of combined immunosuppression. *Circ Heart Fail* 2013;**6**:15–22. <https://doi.org/10.1161/CIRCHEARTFAILURE.112.969261>
 218. Casella M, Dello Russo A, Bergonti M, Catto V, Conte E, Sommariva E, et al. Diagnostic yield of electroanatomic voltage mapping in guiding endomyocardial biopsies. *Circulation* 2020;**142**:1249–60. <https://doi.org/10.1161/CIRCULATIONAHA.120.046900>
 219. Casella M, Pizzamiglio F, Dello Russo A, Carbucicchio C, Al-Mohani G, Russo E, et al. Feasibility of combined unipolar and bipolar voltage maps to improve sensitivity of endomyocardial biopsy. *Circ Arrhythm Electrophysiol* 2015;**8**:625–32. <https://doi.org/10.1161/CIRCEP.114.002216>
 220. Ezzeddine FM, Kapa S, Rosenbaum A, Blauwet L, Deshmukh AJ, AbouEzzeddine OF, et al. Electrogram-guided endomyocardial biopsy yield in patients with suspected cardiac sarcoidosis and relation to outcomes. *J Cardiovasc Electrophysiol* 2021;**32**:2486–95. <https://doi.org/10.1111/jce.15191>
 221. Vaidya VR, Abudan AA, Vasudevan K, Shantha G, Cooper LT, Kapa S, et al. The efficacy and safety of electroanatomic mapping-guided endomyocardial biopsy: a systematic review. *J Interv Card Electrophysiol* 2018;**53**:63–71. <https://doi.org/10.1007/s10840-018-0410-7>
 222. Pelargonio G, Pinnacchio G, Narducci ML, Pieroni M, Perna F, Bencardino G, et al. Long-term arrhythmic risk assessment in biopsy-proven myocarditis. *JACC Clin Electrophysiol* 2020;**6**:574–82. <https://doi.org/10.1016/j.jacep.2019.12.010>
 223. Aretz HT, Billingham ME, Edwards WD, Factor SM, Fallon JT, Fenoglio JJ, et al. Myocarditis. A histopathologic definition and classification. *Am J Cardiovasc Pathol* 1987;**1**:3–14.
 224. Schnitt SJ, Ciano PS, Schoen FJ. Quantitation of lymphocytes in endomyocardial biopsies: use and limitations of antibodies to leukocyte common antigen. *Hum Pathol* 1987;**18**:796–800. [https://doi.org/10.1016/s0046-8177\(87\)80053-9](https://doi.org/10.1016/s0046-8177(87)80053-9)
 225. Linder J, Cassling RS, Rogler WC, Wilson JE, Markin RS, Sears TD, et al. Immunohistochemical characterization of lymphocytes in uninfamed ventricular myocardium. Implications for myocarditis. *Arch Pathol Lab Med* 1985;**109**:917–20.
 226. Ohta-Ogo K, Sugano Y, Ogata S, Nakayama T, Komori T, Eguchi K, et al. Myocardial T-lymphocytes as a prognostic risk-stratifying marker of dilated cardiomyopathy—results of the multicenter registry to investigate inflammatory cell infiltration in dilated cardiomyopathy in tissues of endomyocardial biopsy (INDICATE study). *Circ J* 2022;**86**:1092–101. <https://doi.org/10.1253/circj.CJ-21-0529>
 227. Katzmann JL, Schlattmann P, Rigopoulos AG, Noutsias E, Bigalke B, Pauschinger M, et al. Meta-analysis on the immunohistological detection of inflammatory cardiomyopathy in endomyocardial biopsies. *Heart Fail Rev* 2020;**25**:277–94. <https://doi.org/10.1007/s10741-019-09835-9>
 228. Pelz L, Mantino S, Sauter M, Manuylova T, Vogel U, Klingel K. Lymphocytic myocarditis in children with parvovirus B19 infection: pathological and molecular insights. *Biomedicines* 2024;**12**:1909. <https://doi.org/10.3390/biomedicines12081909>
 229. Stiermaier T, Föhrenbach F, Klingel K, Kandolf R, Boudriot E, Sandri M, et al. Biventricular endomyocardial biopsy in patients with suspected myocarditis: feasibility, complication rate and additional diagnostic value. *Int J Cardiol* 2017;**230**:364–70. <https://doi.org/10.1016/j.ijcard.2016.12.103>
 230. Mahfoud F, Gärtner B, Kindermann M, Ukena C, Gadowski K, Klingel K, et al. Virus serology in patients with suspected myocarditis: utility or futility? *Eur Heart J* 2011;**32**:897–903. <https://doi.org/10.1093/eurheartj/ehq493>
 231. Heidecker B, Williams SH, Jain K, Oleynik A, Patriki D, Kottwitz J, et al. Virome sequencing in patients with myocarditis. *Circ Heart Fail* 2020;**13**:e007103. <https://doi.org/10.1161/CIRCHEARTFAILURE.120.007103>
 232. Maisch B, Rupp H, Ristic A, Pankuweit S. Pericardioscopy and epi- and pericardial biopsy—a new window to the heart improving etiological diagnoses and permitting targeted intrapericardial therapy. *Heart Fail Rev* 2013;**18**:317–28. <https://doi.org/10.1007/s10741-013-9382-y>
 233. Ding X, Yang M, Wang Y, Wu S, Qiu X, Liu Q. Retrospective analysis of 769 cases of sudden cardiac death from 2006 to 2015: a forensic experience in China. *Forensic Sci Med Pathol* 2017;**13**:336–41. <https://doi.org/10.1007/s12024-017-9888-z>
 234. Vassalini M, Verzeletti A, Restori M, De Ferrari F. An autopsy study of sudden cardiac death in persons aged 1–40 years in Brescia (Italy). *J Cardiovasc Med (Hagerstown)* 2016;**17**:446–53. <https://doi.org/10.2459/JCM.0000000000000234>
 235. Wu Y, Ai M, Bardeesi ASA, Zhang L, Wu Q, Yin K, et al. The forensic pathological analysis of sport-related sudden cardiac death in Southern China. *Forensic Sci Res* 2020;**5**:47–54. <https://doi.org/10.1080/20961790.2017.1319785>
 236. Wang H, Yao Q, Zhu S, Zhang G, Wang Z, Li Z, et al. The autopsy study of 553 cases of sudden cardiac death in Chinese adults. *Heart Vessels* 2014;**29**:486–95. <https://doi.org/10.1007/s00380-013-0388-0>
 237. Doolan A, Langlois N, Semsarian C. Causes of sudden cardiac death in young Australians. *Med J Aust* 2004;**180**:110–2. <https://doi.org/10.5694/j.1326-5377.2004.tb05830.x>
 238. Harris KM, Mackey-Bojack S, Bennett M, Nwaudo D, Duncanson E, Maron BJ. Sudden unexpected death due to myocarditis in young people, including athletes. *Am J Cardiol* 2021;**143**:131–4. <https://doi.org/10.1016/j.amjcard.2020.12.028>
 239. Basso C, Aguilera B, Banner J, Kohle S, d'Amati G, de Gouveia RH, et al. Guidelines for autopsy investigation of sudden cardiac death: 2017 update from the Association for European Cardiovascular Pathology. *Virchows Arch* 2017;**471**:691–705. <https://doi.org/10.1007/s00428-017-2221-0>
 240. Ekström K, Lehtonen J, Nordenswan H-K, Mäyränpää MI, Räisänen-Sokolowski A, Kandolin R, et al. Sudden death in cardiac sarcoidosis: an analysis of nationwide clinical and cause-of-death registries. *Eur Heart J* 2019;**40**:3121–8. <https://doi.org/10.1093/eurheartj/ehz428>

241. Ackerman MJ, Priori SG, Willems S, Berul C, Brugada R, Calkins H, et al. HRS/EHRA expert consensus statement on the state of genetic testing for the channelopathies and cardiomyopathies. This document was developed as a partnership between the Heart Rhythm Society (HRS) and the European Heart Rhythm Association (EHRA). *Heart Rhythm* 2011;**8**:1308–39. <https://doi.org/10.1016/j.hrthm.2011.05.020>
242. Wilhelm M, Bolliger SA, Bartsch C, Fokstuen S, Gräni C, Martos V, et al. Sudden cardiac death in forensic medicine—Swiss recommendations for a multidisciplinary approach. *Swiss Med Wkly* 2015;**145**:w14129. <https://doi.org/10.4414/sm.w.2015.14129>
243. de Noronha SV, Behr ER, Papadakis M, Ohta-Ogo K, Banya W, Wells J, et al. The importance of specialist cardiac histopathological examination in the investigation of young sudden cardiac deaths. *Europace* 2014;**16**:899–907. <https://doi.org/10.1093/europace/eut329>
244. De Gaspari M, Fedeli U, Saia M, Carturan E, Pilichou K, Corrado D, et al. Rate and cause of sudden cardiac death in the young during the COVID-19 pandemic and vaccination. *Circulation* 2023;**148**:2069–71. <https://doi.org/10.1161/CIRCULATIONAHA.123.066270>
245. du Long R, Fronczek J, Niessen HWM, van der Wal A, de Boer H. The histopathological spectrum of myocardial inflammation in relation to circumstance of death: a retrospective cohort study in clinical and forensic autopsies. *Forensic Sci Res* 2022;**7**:238–46. <https://doi.org/10.1080/20961790.2021.1989793>
246. Li L, Zhang Y, Burke A, Xue A, Zhao Z, Fowler D, et al. Demographic, clinical and pathological features of sudden deaths due to myocarditis: results from a state-wide population-based autopsy study. *Forensic Sci Int* 2017;**272**:81–6. <https://doi.org/10.1016/j.forsciint.2016.12.037>
247. Gulino SP, Burns K, Gunther WM, MacLeod H. Improving forensic pathologic investigation of sudden death in the young: tools, guidance, and methods of cardiovascular dissection from the sudden death in the young case registry. *Acad Forensic Pathol* 2018;**8**:347–91. <https://doi.org/10.1177/1925362118782077>
248. Vrints C, Andreotti F, Koskinas KC, Rossello X, Adamo M, Ainslie J, et al. 2024 ESC guidelines for the management of chronic coronary syndromes. *Eur Heart J* 2024;**45**:3415–537. <https://doi.org/10.1093/eurheartj/ehae177>
249. Nowatzke J, Guedeney P, Palaskas N, Lehmann L, Ederhy S, Zhu H, et al. Coronary artery disease and revascularization associated with immune checkpoint blocker myocarditis: report from an international registry. *Eur J Cancer* 2022;**177**:197–205. <https://doi.org/10.1016/j.ejca.2022.07.018>
250. Drobni ZD, Alvi RM, Taron J, Zafar A, Murphy SP, Rambarat PK, et al. Association between immune checkpoint inhibitors with cardiovascular events and atherosclerotic plaque. *Circulation* 2020;**142**:2299–311. <https://doi.org/10.1161/CIRCULATIONAHA.120.049981>
251. Zöller B, Ji J, Sundquist J, Sundquist K. Risk of coronary heart disease in patients with cancer: a nationwide follow-up study from Sweden. *Eur J Cancer* 2012;**48**:121–8. <https://doi.org/10.1016/j.ejca.2011.09.015>
252. Jain CC, Miranda WR, El Sabbagh A, Nishimura RA. A simplified method for the diagnosis of constrictive pericarditis in the cardiac catheterization laboratory. *JAMA Cardiol* 2022;**7**:100–4. <https://doi.org/10.1001/jamacardio.2021.3478>
253. Casella M, Gasperetti A, Compagnucci P, Narducci ML, Pelargonio G, Catto V, et al. Different phases of disease in lymphocytic myocarditis: clinical and electrophysiological characteristics. *JACC Clin Electrophysiol* 2023;**9**:314–26. <https://doi.org/10.1016/j.jacep.2022.10.004>
254. Hoogendoorn JC, Sramko M, Venlet J, Siontis KC, Kumar S, Singh R, et al. Electroanatomic voltage mapping to distinguish right-sided cardiac sarcoidosis from arrhythmogenic right ventricular cardiomyopathy. *JACC Clin Electrophysiol* 2020;**6**:696–707. <https://doi.org/10.1016/j.jacep.2020.02.008>
255. Peretto G, Sala S, Basso C, Della Bella P. Programmed ventricular stimulation in patients with active vs previous arrhythmic myocarditis. *J Cardiovasc Electrophysiol* 2020;**31**:692–701. <https://doi.org/10.1111/jce.14374>
256. Haanschoten DM, Adiyaman A, 't Hart NA, Jager PL, Elvan A. Value of 3D mapping-guided endomyocardial biopsy in cardiac sarcoidosis: case series and narrative review on the value of electro-anatomic mapping-guided endomyocardial biopsies. *Eur J Clin Invest* 2021;**51**:e13497. <https://doi.org/10.1111/eci.13497>
257. Muser D, Santangeli P, Liang JJ, Castro SA, Magnani S, Hayashi T, et al. Characterization of the electroanatomic substrate in cardiac sarcoidosis: correlation with imaging findings of scar and inflammation. *JACC Clin Electrophysiol* 2018;**4**:291–303. <https://doi.org/10.1016/j.jacep.2017.09.175>
258. Liang JJ, Hebl VB, DeSimone CV, Madhavan M, Nanda S, Kapa S, et al. Electrogram guidance: a method to increase the precision and diagnostic yield of endomyocardial biopsy for suspected cardiac sarcoidosis and myocarditis. *JACC Heart Fail* 2014;**2**:466–73. <https://doi.org/10.1016/j.jchf.2014.03.015>
259. McDonagh TA, Metra M, Adamo M, Gardner RS, Baumbach A, Böhm M, et al. 2023 Focused update of the 2021 ESC guidelines for the diagnosis and treatment of acute and chronic heart failure. *Eur Heart J* 2023;**44**:3627–39. <https://doi.org/10.1093/eurheartj/ehad195>
260. Van Gelder IC, Rienstra M, Bunting KV, Casado-Arroyo R, Caso V, Crijns HJGM, et al. 2024 ESC Guidelines for the management of atrial fibrillation developed in collaboration with the European Association for Cardio-Thoracic Surgery (EACTS). *Eur Heart J* 2024;**45**:3314–414. <https://doi.org/10.1093/eurheartj/ehae176>
261. Brugada J, Katritsis DG, Arbelo E, Arribas F, Bax JJ, Blomström-Lundqvist C, et al. 2019 ESC guidelines for the management of patients with supraventricular tachycardia. The Task Force for the management of patients with supraventricular tachycardia of the European Society of Cardiology (ESC). *Eur Heart J* 2020;**41**:655–720. <https://doi.org/10.1093/eurheartj/ehz467>
262. Berg J, Lovrinovic M, Baltensperger N, Kissel CK, Kottwitz J, Manka R, et al. Non-steroidal anti-inflammatory drug use in acute myocarditis: 12-month clinical follow-up. *Open Heart* 2019;**6**:e000990. <https://doi.org/10.1136/openhrt-2018-000990>
263. Collini V, De Martino M, Andreis A, De Biasio M, Gaspard F, Paneva E, et al. Efficacy and safety of colchicine for the treatment of myopericarditis. *Heart* 2024;**110**:735–9. <https://doi.org/10.1136/heartjnl-2023-323484>
264. Kindermann M, Kindermann M, Kandolf R, Klingel K, Bültmann B, Müller T, et al. Predictors of outcome in patients with suspected myocarditis. *Circulation* 2008;**118**:639–48. <https://doi.org/10.1161/CIRCULATIONAHA.108.769489>
265. Chioncel O, Parissis J, Mebazaa A, Thiele H, Desch S, Bauersachs J, et al. Epidemiology, pathophysiology and contemporary management of cardiogenic shock—a position statement from the Heart Failure Association of the European Society of Cardiology. *Eur J Heart Fail* 2020;**22**:1315–41. <https://doi.org/10.1002/ehf.1922>
266. Heymans S, Van Linthout S, Kraus SM, Cooper LT, Ntusi NAB. Clinical characteristics and mechanisms of acute myocarditis. *Circ Res* 2024;**135**:397–411. <https://doi.org/10.1161/CIRCRESAHA.124.324674>
267. Pappritz K, Lin J, El-Shafeey M, Fechner H, Kühl U, Alogna A, et al. Colchicine prevents disease progression in viral myocarditis via modulating the NLRP3 inflammasome in the cardioplemic axis. *ESC Heart Fail* 2022;**9**:925–41. <https://doi.org/10.1002/ehf2.13845>
268. Kerneis M, Cohen F, Combes A, Amoura Z, Pare C, Brugier D, et al. Rationale and design of the ARAMIS trial: anakinra versus placebo, a double blind randomized controlled trial for the treatment of acute myocarditis. *Arch Cardiovasc Dis* 2023;**116**:460–6. <https://doi.org/10.1016/j.jacvd.2023.07.004>
269. Li Y, Yu Y, Chen S, Liao Y, Du J. Corticosteroids and intravenous immunoglobulin in pediatric myocarditis: a meta-analysis. *Front Pediatr* 2019;**7**:342. <https://doi.org/10.3389/fped.2019.00342>
270. Chen HS, Wang W, Wu SN, Liu JP. Corticosteroids for viral myocarditis. *Cochrane Database Syst Rev* 2013;**2013**:CD004471. <https://doi.org/10.1002/14651858.CD004471.pub3>
271. Brambatti M, Matassini MV, Adler ED, Klingel K, Camici PG, Ammirati E. Eosinophilic myocarditis: characteristics, treatment, and outcomes. *J Am Coll Cardiol* 2017;**70**:2363–75. <https://doi.org/10.1016/j.jacc.2017.09.023>
272. Mason JW, O'Connell JB, Herskowitz A, Rose NR, McManus BM, Billingham ME, et al. A clinical trial of immunosuppressive therapy for myocarditis. *N Engl J Med* 1995;**333**:269–75. <https://doi.org/10.1056/NEJM199508033330501>
273. Schultheiss H-P, Piper C, Sowade O, Waagstein F, Kapp J-F, Wegscheider K, et al. Betaferon in chronic viral cardiomyopathy (BICC) trial: effects of interferon-β treatment in patients with chronic viral cardiomyopathy. *Clin Res Cardiol* 2016;**105**:763–73. <https://doi.org/10.1007/s00392-016-0986-9>
274. Imazio M, Andreis A, Agosti A, Piroli F, Avondo S, Casula M, et al. Usefulness of beta-blockers to control symptoms in patients with pericarditis. *Am J Cardiol* 2021;**146**:115–9. <https://doi.org/10.1016/j.amjcard.2021.01.032>
275. Avondo S, Andreis A, Casula M, Biondi-Zoccai G, Imazio M. Pharmacologic treatment of acute and recurrent pericarditis: a systematic review and meta-analysis of controlled clinical trials. *Painmaniva Med* 2021;**63**:314–23. <https://doi.org/10.23736/S0031-0808.21.04263-4>
276. Lutschinger LL, Rigopoulos AG, Schlattmann P, Matiakis M, Sedding D, Schulze PC, et al. Meta-analysis for the value of colchicine for the therapy of pericarditis and of postpericardiotomy syndrome. *BMC Cardiovasc Disord* 2019;**19**:207. <https://doi.org/10.1186/s12872-019-1190-4>
277. Li Y-L, Qiao S-B, Wang J-Y, Chen Y-M, Luo J, Zhang H-F. Colchicine in addition to conventional therapy for pericarditis recurrence: an update meta-analysis. *Herz* 2016;**41**:630–8. <https://doi.org/10.1007/s00059-016-4410-z>
278. Papageorgiou N, Briasoulis A, Lazaros G, Imazio M, Tousoulis D. Colchicine for prevention and treatment of cardiac diseases: a meta-analysis. *Cardiovasc Ther* 2017;**35**:10–18. <https://doi.org/10.1111/1755-5922.12226>
279. Scally B, Emberson JR, Spata E, Reith C, Davies K, Halls H, et al. Effects of gastroprotectant drugs for the prevention and treatment of peptic ulcer disease and its complications: a meta-analysis of randomised trials. *Lancet Gastroenterol Hepatol* 2018;**3**:231–41. [https://doi.org/10.1016/S2468-1253\(18\)30037-2](https://doi.org/10.1016/S2468-1253(18)30037-2)
280. Humphrey MB, Russell L, Danila MI, Fink HA, Guyatt G, Cannon M, et al. 2022 American College of Rheumatology guideline for the prevention and treatment of glucocorticoid-induced osteoporosis. *Arthritis Rheumatol* 2023;**75**:2088–102. <https://doi.org/10.1002/art.42646>
281. Sambola A, Roca Luque I, Mercé J, Alguersuari J, Francisco-Pascual J, García-Dorado D, et al. Colchicine administered in the first episode of acute idiopathic pericarditis: a randomized multicenter open-label study. *Rev Esp Cardiol (Engl Ed)* 2019;**72**:709–16. <https://doi.org/10.1016/j.rec.2018.11.016>
282. Imazio M, Andreis A, Piroli F, Lazaros G, Gattorno M, Lewinter M, et al. Anti-interleukin 1 agents for the treatment of recurrent pericarditis: a systematic

- review and meta-analysis. *Heart* 2021;**107**:1240–5. <https://doi.org/10.1136/heartjnl-2020-318869>
283. Klein AL, Imazio M, Cremer P, Brucato A, Abbate A, Fang F, et al. Phase 3 trial of interleukin-1 trap riloncept in recurrent pericarditis. *N Engl J Med* 2021;**384**:31–41. <https://doi.org/10.1056/NEJMoa2027892>
 284. Brucato A, Imazio M, Gattorno M, Lazaros G, Maestroni S, Carraro M, et al. Effect of anakinra on recurrent pericarditis among patients with colchicine resistance and corticosteroid dependence: the AIRTRIP randomized clinical trial. *JAMA* 2016;**316**:1906–12. <https://doi.org/10.1001/jama.2016.15826>
 285. Brucato A, Wheeler A, Luis SA, Abbate A, Cremer PC, Zou L, et al. Transition to riloncept monotherapy from oral therapies in patients with recurrent pericarditis. *Heart* 2023;**109**:297–304. <https://doi.org/10.1136/heartjnl-2022-321328>
 286. Collini V, Andreis A, De Biasio M, De Martino M, Isola M, Croatto N, et al. Efficacy of colchicine in addition to anakinra in patients with recurrent pericarditis. *Open Heart* 2024;**11**:e002599. <https://doi.org/10.1136/openhrt-2023-002599>
 287. Vianello F, Cinetto F, Cavarro M, Battisti A, Castelli M, Imbergamo S, et al. Azathioprine in isolated recurrent pericarditis: a single centre experience. *Int J Cardiol* 2011;**147**:477–8. <https://doi.org/10.1016/j.ijcard.2011.01.027>
 288. Imazio M, Lazaros G, Picardi E, Vasileiou P, Carraro M, Tousoulis D, et al. Intravenous human immunoglobulins for refractory recurrent pericarditis: a systematic review of all published cases. *J Cardiovasc Med (Hagerstown)* 2016;**17**:263–9. <https://doi.org/10.2459/JCM.0000000000000260>
 289. Marcolongo R, Russo R, Laveder F, Noventa F, Agostini C. Immunosuppressive therapy prevents recurrent pericarditis. *J Am Coll Cardiol* 1995;**26**:1276–9. [https://doi.org/10.1016/0735-1097\(95\)00302-9](https://doi.org/10.1016/0735-1097(95)00302-9)
 290. Lazaros G, Antonopoulos AS, Antonatou K, Skendros P, Ritis K, Hadziyannis E, et al. Hydroxychloroquine for colchicine-resistant glucocorticoid-dependent idiopathic recurrent pericarditis: a pilot observational prospective study. *Int J Cardiol* 2020;**311**:77–82. <https://doi.org/10.1016/j.ijcard.2020.03.069>
 291. Lotrionte M, Biondi-Zoccai G, Imazio M, Castagno D, Moretti C, Abbate A, et al. International collaborative systematic review of controlled clinical trials on pharmacologic treatments for acute pericarditis and its recurrences. *Am Heart J* 2010;**160**:662–70. <https://doi.org/10.1016/j.ahj.2010.06.015>
 292. Horneffer PJ, Miller RH, Pearson TA, Rykiel MF, Reitz BA, Gardner TJ. The effective treatment of postpericardiotomy syndrome after cardiac operations. A randomized placebo-controlled trial. *J Thorac Cardiovasc Surg* 1990;**100**:292–6. [https://doi.org/10.1016/S0022-5223\(19\)35571-0](https://doi.org/10.1016/S0022-5223(19)35571-0)
 293. Atluri P, Ullery BW, MacArthur JW, Goldstone AB, Fairman AS, Hiesinger W, et al. Rapid onset of fulminant myocarditis portends a favourable prognosis and the ability to bridge mechanical circulatory support to recovery. *Eur J Cardiothorac Surg* 2013;**43**:379–82. <https://doi.org/10.1093/ejcts/ezs242>
 294. Montero S, Aissaoui N, Tadié J-M, Bizouarn P, Scherrer V, Persichini R, et al. Fulminant giant-cell myocarditis on mechanical circulatory support: management and outcomes of a French multicentre cohort. *Int J Cardiol* 2018;**253**:105–12. <https://doi.org/10.1016/j.ijcard.2017.10.053>
 295. Bernhardt AM, Copeland H, Deswal A, Gluck J, Givertz MM; Task Force 1; et al. The International Society for Heart and Lung Transplantation/Heart Failure Society of America Guideline on Acute Mechanical Circulatory Support. *J Heart Lung Transplant* 2023;**42**:e1–e64. <https://doi.org/10.1016/j.healun.2022.10.028>
 296. Lorusso R, Shekar K, MacLaren G, Schmidt M, Pellegrino V, Meyns B, et al. ELSO interim guidelines for venoarterial extracorporeal membrane oxygenation in adult cardiac patients. *ASAIO J* 2021;**67**:827–44. <https://doi.org/10.1097/MAT.0000000000001510>
 297. Lorusso R, Centofanti P, Gelsomino S, Barili F, Di Mauro M, Orlando P, et al. Venoarterial extracorporeal membrane oxygenation for acute fulminant myocarditis in adult patients: a 5-year multi-institutional experience. *Ann Thorac Surg* 2016;**101**:919–26. <https://doi.org/10.1016/j.athoracsur.2015.08.014>
 298. Mirabel M, Luyt C-E, Leprince P, Trouillet J-L, Léger P, Pavie A, et al. Outcomes, long-term quality of life, and psychologic assessment of fulminant myocarditis patients rescued by mechanical circulatory support. *Crit Care Med* 2011;**39**:1029–35. <https://doi.org/10.1097/CCM.0b013e31820ead45>
 299. Diddle JW, Almodovar MC, Rajagopal SK, Rycus PT, Thiagarajan RR. Extracorporeal membrane oxygenation for the support of adults with acute myocarditis. *Crit Care Med* 2015;**43**:1016–25. <https://doi.org/10.1097/CCM.0000000000000920>
 300. Nunez JJ, Grandin EV, Reyes-Castro T, Sabe M, Quintero P, Motiwala S, et al. Outcomes with peripheral venoarterial extracorporeal membrane oxygenation for suspected acute myocarditis: 10-year experience from the extracorporeal life support organization registry. *Circ Heart Fail* 2023;**16**:e010152. <https://doi.org/10.1161/CIRCHEARTFAILURE.122.010152>
 301. Strobbe A, Adriaenssens T, Bennett J, Dubois C, Desmet W, McCutcheon K, et al. Etiology and long-term outcome of patients undergoing pericardiocentesis. *J Am Heart Assoc* 2017;**6**:e007598. <https://doi.org/10.1161/JAHA.117.007598>
 302. Maisch B, Ristić AD, Pankuweit S, Neubauer A, Moll R. Neoplastic pericardial effusion. Efficacy and safety of intrapericardial treatment with cisplatin. *Eur Heart J* 2002;**23**:1625–31. <https://doi.org/10.1053/ehj.2002.3328>
 303. Martinoni A, Cipolla CM, Cardinale D, Civelli M, Lamantia G, Colleoni M, et al. Long-term results of intrapericardial chemotherapeutic treatment of malignant pericardial effusions with thiotepa. *Chest* 2004;**126**:1412–6. <https://doi.org/10.1378/chest.126.5.1412>
 304. Colleoni M, Martinelli G, Beretta F, Marone C, Gallino A, Fontana M, et al. Intracavitary chemotherapy with thiotepa in malignant pericardial effusions: an active and well-tolerated regimen. *J Clin Oncol* 1998;**16**:2371–6. <https://doi.org/10.1200/JCO.1998.16.7.2371>
 305. Kunitoh H, Tamura T, Shibata T, Imai M, Nishiwaki Y, Nishio M, et al. A randomised trial of intrapericardial bleomycin for malignant pericardial effusion with lung cancer (JCOG9811). *Br J Cancer* 2009;**100**:464–9. <https://doi.org/10.1038/sj.bjc.6604866>
 306. Shepherd FA, Morgan C, Evans WK, Ginsberg JF, Watt D, Murphy K. Medical management of malignant pericardial effusion by tetracycline sclerosis. *Am J Cardiol* 1987;**60**:1161–6. [https://doi.org/10.1016/0002-9149\(87\)90411-5](https://doi.org/10.1016/0002-9149(87)90411-5)
 307. Beckmann E, Ismail I, Cebotari S, Busse A, Martens A, Shrestha M, et al. Right-sided heart failure and extracorporeal life support in patients undergoing pericardiectomy for constrictive pericarditis: a risk factor analysis for adverse outcome. *Thorac Cardiovasc Surg* 2017;**65**:662–70. <https://doi.org/10.1055/s-0036-1593817>
 308. Busch C, Penov K, Amorim PA, Garbade J, Davierwala P, Schuler GC, et al. Risk factors for mortality after pericardiectomy for chronic constrictive pericarditis in a large single-centre cohort. *Eur J Cardiothorac Surg* 2015;**48**:e110–6. <https://doi.org/10.1093/ejcts/ezv322>
 309. Vondran M, Rylski B, Berezowski M, Polycarpou A, Born F, Guenther S, et al. Preemptive extracorporeal life support for surgical treatment of severe constrictive pericarditis. *Ann Thorac Surg* 2019;**108**:1376–81. <https://doi.org/10.1016/j.athoracsur.2019.03.105>
 310. Saxena P, Joyce LD, Daly RC, Kushwaha SS, Schirger JA, Rosedahl J, et al. Cardiac transplantation for radiation-induced cardiomyopathy: the Mayo Clinic experience. *Ann Thorac Surg* 2014;**98**:2115–21. <https://doi.org/10.1016/j.athoracsur.2014.06.056>
 311. Al-Kazaz M, Klein AL, Oh JK, Crestanello JA, Cremer PC, Tong MZ, et al. Pericardial diseases and best practices for pericardiectomy: JACC state-of-the-art review. *J Am Coll Cardiol* 2024;**84**:561–80. <https://doi.org/10.1016/j.jacc.2024.05.048>
 312. Vistarini N, Chen C, Mazine A, Bouchard D, Hebert Y, Carrier M, et al. Pericardiectomy for constrictive pericarditis: 20 years of experience at the Montreal Heart Institute. *Ann Thorac Surg* 2015;**100**:107–13. <https://doi.org/10.1016/j.athoracsur.2015.02.054>
 313. Lee S, Lee J, Joo S, Park YK, Kim KM, Jung JC, et al. Impact of pericardial calcification on early postoperative outcomes after pericardiectomy: a retrospective observational study. *J Cardiothorac Surg* 2024;**19**:449. <https://doi.org/10.1186/s13019-024-02842-4>
 314. Yamamoto N, Ohara K, Nie M, Torii S, Inoue N, Miyaji K. For what type of constrictive pericarditis is the waffle procedure effective? *Asian Cardiovasc Thorac Ann* 2011;**19**:115–8. <https://doi.org/10.1177/0218492311399496>
 315. Matsuura K, Mogi K, Takahara Y. Off-pump waffle procedure using an ultrasonic scalpel for constrictive pericarditis. *Eur J Cardiothorac Surg* 2015;**47**:e220–2. <https://doi.org/10.1093/ejcts/ezu554>
 316. Calderon-Rojas RD, Greason KL, King KS, Luis SA, Oh JK, Stulak JM, et al. Outcomes of tricuspid valve operation at the time of pericardiectomy for constrictive pericarditis. *Ann Thorac Surg* 2021;**111**:1252–7. <https://doi.org/10.1016/j.athoracsur.2020.06.106>
 317. Li T-T, Cheng J. Clinical analysis of temporary pacemaker implantation in 13 children. *Transl Pediatr* 2022;**11**:174–82. <https://doi.org/10.21037/tp-21-586>
 318. Suarez K, Banchs JE. A review of temporary permanent pacemakers and a comparison with conventional temporary pacemakers. *J Innov Card Rhythm Manag* 2019;**10**:3652–61. <https://doi.org/10.19102/icrm.2019.100506>
 319. Braun MU, Rauwolf T, Bock M, Kappert U, Boscheri A, Schnabel A, et al. Percutaneous lead implantation connected to an external device in stimulation-dependent patients with systemic infection—a prospective and controlled study. *Pacing Clin Electrophysiol* 2006;**29**:875–9. <https://doi.org/10.1111/j.1540-8159.2006.00454.x>
 320. Zei PC, Eckart RE, Epstein LM. Modified temporary cardiac pacing using transvenous active fixation leads and external re-sterilized pulse generators. *J Am Coll Cardiol* 2006;**47**:1487–9. <https://doi.org/10.1016/j.jacc.2006.01.006>
 321. Chung MK, Patton KK, Lau C-P, Forno ARJD, Al-Khatib SM, Arora V, et al. 2023 HRS/APHRS/LAHR guideline on cardiac physiologic pacing for the avoidance and mitigation of heart failure. *Heart Rhythm* 2023;**20**:e17–91. <https://doi.org/10.1016/j.hrthm.2023.03.1538>
 322. Casella M, Bergonti M, Narducci ML, Persampieri S, Gasperetti A, Conte E, et al. Prior myocarditis and ventricular arrhythmias: the importance of scar pattern. *Heart Rhythm* 2021;**18**:589–96. <https://doi.org/10.1016/j.hrthm.2020.12.016>
 323. Rav-Acha M, Shah K, Hasin T, Gumuser E, Tovia-Brodie O, Shauer A, et al. Incidence and predictors for recurrence of ventricular arrhythmia presenting during acute myocarditis: a multicenter study. *JACC Clin Electrophysiol* 2024;**10**:1161–74. <https://doi.org/10.1016/j.jacep.2024.02.027>
 324. Sasko B, Patschan D, Nordbeck P, Seidlmayer L, Andresen H, Jänsch M, et al. Secondary prevention of potentially life-threatening arrhythmia using implantable cardioverter defibrillators in patients with biopsy-proven viral myocarditis and preserved ejection fraction. *Cardiology* 2021;**146**:213–21. <https://doi.org/10.1159/000511120>
 325. Peretto G, Sala S, Carturan E, Rizzo S, Villatore A, De Luca G, et al. Clinical profiling and outcomes of viral myocarditis manifesting with ventricular arrhythmias. *Eur Heart J Open* 2023;**3**:oead132. <https://doi.org/10.1093/ehjopen/oead132>

326. Ekström K, Lehtonen J, Kandinou R, Räisänen-Sokolowski A, Salmenkivi K, Kupari M. Incidence, risk factors, and outcome of life-threatening ventricular arrhythmias in giant cell myocarditis. *Circ Arrhythm Electrophysiol* 2016;**9**:e004559. <https://doi.org/10.1161/CIRCEP.116.004559>
327. Tscholl V, Wielander D, Kelch F, Stroux A, Attanasio P, Tschöpe C, et al. Benefit of a wearable cardioverter defibrillator for detection and therapy of arrhythmias in patients with myocarditis. *ESC Heart Fail* 2021;**8**:2428–37. <https://doi.org/10.1002/ehf2.13353>
328. Blaschke F, Lacour P, Dang PL, Parwani AS, Hohendanner F, Walter T, et al. Wearable cardioverter-defibrillator: friend or foe in suspected myocarditis? *ESC Heart Fail* 2021;**8**:2591–6. <https://doi.org/10.1002/ehf2.13340>
329. Waßnig NK, Günther M, Quick S, Pfluecke C, Rottstädt F, Szymkiewicz SJ, et al. Experience with the wearable cardioverter-defibrillator in patients at high risk for sudden cardiac death. *Circulation* 2016;**134**:635–43. <https://doi.org/10.1161/CIRCULATIONAHA.115.019124>
330. El-Battrawy I, Koepsel K, Tenbrink D, Kovacs B, Dreher TC, Blockhaus C, et al. Use of the wearable cardioverter-defibrillator among patients with myocarditis and reduced ejection fraction or ventricular tachyarrhythmia: data from a multicenter registry. *J Am Heart Assoc* 2023;**12**:e030615. <https://doi.org/10.1161/JAHA.123.030615>
331. Peretto G, Gulletta S, Slavich M, Campochiaro C, Vignale D, De Luca G, et al. Exercise stress test late after arrhythmic versus nonarrhythmic presentation of myocarditis. *J Pers Med* 2022;**12**:1702. <https://doi.org/10.3390/jpm12101702>
332. Yang F, Wang J, Li W, Xu Y, Wan K, Zeng R, et al. The prognostic value of late gadolinium enhancement in myocarditis and clinically suspected myocarditis: systematic review and meta-analysis. *Eur Radiol* 2020;**30**:2616–26. <https://doi.org/10.1007/s00330-019-06643-5>
333. Georgiopoulos G, Figliozzi S, Sanguineti F, Aquaro GD, di Bella G, Stamatelopoulos K, et al. Prognostic impact of late gadolinium enhancement by cardiovascular magnetic resonance in myocarditis. *Circ Cardiovasc Imaging* 2021;**14**:e011492. <https://doi.org/10.1161/CIRCIMAGING.120.011492>
334. Schumm J, Greulich S, Wagner A, Grün S, Ong P, Bentz K, et al. Cardiovascular magnetic resonance risk stratification in patients with clinically suspected myocarditis. *J Cardiovasc Magn Reson* 2014;**16**:14. <https://doi.org/10.1186/1532-429X-16-14>
335. Salamanca J, Díez-Villanueva P, Martínez P, Cecconi A, González de Marcos B, Reyes G, et al. COVID-19 ‘fulminant myocarditis’ successfully treated with temporary mechanical circulatory support. *JACC Cardiovasc Imaging* 2020;**13**:2457–9. <https://doi.org/10.1016/j.jcmg.2020.05.003>
336. Pavlicek V, Kindermann I, Wintrich J, Mahfoud F, Klingel K, Böhm M, et al. Ventricular arrhythmias and myocardial inflammation: long-term follow-up of patients with suspected myocarditis. *Int J Cardiol* 2019;**274**:132–7. <https://doi.org/10.1016/j.ijcard.2018.07.142>
337. Imazio M, Brucato A, Spodick DH, Adler Y. Prognosis of myopericarditis as determined from previously published reports. *J Cardiovasc Med (Hagerstown)* 2014;**15**:835–9. <https://doi.org/10.2459/JCM.0000000000000082>
338. Castrichini M, Porcari A, Baggio C, Gagno G, Maione D, Barbati G, et al. Sex differences in natural history of cardiovascular magnetic resonance- and biopsy-proven lymphocytic myocarditis. *ESC Heart Fail* 2022;**9**:4010–9. <https://doi.org/10.1002/ehf2.14102>
339. Grün S, Schumm J, Greulich S, Wagner A, Schneider S, Bruder O, et al. Long-term follow-up of biopsy-proven viral myocarditis: predictors of mortality and incomplete recovery. *J Am Coll Cardiol* 2012;**59**:1604–15. <https://doi.org/10.1016/j.jacc.2012.01.007>
340. Ammirati E, Varrenti M, Sormani P, Bernasconi D, Moro C, Grosu A, et al. Long-term prognostic performance of cardiac magnetic resonance imaging markers versus complicated clinical presentation after an acute myocarditis. *Int J Cardiol* 2024;**417**:132567. <https://doi.org/10.1016/j.ijcard.2024.132567>
341. Greulich S, Seitz A, Müller KAL, Grün S, Ong P, Ebadi N, et al. Predictors of mortality in patients with biopsy-proven viral myocarditis: 10-year outcome data. *J Am Heart Assoc* 2020;**9**:e015351. <https://doi.org/10.1161/JAHA.119.015351>
342. Mahrholdt H, Wagner A, Deluigi CC, Kispert E, Hager S, Meinhardt G, et al. Presentation, patterns of myocardial damage, and clinical course of viral myocarditis. *Circulation* 2006;**114**:1581–90. <https://doi.org/10.1161/CIRCULATIONAHA.105.606509>
343. Narducci ML, Pelargonio G, La Rosa G, Inzani F, d’Amati G, Novelli V, et al. Role of extensive diagnostic workup in young athletes and nonathletes with complex ventricular arrhythmias. *Heart Rhythm* 2020;**17**:230–7. <https://doi.org/10.1016/j.hrthm.2019.08.022>
344. Maleszewski JJ, Orellana VM, Hodge DO, Kuhl U, Schultheiss H-P, Cooper LT. Long-term risk of recurrence, morbidity and mortality in giant cell myocarditis. *Am J Cardiol* 2015;**115**:1733–8. <https://doi.org/10.1016/j.amjcard.2015.03.023>
345. Kim M-J, Jung HO, Kim H, Bae Y, Lee SY, Jeon DS. 10-Year survival outcome after clinically suspected acute myocarditis in adults: a nationwide study in the pre-COVID-19 era. *PLoS One* 2023;**18**:e0281296. <https://doi.org/10.1371/journal.pone.0281296>
346. Kytö V, Sipilä J, Rautava P. Rate and patient features associated with recurrence of acute myocarditis. *Eur J Intern Med* 2014;**25**:946–50. <https://doi.org/10.1016/j.ejim.2014.11.001>
347. Imazio M, Brucato A, Maestroni S, Cumetti D, Belli R, Trincherò R, et al. Risk of restrictive pericarditis after acute pericarditis. *Circulation* 2011;**124**:1270–5. <https://doi.org/10.1161/CIRCULATIONAHA.111.018580>
348. Yesilyaprak A, Kumar AK, Agrawal A, Furqan MM, Verma BR, Syed AB, et al. Predicting long-term clinical outcomes of patients with recurrent pericarditis. *J Am Coll Cardiol* 2024;**84**:1193–204. <https://doi.org/10.1016/j.jacc.2024.05.072>
349. Caforio ALP, Adler Y, Agostini C, Allanore Y, Anastasakis A, Arad M, et al. Diagnosis and management of myocardial involvement in systemic immune-mediated diseases: a position statement of the European Society of Cardiology Working Group on Myocardial and Pericardial Disease. *Eur Heart J* 2017;**38**:2649–62. <https://doi.org/10.1093/eurheartj/ehx321>
350. Cheng C-Y, Baritussio A, Giordani AS, Iliceto S, Marcolongo R, Caforio ALP. Myocarditis in systemic immune-mediated diseases: prevalence, characteristics and prognosis. A systematic review. *Autoimmun Rev* 2022;**21**:103037. <https://doi.org/10.1016/j.autrev.2022.103037>
351. Mavrogeni S, Bratis K, Sfendouraki E, Papadopoulou E, Kolovou G. Myopericarditis, as the first sign of rheumatoid arthritis relapse, evaluated by cardiac magnetic resonance. *Inflamm Allergy Drug Targets* 2013;**12**:206–11. <https://doi.org/10.2174/1871528111312030008>
352. Aringer M, Costenbader K, Daikh D, Brinks R, Mosca M, Ramsey-Goldman R, et al. 2019 European League Against Rheumatism/American College of Rheumatology classification criteria for systemic lupus erythematosus. *Arthritis Rheumatol* 2019;**71**:1400–12. <https://doi.org/10.1002/art.40930>
353. Jia E, Geng H, Liu Q, Xiao Y, Zhang Y, Xie J, et al. Cardiac manifestations of Han Chinese patients with systemic lupus erythematosus: a retrospective study. *Ir J Med Sci* 2019;**188**:801–6. <https://doi.org/10.1007/s11845-018-1934-7>
354. Tanwani J, Seliouk K, Gladman DD, Su J, Urowitz MB. Lupus myocarditis: a single center experience and a comparative analysis of observational cohort studies. *Lupus* 2018;**27**:1296–302. <https://doi.org/10.1177/0961203318770018>
355. Thomas G, Cohen Aubart F, Chiche L, Haroche J, Hié M, Hervier B, et al. Lupus myocarditis: initial presentation and longterm outcomes in a multicentric series of 29 patients. *J Rheumatol* 2017;**44**:24–32. <https://doi.org/10.3899/jrheum.160493>
356. Mathian A, Mouries-Martin S, Dorgham K, Devilliers H, Yssel H, Garrido Castillo L, et al. Ultrasensitive serum interferon- α quantification during SLE remission identifies patients at risk for relapse. *Ann Rheum Dis* 2019;**78**:1669–76. <https://doi.org/10.1136/annrheumdis-2019-215571>
357. Mathian A, Mouries-Martin S, Dorgham K, Devilliers H, Barnabei L, Ben Salah E, et al. Monitoring disease activity in systemic lupus erythematosus with single-molecule array digital enzyme-linked immunosorbent assay quantification of serum interferon- α . *Arthritis Rheumatol* 2019;**71**:756–65. <https://doi.org/10.1002/art.40792>
358. du Toit R, Herbst PG, Ackerman C, Pecoraro AJ, Claassen D, Cyster HP, et al. Outcome of clinical and subclinical myocardial injury in systemic lupus erythematosus—a prospective cohort study. *Lupus* 2021;**30**:256–68. <https://doi.org/10.1177/0961203320976960>
359. Hinojar R, Foote L, Sangle S, Marber M, Mayr M, Carr-White G, et al. Native T1 and T2 mapping by CMR in lupus myocarditis: disease recognition and response to treatment. *Int J Cardiol* 2016;**222**:717–26. <https://doi.org/10.1016/j.ijcard.2016.07.182>
360. Sacré K, Brihaye B, Hyafil F, Serfaty J-M, Escoubet B, Zennaro M-C, et al. Asymptomatic myocardial ischemic disease in antiphospholipid syndrome: a controlled cardiac magnetic resonance imaging study. *Arthritis Rheum* 2010;**62**:2093–100. <https://doi.org/10.1002/art.27488>
361. Pineton de Chambrun M, Larcher R, Pène F, Argaud L, Mayaux J, Jamme M, et al. In-hospital mortality-associated factors in patients with thrombotic antiphospholipid syndrome requiring ICU admission. *Chest* 2020;**157**:1158–66. <https://doi.org/10.1016/j.chest.2019.11.010>
362. Yong WC, Sangankeo A, Upala S. Association between primary Sjogren’s syndrome, arterial stiffness, and subclinical atherosclerosis: a systematic review and meta-analysis. *Clin Rheumatol* 2019;**38**:447–55. <https://doi.org/10.1007/s10067-018-4265-1>
363. Lazzarini PE, Murthy Ginjupalli VK, Srivastava U, Bertolozzi I, Bacarelli MR, Verriglia D, et al. Anti-Ro/SSA antibodies blocking calcium channels as a potentially reversible cause of atrioventricular block in adults. *JACC Clin Electrophysiol* 2023;**9**:1631–48. <https://doi.org/10.1016/j.jacep.2023.03.007>
364. Bruni C, Buch MH, Furst DE, De Luca G, Djokovic A, Dumitru RB, et al. Primary systemic sclerosis heart involvement: a systematic literature review and preliminary data-driven, consensus-based WSF/HFA definition. *J Scleroderma Relat Disord* 2022;**7**:24–32. <https://doi.org/10.1177/23971983211053246>
365. Krumm P, Mueller KAL, Klingel K, Kramer U, Horger MS, Zitzelsberger T, et al. Cardiovascular magnetic resonance patterns of biopsy proven cardiac involvement in systemic sclerosis. *J Cardiovasc Magn Reson* 2016;**18**:70. <https://doi.org/10.1186/s12968-016-0289-3>
366. De Luca G, Campochiaro C, De Santis M, Sartorelli S, Peretto G, Sala S, et al. Systemic sclerosis myocarditis has unique clinical, histological and prognostic features: a comparative histological analysis. *Rheumatology (Oxford)* 2020;**59**:2523–33. <https://doi.org/10.1093/rheumatology/kez658>
367. Ferri C, Valentini G, Cozzi F, Sebastiani M, Michelassi C, La Montagna G, et al. Systemic sclerosis: demographic, clinical, and serologic features and survival in 1,012 Italian

- patients. *Medicine (Baltimore)* 2002;**81**:139–53. <https://doi.org/10.1097/00005792-200203000-00004>
368. Bruni C, Buch MH, Djokovic A, De Luca G, Dumitru RB, Giollo A, et al. Consensus on the assessment of systemic sclerosis-associated primary heart involvement: World Scleroderma Foundation/Heart Failure Association guidance on screening, diagnosis, and follow-up assessment. *J Scleroderma Relat Disord* 2023;**8**:169–82. <https://doi.org/10.1177/23971983231163413>
369. Fairley JL, Wicks I, Peters S, Day J. Defining cardiac involvement in idiopathic inflammatory myopathies: a systematic review. *Rheumatology (Oxford)* 2021;**61**:103–20. <https://doi.org/10.1093/rheumatology/keab573>
370. Dankó K, Ponyi A, Constantini T, Borgulya G, Szegedi G. Long-term survival of patients with idiopathic inflammatory myopathies according to clinical features: a longitudinal study of 162 cases. *Medicine (Baltimore)* 2004;**83**:35–42. <https://doi.org/10.1097/01.md.0000109755.65914.5e>
371. Allanore Y, Vignaux O, Arnaud L, Puéchal X, Pavy S, Duboc D, et al. Effects of corticosteroids and immunosuppressors on idiopathic inflammatory myopathy related myocarditis evaluated by magnetic resonance imaging. *Ann Rheum Dis* 2006;**65**:249–52. <https://doi.org/10.1136/ard.2005.038679>
372. Zhang L, Wang G, Ma L, Zu N. Cardiac involvement in adult polymyositis or dermatomyositis: a systematic review. *Clin Cardiol* 2012;**35**:686–91. <https://doi.org/10.1002/clc.22026>
373. Groh M, Masciocco G, Kirchner E, Kristen A, Pellegrini C, Varnous S, et al. Heart transplantation in patients with eosinophilic granulomatosis with polyangiitis (Churg–Strauss syndrome). *J Heart Lung Transplant* 2014;**33**:842–50. <https://doi.org/10.1016/j.jhealun.2014.02.023>
374. Bojkova D, Wagner JUG, Shumliakivska M, Aslan GS, Saleem U, Hansen A, et al. SARS-CoV-2 infects and induces cytotoxic effects in human cardiomyocytes. *Cardiovasc Res* 2020;**116**:2207–15. <https://doi.org/10.1093/cvr/cvaa267>
375. Peretto G, Villatore A, Rizzo S, Esposito A, De Luca G, Palmisano A, et al. The spectrum of COVID-19-associated myocarditis: a patient-tailored multidisciplinary approach. *J Clin Med* 2021;**10**:1974. <https://doi.org/10.3390/jcm10091974>
376. Weckbach LT, Curta A, Bieber S, Kraechan A, Brado J, Hellmuth JC, et al. Myocardial inflammation and dysfunction in COVID-19-associated myocardial injury. *Circ Cardiovasc Imaging* 2021;**14**:e012220. <https://doi.org/10.1161/CIRCIMAGING.120.011713>
377. Basso C, Leone O, Rizzo S, De Gaspari M, van der Wal A, Aubry M-C, et al. Pathological features of COVID-19-associated myocardial injury: a multicentre cardiovascular pathology study. *Eur Heart J* 2020;**41**:3827–35. <https://doi.org/10.1093/eurheartj/ehaa664>
378. Halushka MK, Vander Heide RS. Myocarditis is rare in COVID-19 autopsies: cardiovascular findings across 277 postmortem examinations. *Cardiovasc Pathol* 2021;**50**:107300. <https://doi.org/10.1016/j.carpath.2020.107300>
379. Lindner D, Fitzek A, Bräuninger H, Aleshcheva G, Edler C, Meissner K, et al. Association of cardiac infection with SARS-CoV-2 in confirmed COVID-19 autopsy cases. *JAMA Cardiol* 2020;**5**:1281–5. <https://doi.org/10.1001/jamacardio.2020.3551>
380. Aquaro GD, Licordari R, Todiore G, Ianni U, Dellegrottaglie S, Restivo L, et al. Incidence of acute myocarditis and pericarditis during the coronavirus disease 2019 pandemic: comparison with the pre-pandemic period. *J Cardiovasc Med (Hagerstown)* 2022;**23**:447–53. <https://doi.org/10.2459/JCM.0000000000001330>
381. Boehmer TK, Kompaniyets L, Lavery AM, Hsu J, Ko JY, Yusuf H, et al. Association between COVID-19 and myocarditis using hospital-based administrative data—United States, March 2020–January 2021. *MMWR Morb Mortal Wkly Rep* 2021;**70**:1228–32. <https://doi.org/10.15585/mmwr.mm7035e5>
382. Daniels CJ, Rajpal S, Greenshields JT, Rosenthal GL, Chung EH, Terrin M, et al. Prevalence of clinical and subclinical myocarditis in competitive athletes with recent SARS-CoV-2 infection: results from the big ten COVID-19 cardiac registry. *JAMA Cardiol* 2021;**6**:1078–87. <https://doi.org/10.1001/jamacardio.2021.2065>
383. Cavalli G, De Luca G, Campochiaro C, Della-Torre E, Ripa M, Canetti D, et al. Interleukin-1 blockade with high-dose anakinra in patients with COVID-19, acute respiratory distress syndrome, and hyperinflammation: a retrospective cohort study. *Lancet Rheumatol* 2020;**2**:e325–31. [https://doi.org/10.1016/S2665-9913\(20\)30127-2](https://doi.org/10.1016/S2665-9913(20)30127-2)
384. REMAP-CAP Investigators; Gordon AC, Mouncey PR, Al-Beidh F, Rowan KM, Nichol AD, et al. Interleukin-6 receptor antagonists in critically ill patients with Covid-19. *N Engl J Med* 2021;**384**:1491–502. <https://doi.org/10.1056/NEJMoa2100433>
385. Gupta S, Wang W, Hayek SS, Chan L, Mathews KS, Melamed ML, et al. Association between early treatment with tocilizumab and mortality among critically ill patients with COVID-19. *JAMA Intern Med* 2021;**181**:41–51. <https://doi.org/10.1001/jamainternmed.2020.6252>
386. Klingel K, Hohenadl C, Canu A, Albrecht M, Seemann M, Mall G, et al. Ongoing enterovirus-induced myocarditis is associated with persistent heart muscle infection: quantitative analysis of virus replication, tissue damage, and inflammation. *Proc Natl Acad Sci U S A* 1992;**89**:314–8. <https://doi.org/10.1073/pnas.89.1.314>
387. Schowengerdt KO, Ni J, Denfield SW, Gajarski RJ, Bowles NE, Rosenthal G, et al. Association of parvovirus B19 genome in children with myocarditis and cardiac allograft rejection: diagnosis using the polymerase chain reaction. *Circulation* 1997;**96**:3549–54. <https://doi.org/10.1161/01.cir.96.10.3549>
388. Bock C-T, Klingel K, Kandolf R. Human parvovirus B19-associated myocarditis. *N Engl J Med* 2010;**362**:1248–9. <https://doi.org/10.1056/NEJMc0911362>
389. Huang C-H, Vallejo JG, Kollias G, Mann DL. Role of the innate immune system in acute viral myocarditis. *Basic Res Cardiol* 2009;**104**:228–37. <https://doi.org/10.1007/s00395-008-0765-5>
390. Corsten MF, Papageorgiou A, Verheesen W, Carai P, Lindow M, Obad S, et al. MicroRNA profiling identifies microRNA-155 as an adverse mediator of cardiac injury and dysfunction during acute viral myocarditis. *Circ Res* 2012;**111**:415–25. <https://doi.org/10.1161/CIRCRESAHA.112.267443>
391. Goldberg L, Tirosh-Wagner T, Vardi A, Abbas H, Pillar N, Shomron N, et al. Circulating microRNAs: a potential biomarker for cardiac damage, inflammatory response, and left ventricular function recovery in pediatric viral myocarditis. *J Cardiovasc Transl Res* 2018;**11**:319–28. <https://doi.org/10.1007/s12265-018-9814-0>
392. Mueller KAL, Mueller II, Eppler D, Zuern CS, Seizer P, Kramer U, et al. Clinical and histopathological features of patients with systemic sclerosis undergoing endomyocardial biopsy. *PLoS One* 2015;**10**:e0126707. <https://doi.org/10.1371/journal.pone.0126707>
393. Wakafuji S, Okada R. Twenty year autopsy statistics of myocarditis incidence in Japan. *Jpn Circ J* 1986;**50**:1288–93. <https://doi.org/10.1253/jcj.50.1288>
394. Vaideswar P, Cooper LT. Giant cell myocarditis: clinical and pathological features in an Indian population. *Cardiovasc Pathol* 2013;**22**:70–4. <https://doi.org/10.1016/j.carpath.2012.06.003>
395. Caforio ALP, Angelini A, Blank M, Shani A, Kivity S, Goddard G, et al. Passive transfer of affinity-purified anti-heart autoantibodies (AHA) from sera of patients with myocarditis induces experimental myocarditis in mice. *Int J Cardiol* 2015;**179**:166–77. <https://doi.org/10.1016/j.ijcard.2014.10.165>
396. Kandolin R, Lehtonen J, Kupari M. Cardiac sarcoidosis and giant cell myocarditis as causes of atrioventricular block in young and middle-aged adults. *Circ Arrhythm Electrophysiol* 2011;**4**:303–9. <https://doi.org/10.1161/CIRCEP.110.959254>
397. Bozkurt B, Colvin M, Cook J, Cooper LT, Deswal A, Fonarow GC, et al. Current diagnostic and treatment strategies for specific dilated cardiomyopathies: a scientific statement from the American Heart Association. *Circulation* 2016;**134**:e579–e646. <https://doi.org/10.1161/CIR.0000000000000455>
398. Liu S, Zheng L, Shen L, Wu L, Yao Y. Clinical identification and characteristic analysis of giant cell myocarditis in 12 cases. *Front Cardiovasc Med* 2021;**8**:649094. <https://doi.org/10.3389/fcvm.2021.649094>
399. Okura Y, Dec GW, Hare JM, Kodama M, Berry GJ, Tazelaar HD, et al. A clinical and histopathologic comparison of cardiac sarcoidosis and idiopathic giant cell myocarditis. *J Am Coll Cardiol* 2003;**41**:322–9. [https://doi.org/10.1016/s0735-1097\(02\)02715-8](https://doi.org/10.1016/s0735-1097(02)02715-8)
400. Berthelot-Richer M, O'Connor K, Bernier M, Trahan S, Couture C, Dubois M, et al. When should we consider the diagnosis of giant cell myocarditis? Revisiting 'classic' echocardiographic and clinical features of this rare pathology. *Exp Clin Transplant* 2014;**12**:565–8. <https://doi.org/10.6002/ect.2013.0218>
401. Ekström K, Lehtonen J, Kandolin R, Räisänen-Sokolowski A, Salmenkivi K, Kupari M. Long-term outcome and its predictors in giant cell myocarditis. *Eur J Heart Fail* 2016;**18**:1452–8. <https://doi.org/10.1002/ejhf.606>
402. Cooper LT, Baughman KL, Feldman AM, Frustaci A, Jessup M, Kuhl U, et al. The role of endomyocardial biopsy in the management of cardiovascular disease: a scientific statement from the American Heart Association, the American College of Cardiology, and the European Society of Cardiology. Endorsed by the Heart Failure Society of America and the Heart Failure Association of the European Society of Cardiology. *J Am Coll Cardiol* 2007;**50**:1914–31. <https://doi.org/10.1016/j.jacc.2007.09.008>
403. Cooper LT, Hare JM, Tazelaar HD, Edwards WD, Starling RC, Deng MC, et al. Usefulness of immunosuppression for giant cell myocarditis. *Am J Cardiol* 2008;**102**:1535–9. <https://doi.org/10.1016/j.amjcard.2008.07.041>
404. Patel PM, Saxena A, Wood CT, O'Malley TJ, Maynes EJ, Entwistle JWC, et al. Outcomes of mechanical circulatory support for giant cell myocarditis: a systematic review. *J Clin Med* 2020;**9**:3905. <https://doi.org/10.3390/jcm9123905>
405. Bobbio E, Björkenstam M, Nwaru BI, Giallauria F, Hessman E, Bergh N, et al. Short- and long-term outcomes after heart transplantation in cardiac sarcoidosis and giant-cell myocarditis: a systematic review and meta-analysis. *Clin Res Cardiol* 2022;**111**:125–40. <https://doi.org/10.1007/s00392-021-01920-0>
406. Baughman RP, Teirstein AS, Judson MA, Rossman MD, Yeager H, Bresnitz EA, et al. Clinical characteristics of patients in a case control study of sarcoidosis. *Am J Respir Crit Care Med* 2001;**164**:1885–9. <https://doi.org/10.1164/ajrccm.164.10.2104046>
407. Lehtonen J, Uusitalo V, Pöyhönen P, Mäyränpää MI, Kupari M. Cardiac sarcoidosis: phenotypes, diagnosis, treatment, and prognosis. *Eur Heart J* 2023;**44**:1495–510. <https://doi.org/10.1093/eurheartj/ehad067>
408. Okasha O, Kazmirczak F, Chen K-HA, Farzaneh-Far A, Shenoy C. Myocardial involvement in patients with histologically diagnosed cardiac sarcoidosis: a systematic review and meta-analysis of gross pathological images from autopsy or cardiac transplantation cases. *J Am Heart Assoc* 2019;**8**:e011253. <https://doi.org/10.1161/JAHA.118.011253>
409. Iwai K, Tachibana T, Takemura T, Matsui Y, Kitalchi M, Kawabata Y. Pathological studies on sarcoidosis autopsy. I. Epidemiological features of 320 cases in Japan. *Acta Pathol Jpn* 1993;**43**:372–6. <https://doi.org/10.1111/j.1440-1827.1993.tb01148.x>

410. Perry A, Vuitch F. Causes of death in patients with sarcoidosis. A morphologic study of 38 autopsies with clinicopathologic correlations. *Arch Pathol Lab Med* 1995;**119**: 167–72.
411. Philips B, Madhavan S, James CA, te Riele ASJM, Murray B, Tichnell C, et al. Arrhythmogenic right ventricular dysplasia/cardiomyopathy and cardiac sarcoidosis: distinguishing features when the diagnosis is unclear. *Circ Arrhythm Electrophysiol* 2014;**7**:230–6. <https://doi.org/10.1161/CIRCEP.113.000932>
412. Gasperetti A, Rossi VA, Chiodini A, Casella M, Costa S, Akdis D, et al. Differentiating hereditary arrhythmogenic right ventricular cardiomyopathy from cardiac sarcoidosis fulfilling 2010 ARVC task force criteria. *Heart Rhythm* 2021;**18**:231–8. <https://doi.org/10.1016/j.hrthm.2020.09.015>
413. Corrado D, Perazzolo Marra M, Zorzi A, Boffagna G, Cipriani A, Lazzari MD, et al. Diagnosis of arrhythmogenic cardiomyopathy: the Padua criteria. *Int J Cardiol* 2020;**319**:106–14. <https://doi.org/10.1016/j.ijcard.2020.06.005>
414. Bagwan IN, Hooper LVB, Sheppard MN. Cardiac sarcoidosis and sudden death. The heart may look normal or mimic other cardiomyopathies. *Virchows Arch* 2011;**458**: 671–8. <https://doi.org/10.1007/s00428-010-1003-8>
415. Athwal PSS, Chhikara S, Ismail MF, Ismail K, Ogugua FM, Kazmirczak F, et al. Cardiovascular magnetic resonance imaging phenotypes and long-term outcomes in patients with suspected cardiac sarcoidosis. *JAMA Cardiol* 2022;**7**:1057–66. <https://doi.org/10.1001/jamacardio.2022.2981>
416. Azoulay L-D, Waintraub X, Haroche J, Amoura Z, Cohen Aubart F. Factors associated with implantable cardioverter defibrillators appropriate therapy in cardiac sarcoidosis: a meta-analysis. *Sarcoidosis Vasc Diffuse Lung Dis* 2020;**37**:17–23. <https://doi.org/10.36141/svld.v37i1.8271>
417. Sharma R, Kouranos V, Cooper LT, Metra M, Ristic A, Heidecker B, et al. Management of cardiac sarcoidosis. *Eur Heart J* 2024;**45**:2697–726. <https://doi.org/10.1093/eurheartj/ehae356>
418. Selan JC, Michaelson M, Fanburg BL, Estes NAM. Evaluation and management of heart rhythm disturbances due to cardiac sarcoidosis. *Heart Lung Circ* 2014;**23**:1100–9. <https://doi.org/10.1016/j.hlc.2014.07.065>
419. Ardehali H, Howard DL, Hariri A, Qasim A, Hare JM, Baughman KL, et al. A positive endomyocardial biopsy result for sarcoid is associated with poor prognosis in patients with initially unexplained cardiomyopathy. *Am Heart J* 2005;**150**:459–63. <https://doi.org/10.1016/j.ahj.2004.10.006>
420. Kouranos V, Tzelepis GE, Rapti A, Mavrogeni S, Aggeli K, Douskou M, et al. Complementary role of CMR to conventional screening in the diagnosis and prognosis of cardiac sarcoidosis. *JACC Cardiovasc Imaging* 2017;**10**:1437–47. <https://doi.org/10.1016/j.jcmg.2016.11.019>
421. Adhaduk M, Paudel B, Khalid MU, Ashwath M, Mansour S, Liu K. Comparison of cardiac magnetic resonance imaging and fluorodeoxyglucose positron emission tomography in the assessment of cardiac sarcoidosis: meta-analysis and systematic review. *J Nucl Cardiol* 2023;**30**:1574–87. <https://doi.org/10.1007/s12350-022-03129-8>
422. Orii M, Tanimoto T, Ota S, Takagi H, Tanaka R, Fujiwara J, et al. Diagnostic accuracy of cardiac magnetic resonance imaging for cardiac sarcoidosis in complete heart block patients implanted with magnetic resonance conditional pacemaker. *J Cardiol* 2020;**76**: 191–7. <https://doi.org/10.1016/j.jicc.2020.02.014>
423. Stanton KM, Ganigara M, Corte P, Celemajer DS, McGuire MA, Torzillo PJ, et al. The utility of cardiac magnetic resonance imaging in the diagnosis of cardiac sarcoidosis. *Heart Lung Circ* 2017;**26**:1191–9. <https://doi.org/10.1016/j.hlc.2017.02.021>
424. Patel MR, Cawley PJ, Heitner JF, Klem I, Parker MA, Jaroudi WA, et al. Detection of myocardial damage in patients with sarcoidosis. *Circulation* 2009;**120**:1969–77. <https://doi.org/10.1161/CIRCULATIONAHA.109.851352>
425. Zhang J, Li Y, Xu Q, Xu B, Wang H. Cardiac magnetic resonance imaging for diagnosis of cardiac sarcoidosis: a meta-analysis. *Can Respir J* 2018;**2018**:7457369. <https://doi.org/10.1155/2018/7457369>
426. Youssef G, Leung E, Mylonas I, Nery P, Williams K, Wisenberg G, et al. The use of ¹⁸F-FDG PET in the diagnosis of cardiac sarcoidosis: a systematic review and meta-analysis including the Ontario experience. *J Nucl Med* 2012;**53**:241–8. <https://doi.org/10.2967/jnumed.111.090662>
427. Dweck MR, Abgral R, Trivieri MG, Robson PM, Karakatsanis N, Mani V, et al. Hybrid magnetic resonance imaging and positron emission tomography with fluorodeoxyglucose to diagnose active cardiac sarcoidosis. *JACC Cardiovasc Imaging* 2018;**11**:94–107. <https://doi.org/10.1016/j.jcmg.2017.02.021>
428. Okumura W, Iwasaki T, Toyama T, Iso T, Arai M, Oriuchi N, et al. Usefulness of fasting ¹⁸F-FDG PET in identification of cardiac sarcoidosis. *J Nucl Med* 2004;**45**:1989–98. <https://doi.org/10.2967/jnumed.104.013352>
429. Vita T, Okada DR, Veillet-Chowdhury M, Bravo PE, Mullins E, Hulten E, et al. Complementary value of cardiac magnetic resonance imaging and positron emission tomography/computed tomography in the assessment of cardiac sarcoidosis. *Circ Cardiovasc Imaging* 2018;**11**:e007030. <https://doi.org/10.1161/CIRCIMAGING.117.007030>
430. Agoston-Coldea L, Kouaho S, Sacre K, Dossier A, Escoubet B, Chillon S, et al. High mass (>18 g) of late gadolinium enhancement on CMR imaging is associated with major cardiac events on long-term outcome in patients with biopsy-proven extracardiac sarcoidosis. *Int J Cardiol* 2016;**222**:950–6. <https://doi.org/10.1016/j.ijcard.2016.07.233>
431. Greulich S, Deluigi CC, Gloekler S, Wahl A, Zürn C, Kramer U, et al. CMR imaging predicts death and other adverse events in suspected cardiac sarcoidosis. *JACC Cardiovasc Imaging* 2015;**6**:501–11. <https://doi.org/10.1016/j.jcmg.2012.10.021>
432. Nadel J, Lancefield T, Voskoboinik A, Taylor AJ. Late gadolinium enhancement identified with cardiac magnetic resonance imaging in sarcoidosis patients is associated with long-term ventricular arrhythmia and sudden cardiac death. *Eur Heart J Cardiovasc Imaging* 2015;**16**:634–41. <https://doi.org/10.1093/ehjci/jeu294>
433. Murtagh G, Laffin LJ, Beshai JF, Maffessanti F, Bonham CA, Patel AV, et al. Prognosis of myocardial damage in sarcoidosis patients with preserved left ventricular ejection fraction: risk stratification using cardiovascular magnetic resonance. *Circ Cardiovasc Imaging* 2016;**9**:e003738. <https://doi.org/10.1161/CIRCIMAGING.115.003738>
434. Coleman GC, Shaw PW, Balfour PC, Gonzalez JA, Kramer CM, Patel AR, et al. Prognostic value of myocardial scarring on CMR in patients with cardiac sarcoidosis. *JACC Cardiovasc Imaging* 2017;**10**:411–20. <https://doi.org/10.1016/j.jcmg.2016.05.009>
435. Smedema J-P, van Geuns R-J, Ector J, Heidebuechel H, Ainslie G, Crijns HJGM. Right ventricular involvement and the extent of left ventricular enhancement with magnetic resonance predict adverse outcome in pulmonary sarcoidosis. *ESC Heart Fail* 2018;**5**: 157–71. <https://doi.org/10.1002/ehf2.12201>
436. Velangi PS, Chen K-HA, Kazmirczak F, Okasha O, von Wald L, Roukoz H, et al. Right ventricular abnormalities on cardiovascular magnetic resonance imaging in patients with sarcoidosis. *JACC Cardiovasc Imaging* 2020;**13**:1395–405. <https://doi.org/10.1016/j.jcmg.2019.12.011>
437. Greulich S, Kitterer D, Latus J, Aguirre E, Steubing H, Kaesemann P, et al. Comprehensive cardiovascular magnetic resonance assessment in patients with sarcoidosis and preserved left ventricular ejection fraction. *Circ Cardiovasc Imaging* 2016;**9**:e005022. <https://doi.org/10.1161/CIRCIMAGING.116.005022>
438. Puntmann VO, Isted A, Hinojar R, Foote L, Carr-White G, Nagel E. T1 and T2 mapping in recognition of early cardiac involvement in systemic sarcoidosis. *Radiology* 2017;**285**: 63–72. <https://doi.org/10.1148/radiol.2017162732>
439. Crouser ED, Ruden E, Julian MW, Raman SV. Resolution of abnormal cardiac MRI T2 signal following immune suppression for cardiac sarcoidosis. *J Investig Med* 2016;**64**: 1148–50. <https://doi.org/10.1136/jim-2016-000144>
440. Greulich S, Gatidis S, Gräni C, Blankstein R, Glatthaar A, Mezger K, et al. Hybrid cardiac magnetic resonance/fluorodeoxyglucose positron emission tomography to differentiate active from chronic cardiac sarcoidosis. *JACC Cardiovasc Imaging* 2022;**15**:445–56. <https://doi.org/10.1016/j.jcmg.2021.08.018>
441. Crouser ED, Ono C, Tran T, He X, Raman SV. Improved detection of cardiac sarcoidosis using magnetic resonance with myocardial T2 mapping. *Am J Respir Crit Care Med* 2014;**189**:109–12. <https://doi.org/10.1164/rccm.201309-1668LE>
442. Cheung E, Ahmad S, Aitken M, Chan R, Iwanochko RM, Balter M, et al. Combined simultaneous FDG-PET/MRI with T1 and T2 mapping as an imaging biomarker for the diagnosis and prognosis of suspected cardiac sarcoidosis. *Eur J Hybrid Imaging* 2021;**5**:24. <https://doi.org/10.1186/s41824-021-00119-w>
443. Wicks EC, Menezes LJ, Barnes A, Mohiddin SA, Sekhri N, Porter JC, et al. Diagnostic accuracy and prognostic value of simultaneous hybrid ¹⁸F-fluorodeoxyglucose positron emission tomography/magnetic resonance imaging in cardiac sarcoidosis. *Eur Heart J Cardiovasc Imaging* 2018;**19**:757–67. <https://doi.org/10.1093/ehjci/ehx340>
444. Aitken M, Davidson M, Chan MV, Urzua Fresno C, Vasquez LI, Huo YR, et al. Prognostic value of cardiac MRI and FDG PET in cardiac sarcoidosis: a systematic review and meta-analysis. *Radiology* 2023;**307**:e222483. <https://doi.org/10.1148/radiol.222483>
445. Mc Ardle BA, Birnie DH, Klein R, de Kemp RA, Leung E, Renaud J, et al. Is there an association between clinical presentation and the location and extent of myocardial involvement of cardiac sarcoidosis as assessed by ¹⁸F-fluorodeoxyglucose positron emission tomography? *Circ Cardiovasc Imaging* 2013;**6**:617–26. <https://doi.org/10.1161/CIRCIMAGING.112.000289>
446. Muser D, Santangeli P, Castro SA, Liang JJ, Enriquez A, Werner TJ, et al. Prognostic role of serial quantitative evaluation of ¹⁸F-fluorodeoxyglucose uptake by PET/CT in patients with cardiac sarcoidosis presenting with ventricular tachycardia. *Eur J Nucl Med Mol Imaging* 2018;**45**:1394–404. <https://doi.org/10.1007/s00259-018-4001-8>
447. Ahmed AI, Abebe AT, Han Y, Alnabelsi T, Agrawal T, Kassi M, et al. The prognostic role of cardiac positron emission tomography imaging in patients with sarcoidosis: a systematic review. *J Nucl Cardiol* 2021;**28**:1545–52. <https://doi.org/10.1007/s12350-021-02681-z>
448. Flores RJ, Flaherty KR, Jin Z, Bokhari S. The prognostic value of quantitating and localizing F-18 FDG uptake in cardiac sarcoidosis. *J Nucl Cardiol* 2020;**27**:2003–10. <https://doi.org/10.1007/s12350-018-01504-y>
449. Sperry BW, Tamarappoo BK, Oldan JD, Javed O, Culver DA, Brunken R, et al. Prognostic impact of extent, severity, and heterogeneity of abnormalities on ¹⁸F-FDG PET scans for suspected cardiac sarcoidosis. *JACC Cardiovasc Imaging* 2018;**11**: 336–45. <https://doi.org/10.1016/j.jcmg.2017.04.020>
450. Osborne MT, Hulsten EA, Singh A, Waller AH, Bittencourt MS, Stewart GC, et al. Reduction in ¹⁸F-fluorodeoxyglucose uptake on serial cardiac positron emission tomography is associated with improved left ventricular ejection fraction in patients with cardiac sarcoidosis. *J Nucl Cardiol* 2014;**21**:166–74. <https://doi.org/10.1007/s12350-013-9828-6>

451. Birnie D, Beanlands RSB, Nery P, Aaron SD, Culver DA, DeKemp RA, et al. Cardiac sarcoidosis multi-center randomized controlled trial (CHASM CS- RCT). *Am Heart J* 2020;**220**:246–52. <https://doi.org/10.1016/j.ahj.2019.10.003>
452. Nordenswan H-K, Lehtonen J, Ekström K, Kandolin R, Simonen P, Mäyränpää M, et al. Outcome of cardiac sarcoidosis presenting with high-grade atrioventricular block. *Circ Arrhythm Electrophysiol* 2018;**11**:e006145. <https://doi.org/10.1161/CIRCEP.117.006145>
453. Halawa A, Jain R, Turagam MK, Kusumoto FM, Woldu HG, Gautam S. Outcome of implantable cardioverter defibrillator in cardiac sarcoidosis: a systematic review and meta-analysis. *J Interv Card Electrophysiol* 2020;**58**:233–42. <https://doi.org/10.1007/s10840-020-00705-1>
454. Schuller JL, Zipse M, Crawford T, Bogun F, Beshai J, Patel AR, et al. Implantable cardioverter defibrillator therapy in patients with cardiac sarcoidosis. *J Cardiovasc Electrophysiol* 2012;**23**:925–9. <https://doi.org/10.1111/j.1540-8167.2012.02350.x>
455. Betensky BP, Tschabrunn CM, Zado ES, Goldberg LR, Marchlinski FE, Garcia FC, et al. Long-term follow-up of patients with cardiac sarcoidosis and implantable cardioverter-defibrillators. *Heart Rhythm* 2012;**9**:884–91. <https://doi.org/10.1016/j.hrthm.2012.02.010>
456. Franke KB, Marshall H, Kennewell P, Pham H-D, Tully PJ, Rattanakositt T, et al. Risk and predictors of sudden death in cardiac sarcoidosis: a systematic review and meta-analysis. *Int J Cardiol* 2021;**328**:130–40. <https://doi.org/10.1016/j.ijcard.2020.11.044>
457. Mathijssen H, Bakker ALM, Balt JC, Akdim F, van Es HW, Veltkamp M, et al. Predictors of appropriate implantable cardiac defibrillator therapy in cardiac sarcoidosis. *J Cardiovasc Electrophysiol* 2022;**33**:1272–80. <https://doi.org/10.1111/jce.15484>
458. Crawford T, Mueller G, Sarsam S, Prasitdumrong H, Chaiyen N, Gu X, et al. Magnetic resonance imaging for identifying patients with cardiac sarcoidosis and preserved or mildly reduced left ventricular function at risk of ventricular arrhythmias. *Circ Arrhythm Electrophysiol* 2014;**7**:1109–15. <https://doi.org/10.1161/CIRCEP.113.000156>
459. Shafee MA, Fukuda K, Wakayama Y, Nakano M, Kondo M, Hasebe Y, et al. Delayed enhancement on cardiac magnetic resonance imaging is a poor prognostic factor in patients with cardiac sarcoidosis. *J Cardiol* 2012;**60**:448–53. <https://doi.org/10.1016/j.jicc.2012.08.002>
460. Mehta D, Mori N, Goldbarb SH, Lubitz S, Wisnivesky JP, Teirstein A. Primary prevention of sudden cardiac death in silent cardiac sarcoidosis: role of programmed ventricular stimulation. *Circ Arrhythm Electrophysiol* 2011;**4**:43–8. <https://doi.org/10.1161/CIRCEP.110.958322>
461. Okada DR, Smith J, Derakhshan A, Gowani Z, Zimmerman SL, Misra S, et al. Electrophysiology study for risk stratification in patients with cardiac sarcoidosis and abnormal cardiac imaging. *Int J Cardiol Heart Vasc* 2019;**23**:100342. <https://doi.org/10.1016/j.ijcha.2019.03.002>
462. Adhaduk M, Paudel B, Liu K, Ashwath M, Giudici M. The role of electrophysiology study in risk stratification of cardiac sarcoidosis patients: meta-analyses and systemic review. *Int J Cardiol* 2022;**349**:55–61. <https://doi.org/10.1016/j.ijcard.2021.11.061>
463. Zipse MM, Tzou VS, Schuller JL, Aleong RG, Varosy PD, Tompkins C, et al. Electrophysiologic testing for diagnostic evaluation and risk stratification in patients with suspected cardiac sarcoidosis with preserved left and right ventricular systolic function. *J Cardiovasc Electrophysiol* 2019;**30**:1939–48. <https://doi.org/10.1111/jce.14058>
464. Tandon P, Mosleh T, Mustafa A, Miodownik H, Miller M, Morgenthau AS. Utility of electrophysiologic testing for sudden death risk stratification in cardiac sarcoidosis patients with mildly impaired left ventricular function. *Respir Med* 2022;**191**:106712. <https://doi.org/10.1016/j.rmed.2021.106712>
465. Blankstein R, Osborne M, Naya M, Waller A, Kim CK, Murthy VL, et al. Cardiac positron emission tomography enhances prognostic assessments of patients with suspected cardiac sarcoidosis. *J Am Coll Cardiol* 2014;**63**:329–36. <https://doi.org/10.1016/j.jacc.2013.09.022>
466. Kron J, Sauer W, Schuller J, Bogun F, Crawford T, Sarsam S, et al. Efficacy and safety of implantable cardiac defibrillators for treatment of ventricular arrhythmias in patients with cardiac sarcoidosis. *Europace* 2013;**15**:347–54. <https://doi.org/10.1093/europace/eus316>
467. Stevenson A, Bray JJH, Tregidlo L, Ahmad M, Sharma A, Ng A, et al. Prognostic value of late gadolinium enhancement detected on cardiac magnetic resonance in cardiac sarcoidosis. *JACC Cardiovasc Imaging* 2023;**16**:345–57. <https://doi.org/10.1016/j.jcmg.2022.10.018>
468. Veronese G, Ammirati E, Brambatti M, Merlo M, Cipriani M, Potena L, et al. Viral genome search in myocardium of patients with fulminant myocarditis. *Eur J Heart Fail* 2020;**22**:1277–80. <https://doi.org/10.1002/ehf.1738>
469. Sinagra G, Porcari A, Gentile P, Artico J, Fabris E, Bussani R, et al. Viral presence-guided immunomodulation in lymphocytic myocarditis: an update. *Eur J Heart Fail* 2021;**23**:211–6. <https://doi.org/10.1002/ehf.1969>
470. Moimas S, Zacchigna S, Merlo M, Buiatti A, Anzini M, Dreas L, et al. Idiopathic dilated cardiomyopathy and persistent viral infection: lack of association in a controlled study using a quantitative assay. *Heart Lung Circ* 2012;**21**:787–93. <https://doi.org/10.1016/j.hlc.2012.07.013>
471. Stewart GC, Lopez-Molina J, Gottumukkala RVSRK, Rosner GF, Anello MS, Hecht JL, et al. Myocardial parvovirus B19 persistence: lack of association with clinicopathologic phenotype in adults with heart failure. *Circ Heart Fail* 2011;**4**:71–8. <https://doi.org/10.1161/CIRCHEARTFAILURE.110.958249>
472. Robinson J, Hartling L, Vandermeer B, Sebastiani M, Klassen TP. Intravenous immunoglobulin for presumed viral myocarditis in children and adults. *Cochrane Database Syst Rev* 2020;**8**:CD004370. <https://doi.org/10.1002/14651858.CD004370.pub4>
473. Kühl U, Pauschinger M, Schwimmbeck PL, Seeberg B, Lober C, Noutsias M, et al. Interferon- β treatment eliminates cardiotropic viruses and improves left ventricular function in patients with myocardial persistence of viral genomes and left ventricular dysfunction. *Circulation* 2003;**107**:2793–8. <https://doi.org/10.1161/01.CIR.0000072766.67150.51>
474. Kühl U, Lassner D, von Schlippenbach J, Poller W, Schultheiss H-P. Interferon-beta improves survival in enterovirus-associated cardiomyopathy. *J Am Coll Cardiol* 2012;**60**:1295–6. <https://doi.org/10.1016/j.jacc.2012.06.026>
475. Schultheiss H-P, Bock C-T, Aleshcheva G, Baumeier C, Poller W, Escher F. Interferon- β suppresses transcriptionally active parvovirus B19 infection in viral cardiomyopathy: a subgroup analysis of the BICC-trial. *Viruses* 2022;**14**:444. <https://doi.org/10.3390/v14020444>
476. Cobas M, Abbo L, Santos M, Baccini-Jauregui C, Pham S. Successful management of fulminant influenza A subtype H1N1 myocarditis. *BMJ Case Rep* 2010;**2010**:bcr0220102763. <https://doi.org/10.1136/bcr.02.2010.2763>
477. Baik SH, Jeong HS, Kim SJ, Yoon YK, Sohn JW, Kim MJ. A case of influenza associated fulminant myocarditis successfully treated with intravenous peramivir. *Infect Chemother* 2015;**47**:272–7. <https://doi.org/10.3947/ic.2015.47.4.272>
478. Jahns F-P, Ben-Hamouda N, Kirsch M, Roumy A, Liaudet L. Intravenous zanamivir for influenza myocarditis and enteral malabsorption. *Crit Care* 2018;**22**:332. <https://doi.org/10.1186/s13054-018-2263-y>
479. Mazzitelli M, Garofalo E, Bruni A, Barreca GS, Quirino A, Giaccotti A, et al. Severe myocarditis due to influenza A(H1N1)pdm09 viral infection in a young woman successfully treated with intravenous zanamivir: a case report. *Clin Case Rep* 2019;**7**:2336–40. <https://doi.org/10.1002/ccr.3.2499>
480. Yoshimizu N, Tominaga T, Ito T, Nishida Y, Wada Y, Sohmiya K, et al. Repetitive fulminant influenza myocarditis requiring the use of circulatory assist devices. *Intern Med* 2014;**53**:109–14. <https://doi.org/10.2169/internalmedicine.53.1117>
481. Khouzam RN, Parizianu C, Hafiz AM, Chawla S, Schwartz R. Fulminant myocarditis associated with novel H1N1 influenza A. *Heart Lung* 2011;**40**:566–8. <https://doi.org/10.1016/j.hrtlng.2011.01.004>
482. Ito N, Sato M, Momoi N, Aoyagi Y, Endo K, Chishiki M, et al. Influenza A H1N1 pdm09-associated myocarditis during zanamivir therapy. *Pediatr Int* 2015;**57**:1172–4. <https://doi.org/10.1111/ped.12712>
483. Pugliese A, Isnardi D, Saini A, Scarabelli T, Raddino R, Torre D. Impact of highly active antiretroviral therapy in HIV-positive patients with cardiac involvement. *J Infect* 2000;**40**:282–4. <https://doi.org/10.1053/j.jinf.2000.0672>
484. Steere AC, Batsford WP, Weinberg M, Alexander J, Berger HJ, Wolfson S, et al. Lyme carditis: cardiac abnormalities of Lyme disease. *Ann Intern Med* 1980;**93**:8–16. <https://doi.org/10.7326/0003-4819-93-1-8>
485. Besant G, Wan D, Yeung C, Blakely C, Branscombe P, Suarez-Fuster L, et al. Suspicious index in Lyme carditis: systematic review and proposed new risk score. *Clin Cardiol* 2018;**41**:1611–6. <https://doi.org/10.1002/clc.23102>
486. Lantos PM, Rumbaugh J, Bockenstedt LK, Falck-Ytter YT, Aguero-Rosenfeld ME, Auwaerter PG, et al. Clinical Practice Guidelines by the Infectious Diseases Society of America (IDSA), American Academy of Neurology (AAN), and American College of Rheumatology (ACR): 2020 guidelines for the prevention, diagnosis, and treatment of Lyme disease. *Arthritis Care Res (Hoboken)* 2021;**73**:1–9. <https://doi.org/10.1002/acr.24495>
487. Costello JM, Alexander ME, Greco KM, Perez-Atayde AR, Laussen PC. Lyme carditis in children: presentation, predictive factors, and clinical course. *Pediatrics* 2009;**123**:e835–841. <https://doi.org/10.1542/peds.2008-3058>
488. Nunes MCP, Badano LP, Marin-Neto JA, Edvardsen T, Fernández-Golfín C, Bucciarelli-Ducci C, et al. Multimodality imaging evaluation of Chagas disease: an expert consensus of Brazilian Cardiovascular Imaging Department (DIC) and the European Association of Cardiovascular Imaging (EACVI). *Eur Heart J Cardiovasc Imaging* 2018;**19**:459–60. <https://doi.org/10.1093/ehjci/jex154>
489. Morillo CA, Marin-Neto JA, Avezum A, Sosa-Estani S, Rassi A, Rosas F, et al. Randomized trial of benznidazole for chronic Chagas' cardiomyopathy. *N Engl J Med* 2015;**373**:1295–306. <https://doi.org/10.1056/NEJMoa1507574>
490. Pérez-Molina JA, Pérez-Ayala A, Moreno S, Fernández-González MC, Zamora J, López-Velaz R. Use of benznidazole to treat chronic Chagas' disease: a systematic review with a meta-analysis. *J Antimicrob Chemother* 2009;**64**:1139–47. <https://doi.org/10.1093/jac/dkp357>
491. Viotti R, Vigliano C, Lococo B, Bertocchi G, Petti M, Alvarez MG, et al. Long-term cardiac outcomes of treating chronic Chagas disease with benznidazole versus no treatment: a nonrandomized trial. *Ann Intern Med* 2006;**144**:724–34. <https://doi.org/10.7326/0003-4819-144-10-200605160-00006>

492. Chadalawada S, Rassi A, Samara O, Monzon A, Gudapati D, Vargas Barahona L, et al. Mortality risk in chronic Chagas cardiomyopathy: a systematic review and meta-analysis. *ESC Heart Fail* 2021;**8**:5466–81. <https://doi.org/10.1002/ehf2.13648>
493. Carmo AAL, de Sousa MR, Agudelo JF, Boersma E, Rocha MOC, Ribeiro ALP, et al. Implantable cardioverter-defibrillator in Chagas heart disease: a systematic review and meta-analysis of observational studies. *Int J Cardiol* 2018;**267**:88–93. <https://doi.org/10.1016/j.ijcard.2018.05.091>
494. Rassi FM, Minohara L, Rassi A, Correia LCL, Marin-Neto JA, Rassi A, et al. Systematic review and meta-analysis of clinical outcome after implantable cardioverter-defibrillator therapy in patients with Chagas heart disease. *JACC Clin Electrophysiol* 2019;**5**:1213–23. <https://doi.org/10.1016/j.jacep.2019.07.003>
495. Mahmood SS, Fradley MG, Cohen JV, Nohria A, Reynolds KL, Heinzerling LM, et al. Myocarditis in patients treated with immune checkpoint inhibitors. *J Am Coll Cardiol* 2018;**71**:1755–64. <https://doi.org/10.1016/j.jacc.2018.02.037>
496. Salem J-E, Manouchehri A, Moey M, Lebrun-Vignes B, Bastarache L, Pariente A, et al. Cardiovascular toxicities associated with immune checkpoint inhibitors: an observational, retrospective, pharmacovigilance study. *Lancet Oncol* 2018;**19**:1579–89. [https://doi.org/10.1016/S1470-2045\(18\)30608-9](https://doi.org/10.1016/S1470-2045(18)30608-9)
497. Suzuki Y, Kaneko H, Tamura Y, Okada A, Fujiu K, Michihata N, et al. Cardiovascular events after the initiation of immune checkpoint inhibitors. *Heliyon* 2023;**9**:e16373. <https://doi.org/10.1016/j.heliyon.2023.e16373>
498. Nguyen LS, Cooper LT, Kerneis M, Funck-Brentano C, Silvain J, Brechet N, et al. Systematic analysis of drug-associated myocarditis reported in the World Health Organization pharmacovigilance database. *Nat Commun* 2022;**13**:25. <https://doi.org/10.1038/s41467-021-27631-8>
499. Liu M, Cheng X, Ni R, Zheng B, Huang S, Yang J. Cardiotoxicity of immune checkpoint inhibitors: a frequency network meta-analysis. *Front Immunol* 2022;**13**:1006860. <https://doi.org/10.3389/fimmu.2022.1006860>
500. Pradhan R, Nautiyal A, Singh S. Diagnosis of immune checkpoint inhibitor-associated myocarditis: a systematic review. *Int J Cardiol* 2019;**296**:113–21. <https://doi.org/10.1016/j.ijcard.2019.07.025>
501. Lyon AR, López-Fernández T, Couch LS, Asteggiano R, Aznar MC, Bergler-Klein J, et al. 2022 ESC Guidelines on cardio-oncology developed in collaboration with the European Hematology Association (EHA), the European Society for Therapeutic Radiology and Oncology (ESTRO) and the International Cardio-Oncology Society (IC-OS). *Eur Heart J* 2022;**43**:4229–361. <https://doi.org/10.1093/eurheartj/ehac244>
502. Salem J-E, Bretagne M, Abbar B, Leonard-Louis S, Ederhy S, Redheuil A, et al. Abatacept/ruxolitinib and screening for concomitant respiratory muscle failure to mitigate fatality of immune-checkpoint inhibitor myocarditis. *Cancer Discov* 2023;**13**:1100–15. <https://doi.org/10.1158/2159-8290.CD-22-1180>
503. L'Orphelin J-M, Dollalille C, Akroun J, Alexandre J, Domp Martin A. Cardiovascular immunotoxicity associated with immune checkpoint inhibitors in metastatic melanoma. *Cancers (Basel)* 2023;**15**:2170. <https://doi.org/10.3390/cancers15072170>
504. Tocchetti CG, Farmakis D, Koop Y, Andres MS, Couch LS, Formisano L, et al. Cardiovascular toxicities of immune therapies for cancer—a scientific statement of the Heart Failure Association (HFA) of the ESC and the ESC Council of Cardio-Oncology. *Eur J Heart Fail* 2024;**26**:2055–76. <https://doi.org/10.1002/ehfj.3340>
505. Dollalille C, Ederhy S, Sassi M, Cautela J, Thuny F, Cohen AA, et al. Immune checkpoint inhibitor rechallenge after immune-related adverse events in patients with cancer. *JAMA Oncol* 2020;**6**:865–71. <https://doi.org/10.1001/jamaoncol.2020.0726>
506. Clapham E, Reutfors J, Linder M, Brandt L, Sundström J, Bodén R. The association between exposure to clozapine, olanzapine, and quetiapine and the outcomes perimyocarditis and heart failure: a population-based cohort study. *Psychiatry Res* 2023;**326**:115336. <https://doi.org/10.1016/j.psychres.2023.115336>
507. Sandarsh S, Bishnoi RJ, Shashank RB, Miller BJ, Freudenreich O, McEvoy JP. Monitoring for myocarditis during treatment initiation with clozapine. *Acta Psychiatr Scand* 2021;**144**:194–200. <https://doi.org/10.1111/acps.13328>
508. Siskind D, Sidhu A, Cross J, Chua Y-T, Myles N, Cohen D, et al. Systematic review and meta-analysis of rates of clozapine-associated myocarditis and cardiomyopathy. *Aust N Z J Psychiatry* 2020;**54**:467–81. <https://doi.org/10.1177/0004867419898760>
509. Sereevaphinan C, Assanangkornchai N, Nilmoje T. Prolonged extracorporeal membrane oxygenation support in a patient with drug reaction with eosinophilia and systemic symptoms syndrome-associated fulminant myocarditis—a case report and literature review. *Heart Int* 2020;**14**:112–7. <https://doi.org/10.17925/HI.2020.14.2.112>
510. Bonhoeffer J, Kohl K, Chen R, Duclos P, Heijbel H, Heining U, et al. The Brighton Collaboration: addressing the need for standardized case definitions of adverse events following immunization (AEFI). *Vaccine* 2002;**21**:298–302. [https://doi.org/10.1016/S0264-410X\(02\)00449-8](https://doi.org/10.1016/S0264-410X(02)00449-8)
511. Engler RJM, Montgomery JR, Spooner CE, Nelson MR, Collins LC, Ryan MA, et al. Myocarditis and pericarditis recovery following smallpox vaccine 2002–2016: a comparative observational cohort study in the military health system. *PLoS One* 2023;**18**:e0283988. <https://doi.org/10.1371/journal.pone.0283988>
512. Parmar K, Subramanyam S, Del Rio-Pertuz G, Sethi P, Argueta-Sosa E. Cardiac adverse events after vaccination—a systematic review. *Vaccines (Basel)* 2022;**10**:700. <https://doi.org/10.3390/vaccines10050700>
513. Thanjan MT, Ramaswamy P, Lai VVV, Lytrivi ID. Acute myopericarditis after multiple vaccinations in an adolescent: case report and review of the literature. *Pediatrics* 2007;**119**:e1400–3. <https://doi.org/10.1542/peds.2006-2605>
514. Dilber E, Karagöz T, Aytemir K, Ozer S, Alehan D, Oto A, et al. Acute myocarditis associated with tetanus vaccination. *Mayo Clin Proc* 2003;**78**:1431–3. <https://doi.org/10.4065/78.11.1431-a>
515. Boccarda F, Benhaïem-Sigaux N, Cohen A. Acute myopericarditis after diphtheria, tetanus, and polio vaccination. *Chest* 2001;**120**:671–2. <https://doi.org/10.1378/chest.120.2.671>
516. Barton M, Finkelstein Y, Opavsky MA, Ito S, Ho T, Ford-Jones LE, et al. Eosinophilic myocarditis temporally associated with conjugate meningococcal C and hepatitis B vaccines in children. *Pediatr Infect Dis J* 2008;**27**:831–5. <https://doi.org/10.1097/INF.0b013e31816ff7b2>
517. Lu J, Zhang X, Xu H, Li Z. Inspiration to mRNA-based COVID-19 vaccination: serious adverse case reports with hepatitis B vaccine in real-world. *Front Pediatr* 2022;**10**:888686. <https://doi.org/10.3389/fped.2022.888686>
518. Nagano N, Yano T, Fujita Y, Koyama M, Hasegawa R, Nakata J, et al. Hemodynamic collapse after influenza vaccination: a vaccine-induced fulminant myocarditis? *Can J Cardiol* 2020;**36**:1554.e5–e7. <https://doi.org/10.1016/j.cjca.2020.05.005>
519. Jain SS, Anderson SA, Steele JM, Wilson HC, Muniz JC, Soslow JH, et al. Cardiac manifestations and outcomes of COVID-19 vaccine-associated myocarditis in the young in the USA: longitudinal results from the Myocarditis After COVID Vaccination (MACiV) multicenter study. *EClinicalMedicine* 2024;**76**:102809. <https://doi.org/10.1016/j.eclinm.2024.102809>
520. Peretto G, Micaglio E, Cicone G, Maia M, Luzzi M, Cariello M, et al. The 'arrhythmic' presentation of peripartum cardiomyopathy: case series and critical review of the literature. *Front Cardiovasc Med* 2024;**11**:1362692. <https://doi.org/10.3389/fcvm.2024.1362692>
521. Hoevelmann J, Engel ME, Muller E, Hohfeld A, Böhm M, Sliwa K, et al. A global perspective on the management and outcomes of peripartum cardiomyopathy: a systematic review and meta-analysis. *Eur J Heart Fail* 2022;**24**:1719–36. <https://doi.org/10.1002/ehfj.2603>
522. Gunderson EP, Croen LA, Chiang V, Yoshida CK, Walton D, Go AS. Epidemiology of peripartum cardiomyopathy: incidence, predictors, and outcomes. *Obstet Gynecol* 2011;**118**:583–91. <https://doi.org/10.1097/AOG.0b013e318229e6de>
523. Karaye KM, Ishaq NA, Sa'idu H, Balarabe SA, Talle MA, Isa MS, et al. Incidence, clinical characteristics, and risk factors of peripartum cardiomyopathy in Nigeria: results from the PEACE Registry. *ESC Heart Fail* 2020;**7**:235–43. <https://doi.org/10.1002/ehf2.12562>
524. Goli R, Li J, Brandimarto J, Levine LD, Riis V, McAfee Q, et al. Genetic and phenotypic landscape of peripartum cardiomyopathy. *Circulation* 2021;**143**:1852–62. <https://doi.org/10.1161/CIRCULATIONAHA.120.052395>
525. Mallikethi-Reddy S, Akintoye E, Trehan N, Sharma S, Briasoulis A, Jagadeesh K, et al. Burden of arrhythmias in peripartum cardiomyopathy: analysis of 9841 hospitalizations. *Int J Cardiol* 2017;**235**:114–7. <https://doi.org/10.1016/j.ijcard.2017.02.084>
526. Sliwa K, Hilfiker-Kleiner D, Petrie MC, Mebazaa A, Pieske B, Buchmann E, et al. Current state of knowledge on aetiology, diagnosis, management, and therapy of peripartum cardiomyopathy: a position statement from the Heart Failure Association of the European Society of Cardiology Working Group on peripartum cardiomyopathy. *Eur J Heart Fail* 2010;**12**:767–78. <https://doi.org/10.1093/eurjhf/hfq120>
527. Tanous D, Siu SC, Mason J, Greutmann M, Wald RM, Parker JD, et al. B-type natriuretic peptide in pregnant women with heart disease. *J Am Coll Cardiol* 2010;**56**:1247–53. <https://doi.org/10.1016/j.jacc.2010.02.076>
528. Esbrand FD, Zafar S, Panthangi V, Cyril Kurupp AR, Raju A, Luthra G, et al. Utility of N-terminal (NT)-brain natriuretic peptide (proBNP) in the diagnosis and prognosis of pregnancy associated cardiovascular conditions: a systematic review. *Cureus* 2022;**14**:e32848. <https://doi.org/10.7759/cureus.32848>
529. Li W, Li H, Long Y. Clinical characteristics and long-term predictors of persistent left ventricular systolic dysfunction in peripartum cardiomyopathy. *Can J Cardiol* 2016;**32**:362–8. <https://doi.org/10.1016/j.cjca.2015.07.733>
530. Arora NP, Mahajan N, Mohamad T, Kottam A, Afonso LC, Danrad R, et al. Cardiac magnetic resonance imaging in peripartum cardiomyopathy. *Am J Med Sci* 2014;**347**:112–7. <https://doi.org/10.1097/MAJ.0b013e31828155e3>
531. Ordovas KG, Baldassarre LA, Bucciarelli-Ducci C, Carr J, Fernandes JL, Ferreira VM, et al. Cardiovascular magnetic resonance in women with cardiovascular disease: position statement from the Society for Cardiovascular Magnetic Resonance (SCMR). *J Cardiovasc Magn Reson* 2021;**23**:52. <https://doi.org/10.1186/s12968-021-00746-z>
532. Ray JG, Vermeulen MJ, Bharatha A, Montanera VJ, Park AL. Association between MRI exposure during pregnancy and fetal and childhood outcomes. *JAMA* 2016;**316**:952–61. <https://doi.org/10.1001/jama.2016.12126>
533. Schelbert EB, Elkayam U, Cooper LT, Givertz MM, Alexis JD, Briller J, et al. Myocardial damage detected by late gadolinium enhancement cardiac magnetic resonance is uncommon in peripartum cardiomyopathy. *J Am Heart Assoc* 2017;**6**:e005472. <https://doi.org/10.1161/JAHA.117.005472>
534. Cooper LT, Mather PJ, Alexis JD, Pauly DF, Torre-Amione G, Wittstein IS, et al. Myocardial recovery in peripartum cardiomyopathy: prospective comparison with

- recent onset cardiomyopathy in men and nonperipartum women. *J Card Fail* 2012;**18**: 28–33. <https://doi.org/10.1016/j.cardfail.2011.09.009>
535. McNamara DM, Elkayam U, Alharethi R, Damp J, Hsieh E, Ewald G, et al. Clinical outcomes for peripartum cardiomyopathy in North America: results of the IPAC study (investigations of pregnancy-associated cardiomyopathy). *J Am Coll Cardiol* 2015;**66**: 905–14. <https://doi.org/10.1016/j.jacc.2015.06.1309>
536. Biteker M, Özlek B, Özlek E, Çil C, Çelik O, Doğan V, et al. Predictors of early and delayed recovery in peripartum cardiomyopathy: a prospective study of 52 patients. *J Matern Fetal Neonatal Med* 2020;**33**:390–7. <https://doi.org/10.1080/14767058.2018.1494146>
537. Fett JD, Christie LG, Carraway RD, Murphy JG. Five-year prospective study of the incidence and prognosis of peripartum cardiomyopathy at a single institution. *Mayo Clin Proc* 2005;**80**:1602–6. <https://doi.org/10.4065/80.12.1602>
538. Moulig V, Pfeffer TJ, Ricke-Hoch M, Schlothauer S, Koenig T, Schwab J, et al. Long-term follow-up in peripartum cardiomyopathy patients with contemporary treatment: low mortality, high cardiac recovery, but significant cardiovascular co-morbidities. *Eur J Heart Fail* 2019;**21**:1534–42. <https://doi.org/10.1002/ehf.1624>
539. Sliwa K, Azibani F, Baard J, Osman A, Zühlke L, Lachmann A, et al. Reducing late maternal death due to cardiovascular disease—a pragmatic pilot study. *Int J Cardiol* 2018;**272**:70–6. <https://doi.org/10.1016/j.ijcard.2018.07.140>
540. Bauersachs J, Arrigo M, Hilfiker-Kleiner D, Veltmann C, Coats AJS, Crespo-Leiro MG, et al. Current management of patients with severe acute peripartum cardiomyopathy: practical guidance from the Heart Failure Association of the European Society of Cardiology Study Group on peripartum cardiomyopathy. *Eur J Heart Fail* 2016;**18**: 1096–105. <https://doi.org/10.1002/ehf.586>
541. Fu K, Zhang H, Chen N, Hu Y, Xiao J, Zhang X, et al. Risk factors for intracardiac thrombus in peripartum cardiomyopathy: a retrospective study in China. *ESC Heart Fail* 2023;**10**:148–58. <https://doi.org/10.1002/ehf2.14158>
542. Hilfiker-Kleiner D, Haghikia A, Berliner D, Vogel-Claussen J, Schwab J, Franke A, et al. Bromocriptine for the treatment of peripartum cardiomyopathy: a multicentre randomized study. *Eur Heart J* 2017;**38**:2671–9. <https://doi.org/10.1093/eurheartj/ehx355>
543. Sliwa K, Blauwet L, Tibazarwa K, Libhaber E, Smedema J-P, Becker A, et al. Evaluation of bromocriptine in the treatment of acute severe peripartum cardiomyopathy: a proof-of-concept pilot study. *Circulation* 2010;**121**:1465–73. <https://doi.org/10.1161/CIRCULATIONAHA.109.901496>
544. Kumar A, Ravi R, Sivakumar RK, Chidambaram V, Majella MG, Sinha S, et al. Prolactin inhibition in peripartum cardiomyopathy: systematic review and meta-analysis. *Curr Probl Cardiol* 2023;**48**:101461. <https://doi.org/10.1016/j.cpcardiol.2022.101461>
545. Trongsorsak A, Kittipibul V, Mahabir S, Ibrahim M, Saint Croix GR, Hernandez GA, et al. Effects of bromocriptine in peripartum cardiomyopathy: a systematic review and meta-analysis. *Heart Fail Rev* 2022;**27**:533–43. <https://doi.org/10.1007/s10741-021-10185-8>
546. Halliday BP, Wassall R, Lota AS, Khaliq Z, Gregson J, Newsome S, et al. Withdrawal of pharmacological treatment for heart failure in patients with recovered dilated cardiomyopathy (TRED-HF): an open-label, pilot, randomised trial. *Lancet* 2019;**393**: 61–73. [https://doi.org/10.1016/S0140-6736\(18\)32484-X](https://doi.org/10.1016/S0140-6736(18)32484-X)
547. Codsi E, Rose CH, Blauwet LA. Subsequent pregnancy outcomes in patients with peripartum cardiomyopathy. *Obstet Gynecol* 2018;**131**:322–7. <https://doi.org/10.1097/AOG.0000000000002439>
548. Meng M-L, Arendt KW, Banayan JM, Bradley EA, Vaught AJ, Hameed AB, et al. Anesthetic care of the pregnant patient with cardiovascular disease: a scientific statement from the American Heart Association. *Circulation* 2023;**147**:e657–73. <https://doi.org/10.1161/CIR.0000000000001121>
549. De Backer J, Haugaa K. 2025 ESC Guidelines for the management of cardiovascular disease and pregnancy. *Eur Heart J*. 2011;**32**:3147–97. <https://doi.org/10.1093/eurheartj/ehr218>
550. Richardson P, McKenna W, Bristow M, Maisch B, Mautner B, O'Connell J, et al. Report of the 1995 World Health Organization/International Society and Federation of Cardiology Task Force on the definition and classification of cardiomyopathies. *Circulation* 1996;**93**:841–2. <https://doi.org/10.1161/01.cir.93.5.841>
551. Frustaci A, Russo MA, Chimenti C. Randomized study on the efficacy of immunosuppressive therapy in patients with virus-negative inflammatory cardiomyopathy: the TIMIC study. *Eur Heart J* 2009;**30**:1995–2002. <https://doi.org/10.1093/eurheartj/ehp249>
552. Escher F, Kühl U, Lassner D, Poller W, Westermann D, Pieske B, et al. Long-term outcome of patients with virus-negative chronic myocarditis or inflammatory cardiomyopathy after immunosuppressive therapy. *Clin Res Cardiol* 2016;**105**:1011–20. <https://doi.org/10.1007/s00392-016-1011-z>
553. Merken J, Hazebroek M, Van Paassen P, Verdonschot J, Van Empel V, Knackstedt C, et al. Immunosuppressive therapy improves both short- and long-term prognosis in patients with virus-negative nonfulminant inflammatory cardiomyopathy. *Circ Heart Fail* 2018;**11**:e004228. <https://doi.org/10.1161/CIRCHEARTFAILURE.117.004228>
554. De Luca G, Campochiaro C, Sartorelli S, Peretto G, Sala S, Palmisano A, et al. Efficacy and safety of mycophenolate mofetil in patients with virus-negative lymphocytic myocarditis: a prospective cohort study. *J Autoimmun* 2020;**106**:102330. <https://doi.org/10.1016/j.jaut.2019.102330>
555. Peretto G, Sala S, De Luca G, Marcolongo R, Campochiaro C, Sartorelli S, et al. Immunosuppressive therapy and risk stratification of patients with myocarditis presenting with ventricular arrhythmias. *JACC Clin Electrophysiol* 2020;**6**:1221–34. <https://doi.org/10.1016/j.jacep.2020.05.013>
556. Reuter H, Burgess LJ, Doubell AF. Epidemiology of pericardial effusions at a large academic hospital in South Africa. *Epidemiol Infect* 2005;**133**:393–9. <https://doi.org/10.1017/s0950268804003577>
557. Mayosi BM, Wiysonge CS, Ntsekhe M, Gumede F, Volmink JA, Maartens G, et al. Mortality in patients treated for tuberculous pericarditis in sub-Saharan Africa. *S Afr Med J* 2008;**98**:36–40.
558. Mayosi BM, Burgess LJ, Doubell AF. Tuberculous pericarditis. *Circulation* 2005;**112**: 3608–16. <https://doi.org/10.1161/CIRCULATIONAHA.105.543066>
559. Isiguzo G, Du Bruyn E, Howlett P, Ntsekhe M. Diagnosis and management of tuberculous pericarditis: what is new? *Curr Cardiol Rep* 2020;**22**:2. <https://doi.org/10.1007/s11886-020-1254-1>
560. Ntsekhe M, Mayosi BM. Tuberculous pericarditis with and without HIV. *Heart Fail Rev* 2013;**18**:367–73. <https://doi.org/10.1007/s10741-012-9310-6>
561. Noubiap JJ, Agbor VN, Ndoadougou AL, Nkeke JR, Kamguia A, Nyaga UF, et al. Epidemiology of pericardial diseases in Africa: a systematic scoping review. *Heart* 2019;**105**:180–8. <https://doi.org/10.1136/heartjnl-2018-313922>
562. Xie DL, Cheng B, Sheng Y, Jin J. Diagnostic accuracy of adenosine deaminase for tuberculous pericarditis: a meta-analysis. *Eur Rev Med Pharmacol Sci* 2015;**19**:4411–8. https://doi.org/10.118632/eurrev_2015_19_22_4411
563. Pandie S, Peter JG, Kerbelker ZS, Meldau R, Theron G, Govender U, et al. Diagnostic accuracy of quantitative PCR (Xpert MTB/RIF) for tuberculous pericarditis compared to adenosine deaminase and unstimulated interferon- γ in a high burden setting: a prospective study. *BMC Med* 2014;**12**:101. <https://doi.org/10.1186/1741-7015-12-101>
564. Yu G, Ye B, Chen D, Zhong F, Chen G, Yang J, et al. Comparison between the diagnostic validities of Xpert MTB/RIF and interferon- γ release assays for tuberculous pericarditis using pericardial tissue. *PLoS One* 2017;**12**:e0188704. <https://doi.org/10.1371/journal.pone.0188704>
565. Liu C, Cui Y-L, Ding C-M, Wu Y-H, Li H-L, Liu X-F, et al. Diagnostic accuracy of interferon-gamma in pericardial effusions for tuberculous pericarditis: a meta-analysis. *J Thorac Dis* 2018;**10**:854–60. <https://doi.org/10.21037/jtd.2017.12.107>
566. Cattamanchi A, Smith R, Steingart KR, Metcalfe JZ, Date A, Coleman C, et al. Interferon-gamma release assays for the diagnosis of latent tuberculosis infection in HIV-infected individuals: a systematic review and meta-analysis. *J Acquir Immune Defic Syndr* 2011;**56**:230–38. <https://doi.org/10.1097/QAI.0b013e31820b07ab>
567. Wiysonge CS, Ntsekhe M, Thabane L, Volmink J, Majombezi D, Gumede F, et al. Interventions for treating tuberculous pericarditis. *Cochrane Database Syst Rev* 2017;**9**:CD000526. <https://doi.org/10.1002/14651858.CD000526.pub2>
568. Pasipanodya JG, Mubanga M, Ntsekhe M, Pandie S, Magazi BT, Gumede F, et al. Tuberculous pericarditis is multibacillary and bacterial burden drives high mortality. *EBioMedicine* 2015;**2**:1634–9. <https://doi.org/10.1016/j.ebiom.2015.09.034>
569. Mayosi BM, Ntsekhe M, Bosch J, Pandie S, Jung H, Gumede F, et al. Prednisolone and *Mycobacterium indicus pranii* in tuberculous pericarditis. *N Engl J Med* 2014;**371**: 1121–30. <https://doi.org/10.1056/NEJMoa1407380>
570. Reuter H, Burgess LJ, Louw VJ, Doubell AF. The management of tuberculous pericardial effusion: experience in 233 consecutive patients. *Cardiovasc J S Afr* 2007;**18**:20–5.
571. Strang JI, Kakaza HH, Gibson DG, Girling DJ, Nunn AJ, Fox W. Controlled trial of prednisolone as adjuvant in treatment of tuberculous constrictive pericarditis in Transkei. *Lancet* 1987;**2**:1418–22. [https://doi.org/10.1016/s0140-6736\(87\)91127-5](https://doi.org/10.1016/s0140-6736(87)91127-5)
572. Strang JIG, Nunn AJ, Johnson DA, Casbard A, Gibson DG, Girling DJ. Management of tuberculous constrictive pericarditis and tuberculous pericardial effusion in Transkei: results at 10 years follow-up. *QJM* 2004;**97**:525–35. <https://doi.org/10.1093/qjmed/hch086>
573. Cui H-B, Chen X-Y, Cui C-C, Shou X-L, Liu X, Yao X-W, et al. Prevention of pericardial constriction by transcatheter intrapericardial fibrinolysis with urokinase. *Chin Med Sci J* 2005;**20**:5–10. <https://doi.org/10.1016/j.chinmedsci.2005.01.002>
574. Maisch B, Ristic A, Pankuweit S. Evaluation and management of pericardial effusion in patients with neoplastic disease. *Prog Cardiovasc Dis* 2010;**53**:157–63. <https://doi.org/10.1016/j.pcad.2010.06.003>
575. Imazio M, Demichelis B, Parrini I, Favro E, Beqaraj F, Cecchi E, et al. Relation of acute pericardial disease to malignancy. *Am J Cardiol* 2005;**95**:1393–4. <https://doi.org/10.1016/j.amjcard.2005.01.094>
576. Pawlak Ciešlik A, Szturmowicz M, Fijałkowska A, Gałarek J, Gralec R, Błażińska-Przerwa K, et al. Diagnosis of malignant pericarditis: a single centre experience. *Kardiol Pol* 2012;**70**:1147–53. <https://doi.org/10.33963/v.kp.79064>
577. Karatolios K, Pankuweit S, Maisch B. Diagnostic value of biochemical biomarkers in malignant and non-malignant pericardial effusion. *Heart Fail Rev* 2013;**18**:337–44. <https://doi.org/10.1007/s10741-012-9327-x>
578. Wang K, Eblan MJ, Deal AM, Lipner M, Zagar TM, Wang Y, et al. Cardiac toxicity after radiotherapy for stage III non-small-cell lung cancer: pooled analysis of dose-escalation trials delivering 70 to 90 Gy. *J Clin Oncol* 2017;**35**:1387–94. <https://doi.org/10.1200/JCO.2016.70.0229>
579. Takata N, Kataoka M, Hamamoto Y, Tsuruoka S, Kanzaki H, Uwatsu K, et al. Risk factors for pericardial effusion after chemoradiotherapy for thoracic esophageal cancer-

- comparison of four-field technique and traditional two opposed fields technique. *J Radiat Res* 2018;**59**:291–7. <https://doi.org/10.1093/jrr/rry029>
580. Gevaert SA, Halvorsen S, Sinnaeve PR, Sambola A, Gulati G, Lancellotti P, et al. Evaluation and management of cancer patients presenting with acute cardiovascular disease: a Consensus Document of the Acute CardioVascular Care (ACVC) association and the ESC Council of Cardio-Oncology—Part 1: acute coronary syndromes and acute pericardial diseases. *Eur Heart J Acute Cardiovasc Care* 2021;**10**:947–59. <https://doi.org/10.1093/ehjacc/zuab056>
581. Saab J, Hoda RS, Narula N, Hoda SA, Geraghty BE, Nasar A, et al. Diagnostic yield of cytopathology in evaluating pericardial effusions: clinicopathologic analysis of 419 specimens. *Cancer Cytopathol* 2017;**125**:128–37. <https://doi.org/10.1002/cncy.21790>
582. Numico G, Cristofano A, Ocellini M, Sicuro M, Mozzicafreddo A, Fea E, et al. Prolonged drainage and intrapericardial bleomycin administration for cardiac tamponade secondary to cancer-related pericardial effusion. *Medicine (Baltimore)* 2016;**95**:e3273. <https://doi.org/10.1097/MD.0000000000003273>
583. Kim SR, Kim EK, Cho J, Chang S-A, Park S-J, Lee S-C, et al. Effect of anti-inflammatory drugs on clinical outcomes in patients with malignant pericardial effusion. *J Am Coll Cardiol* 2020;**76**:1551–61. <https://doi.org/10.1016/j.jacc.2020.08.003>
584. De Filippo O, Gatti P, Rettegno S, Iannaccone M, D'Ascenzo F, Lazaros G, et al. Is pericardial effusion a negative prognostic marker? Meta-analysis of outcomes of pericardial effusion. *J Cardiovasc Med (Hagerstown)* 2019;**20**:39–45. <https://doi.org/10.2459/JCM.0000000000000720>
585. Gatzoulis K, Archontakis S, Tsiachris D, Lazaros G, Apostolopoulos T, Zervopoulos G, et al. Post-cardiac injury syndrome after permanent electronic cardiac device implantation. Incidence, presentation, management and long-term prognosis. *Int J Cardiol* 2014;**174**:163–4. <https://doi.org/10.1016/j.ijcard.2014.03.170>
586. Nakhla S, Mentias A, Rymer C, Hussein A, Wazni O, Rickard J, et al. Acute pericarditis after atrial fibrillation ablation: incidence, characteristics, and risk factors. *Heart Rhythm* 2022;**3**:248–51. <https://doi.org/10.1016/j.hrroo.2022.02.008>
587. Imazio M, Negro A, Belli R, Beqaraj F, Forno D, Giammaria M, et al. Frequency and prognostic significance of pericarditis following acute myocardial infarction treated by primary percutaneous coronary intervention. *Am J Cardiol* 2009;**103**:1525–9. <https://doi.org/10.1016/j.amjcard.2009.01.366>
588. Figueras J, Juncal A, Carballo J, Cortadellas J, Soler JS. Nature and progression of pericardial effusion in patients with a first myocardial infarction: relationship to age and free wall rupture. *Am Heart J* 2002;**144**:251–8. <https://doi.org/10.1067/mhj.2002.123840>
589. Figueras J, Barrabés JA, Serra V, Cortadellas J, Lidón R-M, Carrizo A, et al. Hospital outcome of moderate to severe pericardial effusion complicating ST-elevation acute myocardial infarction. *Circulation* 2010;**122**:1902–9. <https://doi.org/10.1161/CIRCULATIONAHA.109.934968>
590. Mohanty S, Mohanty P, Kessler D, Gianni C, Baho KK, Morris T, et al. Impact of colchicine monotherapy on the risk of acute pericarditis following atrial fibrillation ablation. *JACC Clin Electrophysiol* 2023;**9**:1051–9. <https://doi.org/10.1016/j.jacep.2023.01.037>
591. Lehto J, Kiviniemi T, Gunn J, Airaksinen J, Rautava P, Kytö V. Occurrence of postpericardiotomy syndrome: association with operation type and postoperative mortality after open-heart operations. *J Am Heart Assoc* 2018;**7**:e010269. <https://doi.org/10.1161/JAHA.118.010269>
592. Imazio M, Brucato A, Rovere ME, Gandino A, Cemin R, Ferrua S, et al. Contemporary features, risk factors, and prognosis of the post-pericardiotomy syndrome. *Am J Cardiol* 2011;**108**:1183–7. <https://doi.org/10.1016/j.amjcard.2011.06.025>
593. Finkelstein Y, Shemesh J, Mahlab K, Abramov D, Bar-El Y, Sagie A, et al. Colchicine for the prevention of postpericardiotomy syndrome. *Herz* 2002;**27**:791–4. <https://doi.org/10.1007/s00059-002-2376-5>
594. Imazio M, Trinchero R, Brucato A, Rovere ME, Gandino A, Cemin R, et al. Colchicine for the Prevention of the Post-pericardiotomy Syndrome (COPPS): a multicentre, randomized, double-blind, placebo-controlled trial. *Eur Heart J* 2010;**31**:2749–54. <https://doi.org/10.1093/eurheartj/ehq319>
595. Imazio M, Brucato A, Ferrazzi P, Spodick DH, Adler Y. Postpericardiotomy syndrome: a proposal for diagnostic criteria. *J Cardiovasc Med (Hagerstown)* 2013;**14**:351–3. <https://doi.org/10.2459/JCM.0b013e328353807d>
596. Imazio M, Brucato A, Ferrazzi P, Pullara A, Adler Y, Barosi A, et al. Colchicine for prevention of postpericardiotomy syndrome and postoperative atrial fibrillation: the COPPS-2 randomized clinical trial. *JAMA* 2014;**312**:1016–23. <https://doi.org/10.1001/jama.2014.11026>
597. Gill PJ, Forbes K, Coe JY. The effect of short-term prophylactic acetylsalicylic acid on the incidence of postpericardiotomy syndrome after surgical closure of atrial septal defects. *Pediatr Cardiol* 2009;**30**:1061–7. <https://doi.org/10.1007/s00246-009-9495-1>
598. Mott AR, Fraser CD, Kusnoor AV, Giesecke NM, Reul GJ, Drescher KL, et al. The effect of short-term prophylactic methylprednisolone on the incidence and severity of postpericardiotomy syndrome in children undergoing cardiac surgery with cardiopulmonary bypass. *J Am Coll Cardiol* 2001;**37**:1700–6. [https://doi.org/10.1016/s0735-1097\(01\)01223-2](https://doi.org/10.1016/s0735-1097(01)01223-2)
599. Bunge JH, van Osch D, Dieleman JM, Jacob KA, Kluijn J, van Dijk D, et al. Dexamethasone for the prevention of postpericardiotomy syndrome: a DEXamethasone for Cardiac Surgery substudy. *Am Heart J* 2014;**168**:126–31.e1. <https://doi.org/10.1016/j.ahj.2014.03.017>
600. Imazio M, Brucato A, Markel G, Cemin R, Trinchero R, Spodick DH, et al. Meta-analysis of randomized trials focusing on prevention of the postpericardiotomy syndrome. *Am J Cardiol* 2011;**108**:575–9. <https://doi.org/10.1016/j.amjcard.2011.03.087>
601. Meurin P, Tabet JY, Thabut G, Cristofini P, Farrokhi T, Fischbach M, et al. Nonsteroidal anti-inflammatory drug treatment for postoperative pericardial effusion: a multicenter randomized, double-blind trial. *Ann Intern Med* 2010;**152**:137–43. <https://doi.org/10.7326/0003-4819-152-3-201002020-00004>
602. Meurin P, Lelay-Kubas S, Pierre B, Pereira H, Pavy B, Iliou MC, et al. Colchicine for postoperative pericardial effusion: a multicenter, double-blind, randomised controlled trial. *Heart* 2015;**101**:1711–6. <https://doi.org/10.1136/heartjnl-2015-307827>
603. Meurin P, Weber H, Renaud N, Larrazet F, Tabet JY, Demolis P, et al. Evolution of the postoperative pericardial effusion after day 15: the problem of the late tamponade. *Chest* 2004;**125**:2182–7. <https://doi.org/10.1378/chest.125.6.2182>
604. Andreis A, Imazio M, Giustetto C, Brucato A, Adler Y, De Ferrari GM. Anakinra for constrictive pericarditis associated with incessant or recurrent pericarditis. *Heart* 2020;**106**:1561–5. <https://doi.org/10.1136/heartjnl-2020-316898>
605. Gattorno M, Hofer M, Federici S, Vanoni F, Bovis F, Aksentjevich I, et al. Classification criteria for autoinflammatory recurrent fevers. *Ann Rheum Dis* 2019;**78**:1025–32. <https://doi.org/10.1136/annrheumdis-2019-215048>
606. Sagristà-Sauleda J, Barrabés JA, Permanyer-Miralda G, Soler-Soler J. Purulent pericarditis: review of a 20-year experience in a general hospital. *J Am Coll Cardiol* 1993;**22**:1661–5. [https://doi.org/10.1016/0735-1097\(93\)90592-o](https://doi.org/10.1016/0735-1097(93)90592-o)
607. Rubin RH, Moellering RC. Clinical, microbiologic and therapeutic aspects of purulent pericarditis. *Am J Med* 1975;**59**:68–78. [https://doi.org/10.1016/0002-9343\(75\)90323-x](https://doi.org/10.1016/0002-9343(75)90323-x)
608. Brook I, Frazier EH. Microbiology of acute purulent pericarditis. A 12-year experience in a military hospital. *Arch Intern Med* 1996;**156**:1857–60. <https://doi.org/10.1001/archinte.1996.00440150113013>
609. Wiyeh AB, Ochodo EA, Wiysonge CS, Kakia A, Awotodu AA, Ristic A, et al. A systematic review of the efficacy and safety of intrapericardial fibrinolysis in patients with pericardial effusion. *Int J Cardiol* 2018;**250**:223–8. <https://doi.org/10.1016/j.ijcard.2017.10.049>
610. Augustin P, Desmard M, Mordant P, Lasocki S, Maury J-M, Heming N, et al. Clinical review: intrapericardial fibrinolysis in management of purulent pericarditis. *Crit Care* 2011;**15**:220. <https://doi.org/10.1186/cc10022>
611. Imazio M, Brucato A, Cemin R, Ferrua S, Belli R, Maestroni S, et al. Colchicine for recurrent pericarditis (CORP): a randomized trial. *Ann Intern Med* 2011;**155**:409–14. <https://doi.org/10.7326/0003-4819-155-7-201110040-00359>
612. Vogiatzidis K, Zarogiannis SG, Aidonidis I, Solenov EI, Molyvdas P-A, Gourgoulianis KI, et al. Physiology of pericardial fluid production and drainage. *Front Physiol* 2015;**6**:62. <https://doi.org/10.3389/fphys.2015.00062>
613. Mitiku TY, Heidenreich PA. A small pericardial effusion is a marker of increased mortality. *Am Heart J* 2011;**161**:152–7. <https://doi.org/10.1016/j.ahj.2010.10.007>
614. Corey GR, Campbell PT, Van Trigt P, Kenney RT, O'Connor CM, Sheikh KH, et al. Etiology of large pericardial effusions. *Am J Med* 1993;**95**:209–13. [https://doi.org/10.1016/0002-9343\(93\)90262-n](https://doi.org/10.1016/0002-9343(93)90262-n)
615. Sagristà-Sauleda J, Mercé J, Permanyer-Miralda G, Soler-Soler J. Clinical clues to the causes of large pericardial effusions. *Am J Med* 2000;**109**:95–101. [https://doi.org/10.1016/s0002-9343\(00\)00459-9](https://doi.org/10.1016/s0002-9343(00)00459-9)
616. Levy P-Y, Corey R, Berger P, Habib G, Bonnet J-L, Levy S, et al. Etiologic diagnosis of 204 pericardial effusions. *Medicine (Baltimore)* 2003;**82**:385–91. <https://doi.org/10.1097/01.md.0000101574.54295.73>
617. Ma W, Liu J, Zeng Y, Chen S, Zheng Y, Ye S, et al. Causes of moderate to large pericardial effusion requiring pericardiocentesis in 140 Han Chinese patients. *Herz* 2012;**37**:183–7. <https://doi.org/10.1007/s00059-011-3428-5>
618. Abdallah R, Atar S. Etiology and characteristics of large symptomatic pericardial effusion in a community hospital in the contemporary era. *QJM* 2014;**107**:363–8. <https://doi.org/10.1093/qjmed/hct255>
619. Roy CL, Minor MA, Brookhart MA, Choudhry NK. Does this patient with a pericardial effusion have cardiac tamponade? *JAMA* 2007;**297**:1810–8. <https://doi.org/10.1001/jama.297.16.1810>
620. Cremer PC, Kumar A, Kontzias A, Tan CD, Rodriguez ER, Imazio M, et al. Complicated pericarditis: understanding risk factors and pathophysiology to inform imaging and treatment. *J Am Coll Cardiol* 2016;**68**:2311–28. <https://doi.org/10.1016/j.jacc.2016.07.785>
621. Lazaros G, Antonopoulos AS, Lazarou E, Vlachopoulos C, Foukarakis E, Androulakis A, et al. Long-term outcome of pericardial drainage in cases of chronic, large, hemodynamically insignificant, C-reactive protein negative, idiopathic pericardial effusions. *Am J Cardiol* 2020;**126**:89–93. <https://doi.org/10.1016/j.amjcard.2020.03.035>
622. Lazaros G, Oikonomou V, Oikonomou E, Aznaouridis K, Vlachopoulos C, Vogiatzi G, et al. Recurrence of pericardial effusion after pericardiocentesis: does catheter-induced acute pericardial inflammation play a role? *Am J Med Sci* 2021;**361**:676–8. <https://doi.org/10.1016/j.amjms.2020.10.012>

623. Buoro S, Tombetti E, Ceriotti F, Simon C, Cugola D, Seghezzi M, et al. What is the normal composition of pericardial fluid? *Heart* 2021;**107**:1584–90. <https://doi.org/10.1136/heartjnl-2020-317966>
624. Imazio M, Biondo A, Ricci D, Boffini M, Pivetta E, Brucato A, et al. Contemporary biochemical analysis of normal pericardial fluid. *Heart* 2020;**106**:541–4. <https://doi.org/10.1136/heartjnl-2018-314574>
625. Imazio M, Lazaros G, Valenti A, De Carlini CC, Maggolini S, Pivetta E, et al. Outcomes of idiopathic chronic large pericardial effusion. *Heart* 2019;**105**:477–81. <https://doi.org/10.1136/heartjnl-2018-313532>
626. Fröhlich GM, Keller P, Schmid F, Wolfrum M, Osranek M, Falk C, et al. Haemodynamically irrelevant pericardial effusion is associated with increased mortality in patients with chronic heart failure. *Eur Heart J* 2013;**34**:1414–23. <https://doi.org/10.1093/eurheartj/ehs006>
627. Porta-Sánchez A, Sagristà-Sauleda J, Ferreira-González I, Torrents-Fernández A, Roca-Luque I, García-Dorado D. Constrictive pericarditis: etiologic spectrum, patterns of clinical presentation, prognostic factors, and long-term follow-up. *Rev Esp Cardiol (Engl Ed)* 2015;**68**:1092–100. <https://doi.org/10.1016/j.rec.2014.12.018>
628. Ling LH, Oh JK, Schaff HV, Danielson GK, Mahoney DW, Seward JB, et al. Constrictive pericarditis in the modern era: evolving clinical spectrum and impact on outcome after pericardiectomy. *Circulation* 1999;**100**:1380–6. <https://doi.org/10.1161/01.cir.100.13.1380>
629. Bertog SC, Thambidorai SK, Parakh K, Schoenhagen P, Ozduran V, Houghtaling PL, et al. Constrictive pericarditis: etiology and cause-specific survival after pericardiectomy. *J Am Coll Cardiol* 2004;**43**:1445–52. <https://doi.org/10.1016/j.jacc.2003.11.048>
630. Mutyaba AK, Balkaran S, Cloete R, du Plessis N, Badri M, Brink J, et al. Constrictive pericarditis requiring pericardiectomy at Groote Schuur Hospital, Cape Town, South Africa: causes and perioperative outcomes in the HIV era (1990–2012). *J Thorac Cardiovasc Surg* 2014;**148**:3058–65.e1. <https://doi.org/10.1016/j.jtcvs.2014.07.065>
631. Yang J, Xiang W, He R, Zhang P. Tuberculous constrictive pericarditis: 'armored heart'. *QJM* 2024;**117**:679–80. <https://doi.org/10.1093/qjmed/hcae101>
632. Welch TD, Ling LH, Espinosa RE, Anavekar NS, Wiste HJ, Lahr BD, et al. Echocardiographic diagnosis of constrictive pericarditis: Mayo Clinic criteria. *Circ Cardiovasc Imaging* 2014;**7**:526–34. <https://doi.org/10.1161/CIRCIMAGING.113.001613>
633. Talreja DR, Nishimura RA, Oh JK, Holmes DR. Constrictive pericarditis in the modern era: novel criteria for diagnosis in the cardiac catheterization laboratory. *J Am Coll Cardiol* 2008;**51**:315–9. <https://doi.org/10.1016/j.jacc.2007.09.039>
634. Qamruddin S, Alkharabsheh SK, Sato K, Kumar A, Cremer PC, Chetrit M, et al. Differentiating constriction from restriction (from the Mayo Clinic echocardiographic criteria). *Am J Cardiol* 2019;**124**:932–8. <https://doi.org/10.1016/j.amjcard.2019.06.002>
635. Saito T, Fukushima S, Yamasaki T, Kawamoto N, Tadokoro N, Kakuta T, et al. Pericardiectomy for constrictive pericarditis at a single Japanese center: 20 years of experience. *Gen Thorac Cardiovasc Surg* 2022;**70**:430–8. <https://doi.org/10.1007/s11748-021-01718-x>
636. Choi MS, Jeong DS, Oh JK, Chang S-A, Park S-J, Chung S. Long-term results of radical pericardiectomy for constrictive pericarditis in Korean population. *J Cardiothorac Surg* 2019;**14**:32. <https://doi.org/10.1186/s13019-019-0845-7>
637. George TJ, Arnaoutakis GJ, Beatty CA, Kilic A, Baumgartner WA, Conte JV. Contemporary etiologies, risk factors, and outcomes after pericardiectomy. *Ann Thorac Surg* 2012;**94**:445–51. <https://doi.org/10.1016/j.athoracsur.2012.03.079>
638. Tzani A, Doulamis IP, Tzoumas A, Avgerinos DV, Koudoumas D, Siasos G, et al. Meta-analysis of population characteristics and outcomes of patients undergoing pericardiectomy for constrictive pericarditis. *Am J Cardiol* 2021;**146**:120–7. <https://doi.org/10.1016/j.amjcard.2021.01.033>
639. Faiza Z, Prakash A, Namburi N, Johnson B, Timsina L, Lee LS. Fifteen-year experience with pericardiectomy at a tertiary referral center. *J Cardiothorac Surg* 2021;**16**:180. <https://doi.org/10.1186/s13019-021-01551-4>
640. Gillaspie EA, Stulak JM, Daly RC, Greason KL, Joyce LD, Oh J, et al. A 20-year experience with isolated pericardiectomy: analysis of indications and outcomes. *J Thorac Cardiovasc Surg* 2016;**152**:448–58. <https://doi.org/10.1016/j.jtcvs.2016.03.098>
641. Ntsckhe M, Shey Wiysonge C, Commerford PJ, Mayosi BM. The prevalence and outcome of effusive constrictive pericarditis: a systematic review of the literature. *Cardiovasc J Afr* 2012;**23**:281–5. <https://doi.org/10.5830/CVJA-2011-072>
642. Thevathasan T, Kenny MA, Gaul AL, Paul J, Krause FJ, Lech S, et al. Sex and age characteristics in acute or chronic myocarditis: a descriptive, multicenter cohort study. *JACC Adv* 2024;**3**:100857. <https://doi.org/10.1016/j.jaccadv.2024.100857>
643. Kanaoka K, Onoue K, Terasaki S, Nakano T, Nakai M, Sumita Y, et al. Features and outcomes of histologically proven myocarditis with fulminant presentation. *Circulation* 2022;**146**:1425–33. <https://doi.org/10.1161/CIRCULATIONAHA.121.058869>
644. Conte E, Leoni O, Ammirati E, Imazio M, Brucato A. Incidence of myocarditis and pericarditis considered as separate clinical events over the years and post-SARS-CoV2 vaccination in adults and children. *Eur J Intern Med* 2023;**115**:140–2. <https://doi.org/10.1016/j.ejim.2023.06.002>
645. Klugman D, Berger JT, Sable CA, He J, Khandelwal SG, Slonim AD. Pediatric patients hospitalized with myocarditis: a multi-institutional analysis. *Pediatr Cardiol* 2010;**31**:222–8. <https://doi.org/10.1007/s00246-009-9589-9>
646. Pitak B, Opgen-Rhein B, Schubert S, Reineker K, Wiegand G, Boecker D, et al. Cardiovascular magnetic resonance in children with suspected myocarditis: current practice and applicability of adult protocols. *Cardiol Young* 2022;**32**:1957–65. <https://doi.org/10.1017/S1047951121005291>
647. Peng DM, Kwiatkowski DM, Lasa JJ, Zhang W, Banerjee M, Mikesell K, et al. Contemporary care and outcomes of critically-ill children with clinically diagnosed myocarditis. *J Card Fail* 2023;**30**:350–8. <https://doi.org/10.1016/j.cardfail.2023.04.010>
648. Schubert S, Opgen-Rhein B, Boehne M, Weigelt A, Wagner R, Müller G, et al. Severe heart failure and the need for mechanical circulatory support and heart transplantation in pediatric patients with myocarditis: results from the prospective multicenter registry 'MYKKE'. *Pediatr Transplant* 2019;**23**:e13548. <https://doi.org/10.1111/ptr.13548>
649. Matsuura H, Ichida F, Saji T, Ogawa S, Waki K, Kaneko M, et al. Clinical features of acute and fulminant myocarditis in children – 2nd Nationwide Survey by Japanese Society of Pediatric Cardiology and Cardiac Surgery. *Circ J* 2016;**80**:2362–8. <https://doi.org/10.1253/circj.CJ-16-0234>
650. Yao Q, Zhan S. Corticosteroid in anti-inflammatory treatment of pediatric acute myocarditis: a systematic review and meta-analysis. *Ital J Pediatr* 2023;**49**:30. <https://doi.org/10.1186/s13052-023-01423-w>
651. Camargo PR, Snitcowsky R, da Luz PL, Mazzieri R, Higuchi ML, Rati M, et al. Favorable effects of immunosuppressive therapy in children with dilated cardiomyopathy and active myocarditis. *Pediatr Cardiol* 1995;**16**:61–8. <https://doi.org/10.1007/BF00796819>
652. Aziz KU, Patel N, Sadullah T, Tasneem H, Thawarani H, Talpur S. Acute viral myocarditis: role of immunosuppression: a prospective randomised study. *Cardiol Young* 2010;**20**:509–15. <https://doi.org/10.1017/S1047951110000594>
653. Lin M-S, Tseng Y-H, Chen M-Y, Chung C-M, Tsai M-H, Wang P-C, et al. In-hospital and post-discharge outcomes of pediatric acute myocarditis underwent after high-dose steroid or intravenous immunoglobulin therapy. *BMC Cardiovasc Disord* 2019;**19**:10. <https://doi.org/10.1186/s12872-018-0981-3>
654. Butts RJ, Boyle GJ, Deshpande SR, Gambetta K, Knecht KR, Prada-Ruiz CA, et al. Characteristics of clinically diagnosed pediatric myocarditis in a contemporary multicenter cohort. *Pediatr Cardiol* 2017;**38**:1175–82. <https://doi.org/10.1007/s00246-017-1638-1>
655. Huang X, Sun Y, Su G, Li Y, Shuai X. Intravenous immunoglobulin therapy for acute myocarditis in children and adults. *Int Heart J* 2019;**60**:359–65. <https://doi.org/10.1536/ihj.18-299>
656. Imazio M, Brucato A, Pluymaekers N, Breda L, Calabri G, Cantarini L, et al. Recurrent pericarditis in children and adolescents: a multicentre cohort study. *J Cardiovasc Med (Hagerstown)* 2016;**17**:707–12. <https://doi.org/10.2459/JCM.0000000000000300>
657. Alsabri M, Elsayed SM, Elshory AB, Abouelmagd K, Ayyad M, Alqeeq BF, et al. Efficacy and safety of colchicine in pediatric pericarditis: a systematic review and future directions. *Pediatr Cardiol* 2024; <https://doi.org/10.1007/s00246-024-03606-6>
658. Caorsi R, Insalaco A, Bovis F, Martini G, Cattalini M, Chinali M, et al. Pediatric recurrent pericarditis: appropriateness of the standard of care and response to IL-1 blockade. *J Pediatr* 2023;**256**:18–26.e8. <https://doi.org/10.1016/j.jpeds.2022.11.034>
659. Sunohara D, Motoki H, Saigusa T, Ebisawa S, Okada A, Ando H, et al. Biopsy detection and clinical management of acute lymphocytic myocarditis in pregnancy. *J Cardiol Cases* 2019;**10**:164–7. <https://doi.org/10.1016/j.jccase.2019.07.010>
660. Veronese G, Nonini S, Cannata A, Aresta F, Olivieri G, Montrasio E, et al. Fulminant lymphocytic myocarditis during pregnancy treated with temporary mechanical circulatory supports and aggressive immunosuppression. *Circ Heart Fail* 2022;**15**:e009810. <https://doi.org/10.1161/CIRCHEARTFAILURE.122.009810>
661. Moore RC, Briery CM, Rose CH, Skelton TN, Martin JN. Lymphocytic myocarditis presenting as nausea, vomiting, and hepatic dysfunction in the first trimester of pregnancy. *Obstet Gynecol* 2006;**108**:815–7. <https://doi.org/10.1097/01.AOG.0000216016.91685.52>
662. Marceau A, McGinnis JM, Derakhshan F, Liu YA, Sathananthan G, Sosa Cazaes AC, et al. Interdisciplinary approach to an unusual case of myocarditis in pregnancy. *CJC Open* 2019;**1**:103–5. <https://doi.org/10.1016/j.cjco.2019.02.001>
663. Movva R, Brown SB, Morris DL, Figueredo VM. Anakinra for myocarditis in juvenile idiopathic arthritis. *Tex Heart Inst J* 2013;**40**:623–5.
664. Brucato A, Pluymaekers N, Tombetti E, Rampello S, Maestroni S, Lucianetti M, et al. Management of idiopathic recurrent pericarditis during pregnancy. *Int J Cardiol* 2019;**282**:60–5. <https://doi.org/10.1016/j.ijcard.2019.02.003>
665. Pouta AM, Räsänen JP, Airaksinen KE, Vuolteenaho OJ, Laatikainen TJ. Changes in maternal heart dimensions and plasma atrial natriuretic peptide levels in the early puerperium of normal and pre-eclamptic pregnancies. *Br J Obstet Gynaecol* 1996;**103**:988–92. <https://doi.org/10.1111/j.1471-0528.1996.tb09548.x>
666. Regitz-Zagrosek V, Roos-Hesselink JW, Bauersachs J, Blomström-Lundqvist C, Cifková R, De Bonis M, et al. 2018 ESC Guidelines for the management of cardiovascular diseases during pregnancy. *Eur Heart J* 2018;**39**:3165–241. <https://doi.org/10.1093/eurheartj/ehy340>
667. Schreiber K, Frishman M, Russell MD, Dey M, Flint J, Allen A, et al. British Society for Rheumatology guideline on prescribing drugs in pregnancy and breastfeeding: comorbidity medications used in rheumatology practice. *Rheumatology* 2023;**62**:e89–e104. <https://doi.org/10.1093/rheumatology/keac552>
668. Sammaritano LR, Bermas BL, Chakravarty EE, Chambers C, Clowse MEB, Lockshin MD, et al. 2020 American College of Rheumatology Guideline for the management

- of reproductive health in rheumatic and musculoskeletal diseases. *Arthritis Rheumatol* 2020;**72**:529–56. <https://doi.org/10.1002/art.41191>
669. Götestam Skorpén C, Hoeltzenbein M, Tincani A, Fischer-Betz R, Elefant E, Chambers C, et al. The EULAR points to consider for use of antirheumatic drugs before pregnancy, and during pregnancy and lactation. *Ann Rheum Dis* 2016;**75**:795–810. <https://doi.org/10.1136/annrheumdis-2015-208840>
670. Russell MD, Dey M, Flint J, Davie P, Allen A, Crossley A, et al. British Society for Rheumatology guideline on prescribing drugs in pregnancy and breastfeeding: immunomodulatory anti-rheumatic drugs and corticosteroids. *Rheumatology* 2023;**62**:e48–e88. <https://doi.org/10.1093/rheumatology/keac551>
671. Bizzi E, Cavaleri F, Mascolo R, Conte E, Maggiolini S, Decarli CC, et al. Recurrent pericarditis in older adults: clinical and laboratory features and outcome. *J Am Geriatr Soc* 2024;**72**:3467–75. <https://doi.org/10.1111/jgs.19150>
672. Pasina L, Brucato AL, Falcone C, Cucchi E, Bresciani A, Sottocorno M, et al. Medication non-adherence among elderly patients newly discharged and receiving polypharmacy. *Drugs Aging* 2014;**31**:283–9. <https://doi.org/10.1007/s40266-014-0163-7>
673. Peretto G, De Luca G, Campochiaro C, Palmisano A, Busnardo E, Sartorelli S, et al. Telemedicine in myocarditis: evolution of a multidisciplinary 'disease unit' at the time of COVID-19 pandemic. *Am Heart J* 2020;**229**:121–6. <https://doi.org/10.1016/j.ahj.2020.07.015>
674. Aldajani A, Bérubé M, Mardigyan V. How and why to set up a pericardial disease clinic. *Can J Cardiol* 2023;**39**:1149–51. <https://doi.org/10.1016/j.cjca.2023.04.028>
675. Mizia-Stec K, Charron P, Gimeno Blanes JR, Elliott P, Kaski JP, Maggioni AP, et al. Current use of cardiac magnetic resonance in tertiary referral centres for the diagnosis of cardiomyopathy: the ESC EORP cardiomyopathy/myocarditis registry. *Eur Heart J Cardiovasc Imaging* 2021;**22**:781–9. <https://doi.org/10.1093/ehjci/jeaa329>
676. Kaski JP, Norrish G, Gimeno Blanes JR, Charron P, Elliott P, Tavazzi L, et al. Cardiomyopathies in children and adolescents: aetiology, management, and outcomes in the European Society of Cardiology EURObservational Research Programme Cardiomyopathy and Myocarditis Registry. *Eur Heart J* 2024;**45**:1443–54. <https://doi.org/10.1093/eurheartj/ehae109>